

—Original—

Randomized Trial Comparing In-Situ Radiofrequency Ablation and Milligan-Morgan Hemorrhoidectomy in Prolapsing Hemorrhoids

Pravin J. Gupta, M.S (Gen. Surgery)

Consulting Proctologist, Fine Morning Hospital and Research Center, Gupta Nursing Home

Abstract

The Milligan-Morgan (MM) operation is the most widely practiced procedure for prolapsed hemorrhoids. But it is also associated with a fair amount of postoperative pain, a long period of convalescence, and complications like bleeding and anal stenosis. The aim of this study was to evaluate the efficacy of in-situ radiofrequency ablation (RA) of hemorrhoids.

During a 6-month period, 40 patients with grade 3 hemorrhoids were prospectively randomized for RA (21 patients) or MM hemorrhoidectomy (19 patients). Patients were evaluated for operative time, postoperative pain, time to return to work and occurrence of early and late complications.

Duration of surgery was significantly higher in the MM group ($p < 0.0001$). Postoperative hospitalization was longer in the MM group ($p < 0.001$). The post defecation pain and pain at rest were much less in the RA group ($p < 0.001$). Wound healing period (16.3 vs. 37.5 days) and time to return to work (7.3 vs. 18.3 days) were other significant findings. Early complications occurred more frequently in the MM group, but late complications like external skin tags [4 patients vs. 2 patients] and one asymptomatic recurrence was noted in the RA group.

In-situ RA of prolapsing hemorrhoids is a quick and bloodless procedure. It is associated with significantly less postoperative pain, shorter hospital stay and early return to normal activity. It can be considered as an alternative to conventional hemorrhoidectomy.

(J Nippon Med Sch 2003; 70: 393–400)

Key words: prolapsing hemorrhoids, hemorrhoidectomy, milligan-morgan, radiofrequency ablation

Introduction

Surgery is considered to be the best therapeutic treatment for advanced hemorrhoidal disease. Precisely, hemorrhoidectomy is the best answer to these types of hemorrhoids. The Milligan-Morgan (MM) Operation¹ is still the most commonly

performed procedure for prolapsing hemorrhoids. But this conventional hemorrhoidectomy is often associated with a long and painful postoperative course², a prolonged convalescence period and a high incidence of relapse. The other procedures in practice are diathermy, laser hemorrhoidectomy and stapled hemorrhoidopexy.

This study presents a new alternative to the

Correspondence to Pravin J. Gupta, M.S (Gen. Surgery) Consulting Proctologist, Fine Morning Hospital and Research Center, Gupta Nursing Home, D/9, Laxminagar, NAGPUR-440022, INDIA

E-mail: drjpg@yahoo.co.in

Journal Website (<http://www.nms.ac.jp/jnms/>)

surgical procedure by an in-situ radiofrequency ablation (RA) of the hemorrhoids. In principle, RA acts by converting radiofrequency waves into heat. The alternating current passing down from an uninsulated electrode tip into the surrounding tissues generates changes in the direction of ions and creates ionic agitation and frictional heating. The tissue heating then drives extracellular and intracellular water out of the tissue, which results in the final destruction of the tissue as a result of coagulative necrosis³. This phenomenon is called as cellular volatilization⁴.

The aim of this study was to assess postoperative pain, time to return to work, and early and late complication rates following traditional MM procedure and in-situ RA of hemorrhoids.

Patients and Methods

During a 6-month period from February 2001 to September 2001, 40 patients with grade three hemorrhoids were prospectively and randomly assigned to MM hemorrhoidectomy or RA. Randomization was done by sealed envelop upon the patient's arrival in the operation theatre. The duty nurse in the operating theatre drew the envelopes. Patients taking anticoagulants, those previously operated on or having thrombosed hemorrhoids were excluded from the study.

All the patients were subjected to detailed clinical examination including the noting down of history, local and general examination, per rectal and anoscopic examination. Four patients (10%) having colonic symptoms like frequency of stool, passage of mucus per rectum or abdominal pain were subjected to sigmoidoscopy to exclude more proximal diseases.

No specific pre-operative preparation was advised, except keeping the patient on fast from the night before the procedure. A dose of laxative (two tablets of senna or bisacodyl) was administered on the night prior to the procedure. The procedure was approved by the local ethical committee and was performed according to the declaration of Helsinki.

All the patients were operated on under either general anesthesia or caudal block as per the preference of the anesthetist after evaluation of the patient. An intravenous dose of 1 gm of Ceftriaxone Sodium was given just before the commencement of the procedure.

In the postoperative course, all the patients were given a standard regimen of 30 ml Lactulose in two divided doses for 4 weeks. Pain was controlled by using 50 mg tablets of Diclofenac sodium with an overall dose of 100 mg on demand, but never more than three times per day, and a local application of Lidocain ointment 5% three times a day. One tablet of Ornidazole 500 mg two times a day was given as an antibiotic for ten days. All the data concerning duration of surgery, postoperative pain, first bowel movement, hospital stay, discharge, wound healing time, return to work and complications [both early and late] were recorded.

Pain was assessed using a visual analogue scale from 0 (no pain at all) to 10 (the worst pain the patient had ever experienced).

Patients were discharged from the hospital only after one bowel movement had been achieved. Outpatient follow up was carried out at 1 week, 2 weeks and 4 weeks after the procedure to assess the duration of post operative pain, time to return to work, wound healing time and early complications like bleeding, urinary retention, seepage and

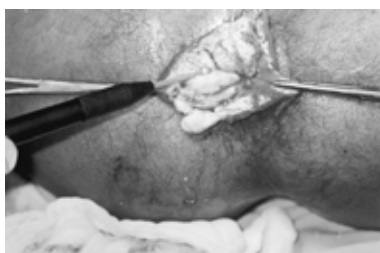

Fig. 1A Radiofrequency coagulation a ball electrode.

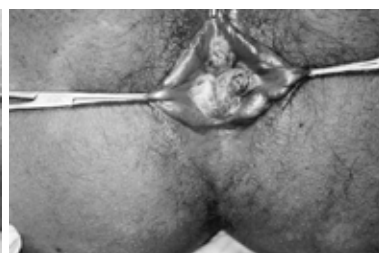

Fig. 2A In-situ radiofrequency ablation of grade III hemorrhoids.

continence disorder. They were subsequently called after 12 months to note late complications like anal stenosis, recurrence of hemorrhoids and development of external skin tags. An independent observer carried out the observations, unaware of what kind of procedure had been performed.

The Radio surgical Unit

We used the patented Ellman Dual Frequency 4 MHz radiofrequency generator from Ellman International-Hewlett, New York. The unit is provided with a handle to which different electrodes could be attached to meet the exact requirements of the procedure⁵. The amount of energy to be delivered can be preset to range between 1 and 100. A ball electrode of a sufficient length was extensively used in our procedure.

In-situ RA of hemorrhoids

The procedure was performed with the patient in the lithotomy position. This position is favored by most surgeons⁶. Anal stretching [Lord's anal dilatation] was done up to four fingers in each patient. This resulted in relieving sphincter spasms and helped in minimizing postoperative pain. It was observed that after relief of spasms, the piles, which earlier looked very large and prolapsing, became reduced in size and less external⁷.

An anoscope was gently inserted into the anal canal to visualize the hemorrhoids. Starting at the base of the pedicle, the whole pile mass was coagulated by gradually rotating the ball electrode of the radiofrequency probe over the hemorrhoid. The power of the radio surgical unit was adjusted so as to produce shrinkage and a gradual change of hemorrhoids to a dusky white color (blanching) indicating a satisfactory coagulation necrosis. Whenever the presence of associated secondary⁸ piles was noticed, those too were simultaneously ablated.

All the hemorrhoids were coagulated at one sitting with the precaution of leaving normal anal mucosa in between the treated hemorrhoids. There was no special preference for the positions of hemorrhoids to begin with, although we went on dealing with the largest pile first and so on. Care

Table 1 Patient Demographics

	RA group	MM Group
No. of Patients	21	19
Mean age (S.D)	42 yrs (9.2)	37 yrs (8.8)
Mean duration of disease (S.D)	67 months (12.2)	58 months (11.4)

was taken to avoid charring of rectal mucosa or hemorrhoids. This precaution helped in avoiding undue fibrosis and anal narrowing, a complication often noticed after such procedures⁹. At the conclusion of the procedure, a generous amount of xylocain ointment was applied over the operated area. No anal pack was kept, as it is known to increase the postoperative pain and discomfort¹⁰. A bisacodyl suppository was kept inside. The suppository helped in initiating early bowel activity. The anal opening was covered with a sterile pad or a sanitary napkin to absorb the little ooze that sometimes occurs postoperatively.

The actual operative procedure was completed in 6~8 minutes. A mean of 74 seconds of radiofrequency ablation was needed for each hemorrhoid.

MM Hemorrhoidectomy

The procedure was performed in the lithotomy position in a way similar to the standard technique described¹. A bisacodyl suppository was kept after the procedure.

Statistical analysis

The data was analyzed using Students' unpaired t test for independent groups and continuous variables. A P value of <0.05 was considered statistically significant.

Results

From the 40 patients with symptomatic grade 3 hemorrhoids, 21 were randomized to RA procedure and 19 were assigned to MM hemorrhoidectomy. There was no significant difference in the age and mean duration of disease. [Table 1].

Table 2 Perioperative and postoperative findings [values are mean (SD)]

	MM group	RA group	P
Operative time	29.6 (5.4)	7.2 (1.4)	< 0.0001
Time to first defecation in days	2.3 (0.6)	1.4 (0.2)	< 0.001
Hospital stay in days	2.6 (0.6)	1.5 (0.3)	< 0.001
Anal discharge in days	11 (2.3)	17 (2.4)	< 0.0001
Time to return to work in days	18.3 (4.3)	7.3 (1.1)	< 0.0001
Wound healing time in days	37.5 (7.1)	16.3 (2.6)	< 0.0001

POST DEFECTION PAIN [VISUAL ANALOGUE SCALE]

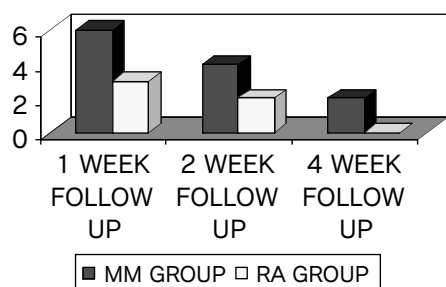


Fig. 1 Post defecation pain on visual analogue scale.

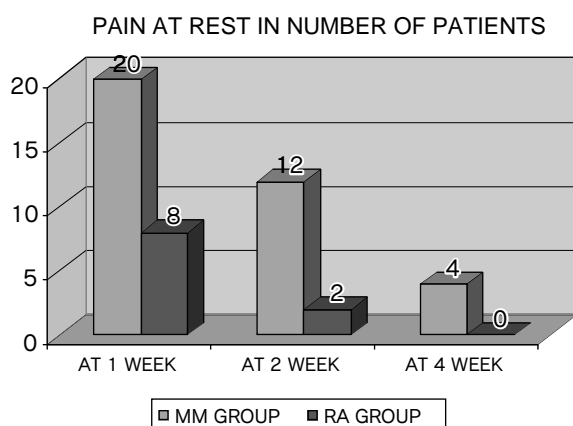


Fig. 2 Pain at rest in number of patients.

Pre operative and postoperative findings

Duration of procedure [Table 2] was significantly longer in the MM group [29.6 minute versus 7.2 minutes ($p = < 0.0001$)], and so was the postoperative hospitalization [2.6 days versus 1.5 days ($p = < 0.001$)]

Patients who had undergone RA of hemorrhoids could pass motion much earlier as compared to the patients who underwent MM hemorrhoidectomy. [1.4 days versus 2.3 days ($p = < 0.001$)]

Serous discharge and anal pruritus were present in both groups, but the duration of discharge was

longer in the RA group. [17 days versus 11 days in the MM group ($p = < 0.0001$)]

The time elapsing before returning to work or full activity was significantly shorter in the RA group (median = 7.3 days) when compared with the MM group (median = 18.3 days) ($P = < 0.0001$).

Wound healing was observed by parting the buttocks of the patients in the MM group and was confirmed by inserting a well-lubricated pediatric anoscope in both the groups. The wound healing took much less time in the RA group with a median period of 16.3 days than in its counterpart, where healing took a median time of 37.5 days to complete. ($P = < 0.0001$).

The duration and intensity of pain after defecation and at rest were significantly greater in the MM group in comparison to the RA group. [Fig. 1-2]

Local changes observed after RA of the pile mass

During anoscopic examination at 4 weeks follow up, the hemorrhoidal mass looked shrunken and segmented. At 12 months follow up the pile mass was replaced by fibrous bands.

Complications

Acute urinary retention developed in four patients, [Table 3], three from the MM group and one from the RA group ($p = < 0.001$). All of them required catheterization once. None of them had this complaint again.

Two patients from the MM group and one from the RA group needed readmission to the hospital due to secondary bleeding in the 2nd week of the procedure. One from each group responded to conservative treatment in the form of local compression and haemostatic. However, the remaining one from the MM group needed

Table 3 Early and late complications [by the number of patients]

Complications	MM group (n = 20)	RA group (n = 20)	P
Urinary retention	3	1	< 0.001
Bleeding	2	1	< 0.001
Incontinence to flatus	4	2	< 0.001
External tags	2	4	< 0.001
Recurrence	0	1	< 0.001
Anal stenosis	1	0	< 0.001

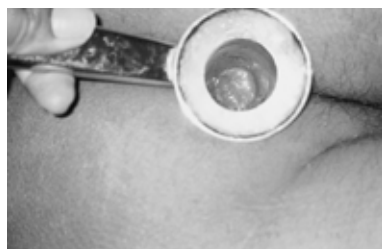

Fig. 1B Anoscopy picture after 4 weeks.

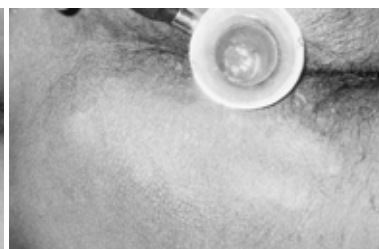

Fig. 2B Anoscopy picture after 12 months.

resuturing under anesthesia to control the bleeding.

While none of the patients in either group complained of any incontinence of feces, 4 patients from the MM group and 2 patients from the RA group had incontinence for flatus for about 3 weeks after the procedure [$p = < 0.001$].

At a follow up after 12 months, 4 patients from the RA group had developed external skin tags. Similar tags were seen in 2 patients from the MM group.

One patient from the RA group was found to have hemorrhoids during anoscopic examination. However, he did not have any complaints. He was prescribed laxatives and was instructed not to strain at stool. No such recurrence was found in the MM group.

One patient from the MM group developed narrowing of the anal canal. The digital anal examination was painful. He was subjected to regular anal dilatation and bulk forming laxative, Isapgulla, 2 teaspoons at bedtime.

Discussion

Radio surgery, unlike electro surgery, diathermy, spark-gap circuitry, or electrocautery, uses a very

high frequency radio wave of 4 MHz¹¹.

As compared to electrocautery or diathermy, the radiofrequency electrode remains cold during application. This is possible because of the use of very high frequency current of 4 MHz, as compared to 0.5 to 1.5 MHz used in the electrocautery¹². As contrast to true cautery, which causes damage similar to 3rd degree burns, the tissue damage that does occur in the RF technique is very superficial and comparable to that which occurs with Lasers¹³. Histologically, it has been shown that tissue damage with radio surgery is actually less when compared with the conventional scalpel and is equal to the cold scalpel¹⁴. CO₂ and Nd:YAG lasers are already in use as scalpel and coagulator for laser hemorrhoidectomy¹⁵. However, in-situ RA of hemorrhoids is a new approach to the treatment of hemorrhoids.

Hippocrates suggested the burning of hemorrhoids as a mode of treatment¹⁶. Infra red heat coagulation¹⁷, bipolar diathermy destruction¹⁸[Bicap], CO₂ or Nd:YAG laser coagulation¹⁹, direct current probe²⁰ [Ultroid] of hemorrhoids, coagulation by heater probe²¹ are the commonly employed forms of heat destruction of hemorrhoids²². A 'suture-less' hemorrhoidectomy using an electro-surgical method has been successfully used. A tissue welding has

been done and results comparable to conventional hemorrhoidectomy have been obtained²³. Radio surgical hemorrhoidectomy by bistury has been used with good success²⁴.

Time taken for the procedure

RA can be performed in almost one fourth of the time taken in the conventional procedure.

Postoperative pain

Radiofrequency has been found to successfully seal the sensory nerve endings and the leaking lymphatic²⁵. Because of the low level of tissue destruction and controlled direction of the radio wave current, there is an appreciable fall in the amount of postoperative pain²⁶.

Hospital stay

Most of the patients operated on with RA were discharged within 30 hrs of the procedure. This was possible due to less postoperative pain, early bowel evacuation and minimal discomfort in the bodily movements.

Period off work

The patients operated on by the RA technique were able to join their duties earlier than the patients operated on by the conventional method.

Functional Impairment

None of the patients in either of the studies had any fecal incontinence. 20% of the patients did complain of inadequate control to hold flatus in the conventional procedure group, while only 10% patients operated on by RA had such complaints.

Time taken for complete healing of the wound

The precise functioning of the radiofrequency equipment is that a very little normal tissue is damaged while ablating the offending tissues²⁷. It could possibly be termed as a minimally invasive procedure compared to the conventional procedure in the process of removing the affected tissues²⁸.

Anal discharge

The longer duration of discharge per anus in the

RA group was probably due to the sloughing of the hemorrhoidal mass after coagulation.

Postoperative anal stenosis

The commonest reason for narrowing of the anal canal is excessive removal of the anoderm, which gives rise to fibrosis and cicatrisation of the anal canal.

As RA does not cause any injury to the anoderm, there was no incidence of anal stenosis as against one noticed in the MM group.

Postoperative bleeding

There was no significant difference between the two groups in terms of postoperative bleeding.

Development of external skin tags

The development of external skin tags after RA of hemorrhoids was probably due to development of perianal thrombosis due to the obstruction to venous return from the external hemorrhoidal plexus caused by the coagulation of the hemorrhoids, which leads to elongation of the skin.

Asymptomatic recurrence

The RA of the hemorrhoidal mass helps in tethering the mucosa to the underlying ano rectal wall. This prevents the possibility of recurrence. However, one of the patients in this study developed this complication.

The in-situ destruction of the hemorrhoid mass with radiofrequency has the following advantages-

(a) precise destruction of the hemorrhoid area of the rectum, sealing of nerve endings and lymphatic resulting in diminished pain and anal discharge; (b) healing through fibrosis by fixing the mucosa to the wall the of the rectum, and thereby preventing recurrence; (c) ease of application of RF as a day care procedure with minimal requirement of after care, resulting in saving on the treatment costs; (d) the RF coagulated area is aseptic and exiguous bacteria are unable to penetrate the necrotic zone formed by heat coagulation of hemorrhoids, which acts as its own dressing²⁹.

In none of the patients in our study of in-situ radiofrequency coagulation of hemorrhoids or in the

study of Wang et al²⁹ was there any significant morbidity. Similarly, for associated secondary hemorrhoids, radiofrequency coagulation was found to be an ideal tool. Procedures like diathermy and stapled hemorrhoidectomy are associated with a late complication of rectal stricture in almost 4 to 5% of the patients. But none of the patient under our study had this complaint³⁰. Four of the patients in our study had skin tag formation. This complication is also seen after diathermy and stapled hemorrhoidectomy³¹.

If compared to electrocautery or lasers, there is minimal or no heat generated at the surgical site after RA. This allows the surgeon to work in direct proximity of the functional tissues that need to be preserved like the intervening normal rectal mucosa in the case of hemorrhoids³².

Except for the radiofrequency unit, our procedure needs no specialized instrument. The equipment is cost effective, as no disposables are needed, as is the case with stapled hemorrhoidectomy. The procedure could be conveniently performed in any routine surgical set up³³.

Conclusion

The study shows that in-situ RA of hemorrhoids offers several advantages over MM hemorrhoidectomy, as the procedure is quick to perform, easy to learn and bloodless in nature. It is appreciably less painful in the postoperative course.

The wound healing is faster and return to work is much sooner. Similarly, the duration of hospitalization and loss of working days are appreciably less.

A long-term follow up, no doubt, is needed to assess the duration of relief and development of some unforeseen side effects. Continued work in this area should provide promising new dimensions in the management of advanced stages of hemorrhoids.

References

1. Milligan ETC, Morgan CN, Jones LE, Officer R: Surgical anatomy of the anal canal and operative treatment of haemorrhoids. *Lancet* 1937; 2: 1119-1124.
2. Mikuni N, Oya M, Komatsu J, Yamana T: A Prospec-

3. Huang S: Advances in applications of radiofrequency current to catheter ablation therapy. *PACE* 1991; 14: 28-42.
4. Goldberg SN, Gazelle GS: Radiofrequency tissue ablation: Physical principles and techniques for increasing coagulation necrosis-Hepatogastroenterology 2001; 48: 359-367.
5. Goldberg SN, Gazelle GS, Dawson SL, et. al: Tissue ablation with radiofrequency: effect of probe size, gauge, duration and temperature on lesion volume. *Acad Radiol* 1995; 2: 399-404.
6. Nivatvongs S, Fang DT, Kennedy HL: The shape of the buttocks. A useful guide for selection of anesthesia and patient position in anorectal surgery. *Dis Colon Rectum* 1983 Feb; 26: 85-86.
7. Khalil KH, O' Bichere A, Sellu D: Randomized clinical trial of sutured versus stapled closed hemorrhoidectomy. *Br J Surg* 2000 Oct; 87: 1352-1355.
8. Moringa K, Hasuda K: A novel therapy for internal hemorrhoids. Ligation of the hemorrhoidal artery with a newly devised instrument [Moricorn] in conjunction with a Doppler flow meter. *Am J Gastroenterol* 1995 Apr; 90: 610-613.
9. Milito G, Cortese F, Anselmo A, Casciani U: Treatment of hemorrhoidal peduncles with diathermy probe. *Ann Ital Chir* 1995 Nov-Dec; 66: 801-803.
10. Ingram M, Wright TA, Ingoldby CJ: A prospective randomized study of calcium alginate (Sorbsan) versus standard gauze packing following haemorrhoidectomy. *J R Coll Surg Edinb* 1998 Oct; 43: 308-309.
11. Wedman J, Miljeteig H: Treatment of simple snoring using radio waves for coagulation of uvula and soft palate: a day-case surgery procedure *Laryngoscope* 2002 Jul; 259: 1256-1259.
12. Pfenninger JL, Zainea GG, Common Anorectal Conditions, Part II (lesions), *American family physician* 2001 Jul; 64: 77-88.
13. Saidi MH, Setzler FD Jr., Saddler RK, Farhart SA, Akright BD: Comparison of office loop electro surgical conization and cold knife conization. *J Am Assoc Gynecol laparosc* 1994 Feb; 1: 135-139.
14. Valinsky MS, Hettinger DF, Gennett PM: Treatment of Verrucae via Radio wave Surgery. *J Am Podiatr Med Assoc* 1990 Sep; 80: 482-488.
15. Rowsell M, Bello M, Hemingway DM: Pain after stapled haemorrhoidectomy. *Lancet* 2000 Dec 23-30; 356: 2188.
16. Hughes E, Cuthberton A, Killinbach K: In: *Colorectal Surgery* 1983: pp 178-202. Churchill Livingstone, London.
17. Leicester RJ, Nicholls RJ, Mann CV, Infra red coagulation: a new treatment for hemorrhoids. *Dis Colon Rectum* 1981 Nov-Dec; 24: 602-605.
18. Smith LE: Hemorrhoids. A review of current techniques and management. *Gastroenterol Clin*

- North Am 1987 Mar; 16: 79-91.
19. Tajana A, Chiurazzi D, De Lorenzi I: Infra red photocoagulation, cryosurgery and laser surgery in hemorrhoidal disease. *Ann-Ital-Chir* 1995 Nov-Dec; 66: 775-782.
 20. Norman DA, Newton R, Nicholas GV: Direct current electrotherapy of internal hemorrhoids: an effective, safe, and painless outpatient approach. *Am J Gastroenterol* 1989 May; 84: 482-487.
 21. Jensen DM, Jutabha R, Machicado GA, Jensen ME, Cheng S, Gornbein J, Hirabayashi K, Ohning G, Randall G: Prospective randomized comparative study of bipolar electrocoagulation versus heater probe for treatment of chronically bleeding internal hemorrhoids. *Gastrointest Endosc* 1997 Nov; 46: 435-443.
 22. Leff EI: Hemorrhoidectomy-Laser versus non-laser outpatient surgical experience. *Dis. colon Rectum* 1992 Aug; 35: 743-746.
 23. Sayfan J, Becker A, Koltun L: Sutureless closed hemorrhoidectomy: a new technique. *Ann Surg* 2001 Jul; 234: 21-24.
 24. Filingeri V, Casciani CU: Submucosal hemorrhoidectomy with a radiofrequency bistoury. *Minerva Chir* 1997 Oct; 52: 1255-1259.
 25. Hussain SA, Hussain S: Incisions with knife or diathermy and postoperative pain. *Br j Surg* 1988; 75: 1179-1180.
 26. Valinsky MS, Hettinger DF, Gennett PM: Treatment of Verrucae via Radio wave Surgery. *Journal of the American Podiatric Medical Association* 1990; 80: 482-488.
 27. Saidi MH, Setzler KR, Farhart SA, Akright BD: Comparison of office loop electrosurgical conization and cold knife conization. *Journal of the American Association of Gynecologic laparoscopists* 1994; 1: 135-139.
 28. Kainz C, Tempfer C, Sliutz G, et al: Radio surgery in the management of cervical intraepithelial neoplasia. *Journal of Reproductive Medicine* 1996; 41: 409-411.
 29. Wang JY, Chang-Chien CR, Chen JS, Lai CR, Tang R P: The role of lasers in hemorrhoidectomy. *Dis Colon Rectum* 1991 Jan; 34: 78-82.
 30. Fazio VW: Early promise of stapling technique for hemorrhoidectomy. *Lancet* 2000; 355: 768-769.
 31. Rowsell M, Belio M, Hemingway DM: Circumferential mucosectomy [stapled hemorrhoidectomy] versus conventional hemorrhoidectomy: randomized controlled trial. *Lancet* 2000 Mar 4; 355: 779-781.
 32. Pfenninger JL, Zainea GG: Common Anorectal Conditions, Part II (lesions), *American family physician* 2001 Jul; 64: 77-88.
 33. Gupta PJ: Novel technique: radiofrequency coagulation—a treatment alternative for early-stage hemorrhoids. *Med Gen Med* 2002; 4: 1-9.

(Received, February 13, 2003)

(Accepted, March 31, 2003)