

—Report on Experiments and Clinical Cases—

Two Cases of Acute Myositis Associated with Influenza A
Virus Infection in the ElderlyKenzo Oba, Aki Nishihara, Kojiro Okamura, Yumiko Ajiro, Yu Yamaguchi, Kyoji Okazaki,
Shuzo Sato, Tastuya Suzuki, Hiroshi Nakano and Shohei Metori

The Division of Geriatric Medicine, Nippon Medical School

Abstract

During the influenza epidemic of 1998–1999, we observed two elderly patients with influenza-like symptoms who had evidence of acute myositis with elevated serum enzymes. Influenza A infection was confirmed serologically in either case. The present cases suggest that it is important to distinguish influenzal myositis from other forms of myopathy in the elderly patients. (J Nippon Med Sch 2000; 67: 126–129)

Key words: acute myositis, influenza A, elderly**Introduction**

Acute myositis associated with Influenza A or B infection has been described in children during epidemics^{1–4}, but we rarely find such cases in the elderly^{5,6}. During the influenza epidemic of 1998~1999, we observed two elderly patients with acute myositis resulting from Influenza A infection. Other cases hitherto reported in the literature are briefly reviewed.

Case reports**1. Case 1 (Fig. 1)**

A 77-year-old male was admitted to the hospital on Jan 4, 1999, because of quadriplegia and dysarthria following a 7-day history of flu-like symptoms. On physical examination, the patient could not stand or walk because of diffuse leg weakness. The patient height was 162 cm and body weight was 58.6 kg. His temperature was 37.6°C, blood pressure was 190/90 mmHg, and pulse rate was 88 beats per minute and ir-

regular. The palpebral conjunctiva was not anemic and the bulbar conjunctiva was not icteric. No abnormalities were observed in the thorax. The abdomen was soft and flat, and the liver and the spleen were not palpable. No superficial lymph nodes were palpable. Muscle strength was diminished in all the extremities, predominately in the lower extremities. Sensation was normal, but deep tendon reflexes were diminished without pathological reflex such as Babinski reflex.

Blood examination showed a C-reactive protein (CRP) of 3.2 mg/dl, an erythrocyte sedimentation rate of 21 mm/h, and a white blood cell count of 10,200/ μ l with 79.3% polymorphonuclear leukocytes, 11.7% monocytes, 8.0% lymphocytes, and 0.8% eosinophils. The AST was 71 IU/l, ALT 25 IU/l, alkaline phosphatase 177 IU/l, LDH 544 IU/l, CK 3827 IU/l, aldolase 28.4 IU/l/37°C and myoglobin was 787 ng/ml. The MM fraction of CK was 99%. No abnormal sign was found on X-ray examination of the chest or the abdomen. The electrocardiogram showed atrial fibrillation.

Correspondence to Kenzo Oba MD, The Division of Geriatric Medicine, Nippon Medical School, 1-1-5 Sendagi, Bunkyo-ku, Tokyo, 113-8603, Japan

Journal Website (<http://www.nms.ac.jp/jnms/>)

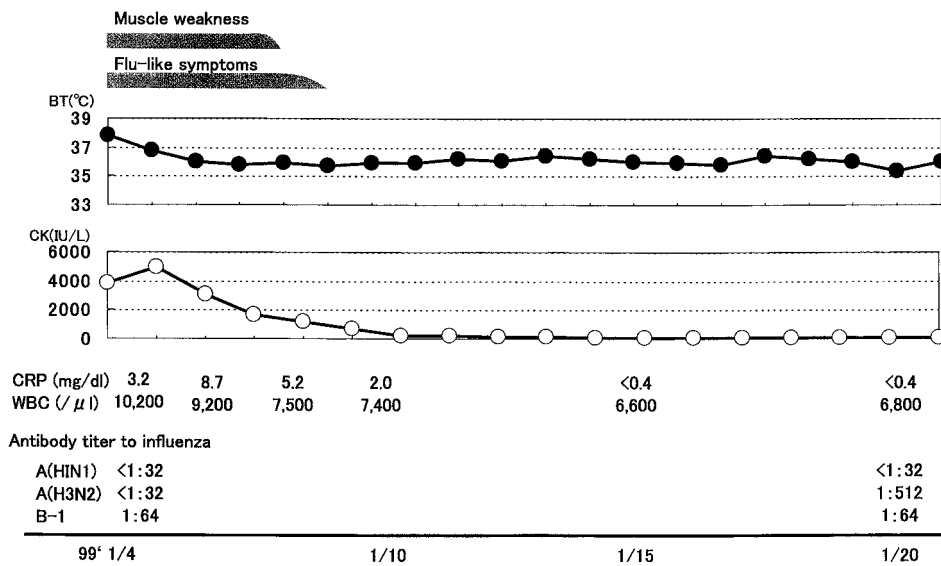


Fig. 1 Clinical course of case 1.

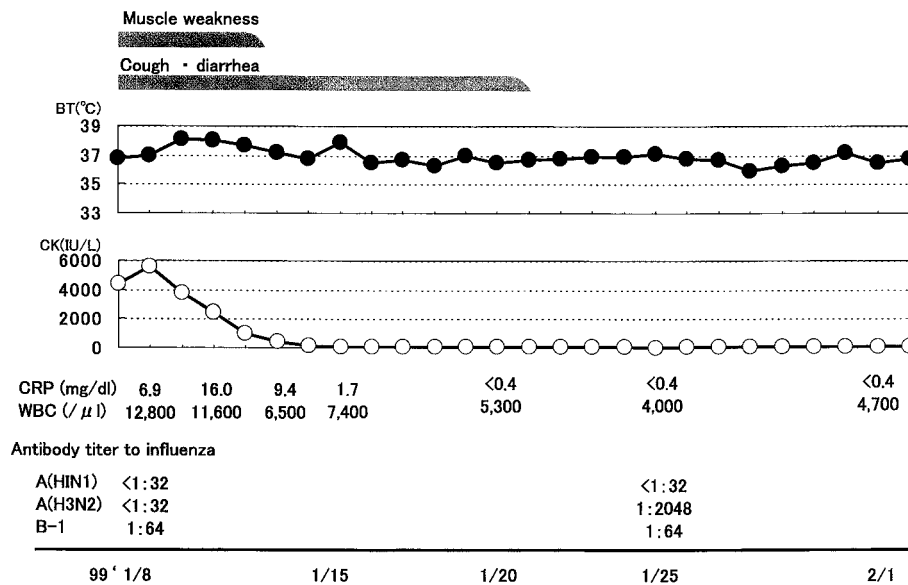


Fig. 2 Clinical course of case 2

One week after the admission, both muscle weakness of the limbs and dysarthria disappeared. Between the first and 17 th hospitalization days, his hemagglutination inhibition titer to Influenza A (H3N2) elevated from 1: 32 to 1: 512.

2. Case 2 (Fig. 2)

A 60-year-old female with a history of Type 2 diabetes mellitus was admitted to the hospital on Jan 8, 1999, because of muscle weakness of the limbs and watery diarrhea following a 6-day history of flu-like symptoms. On physical examination, the patients was drowsy and could not arise from bed. She was 144.5

cm tall and weighed 59.0 kg. Her temperature was 36.9°C, blood pressure was 106/66 mmHg, and pulse rate was 70 beats per minute and regular. The palpebral conjunctiva was not anemic and the bulbar conjunctiva was not icteric. No abnormalities were observed in the thorax. The abdomen was soft and flat, and the liver and the spleen were not palpable. No superficial lymph nodes were palpable. Muscle strength was diminished in all the extremities, predominating on the lower extremities. Sensation was normal, but deep tendon reflexes were diminished without pathological reflex such as Babinski reflex.

C-reactive protein (CRP) was 6.9 mg/dl, and the

Table 1 Reported cases of influenzal myositis in the elderly

Author	Year	Age/sex	Myalgia	Muscle weakness	Elevation in CK	Prognosis	Type *
Gamboa ET ⁷⁾	1979	65/M	+	+	+	Died	B
Cunningham E ⁸⁾	1979	76/F	+	+	+	Improved	A
Kessler HA ⁹⁾	1980	72/M	-	+	+	Improved	A
Baine WB ¹⁰⁾	1980	73/M	-	+	+	Improved	B
	1980	61/M	+	+	+	Improved	B
Congy F ⁵⁾	1980	84/M	-	+	+	Improved	A
Hoshino M ¹¹⁾	1989	67/M			+	Improved	A
Honda K ¹¹⁾	1991	79/M	+	+	+	Improved	A
Yamakoshi M ⁶⁾	1995	82/F	-	+	+	Improved	A
	1995	83/M	-	-	+	Improved	A
	1995	81/M	-	+	+	Improved	A
	1995	87/M	-	+	+	Improved	A
present case 1	1999	77/M	-	+	+	Improved	A
2	1999	60/F	-	+	+	Improved	A

* Type; Type of influenza virus

erythrocyte sedimentation rate was 57 mm/h. The white blood cell count was 12,800/ μ l with 91.5% polymorphonuclear leukocytes, 2.0% monocytes, 6.5% lymphocytes, and 0.0% eosinophils. The AST was 59 IU/l, ALT 162 IU/l, alkaline phosphatase 119 IU/l, LDH 936 IU/l, CK 4221 IU/l, aldolase 18.3 IU/l/37°C and myoglobin was 1515 ng/ml. The MM fraction of CK was 99%. No abnormal sign was found on X-ray examination of the chest or the abdomen. The electrocardiogram was normal. Abdominal ultrasonography revealed fatty liver.

She was immediately treated with intravenous fluid replacement and antibiotics. The CRP and CK gradually decreased and, approximately one week later, her muscle weakness of the limbs disappeared. Between the third and 18 th hospital days, her hemagglutination inhibition titer to Influenza A (H3N2) rose from <1: 32 to 1: 2048.

Discussion

In the present cases, we believe that influenza A induced acute myositis. The resolution of the muscle weakness, return of muscle enzyme values to normal, and the increase in Influenza A (H3N2) titer in the convalescent-phase support the etiologic role of influenza A virus infection in their muscle disorders.

Acute influenzal myositis seems to be a disease of children, usually with acute myalgia of the legs, often

appearing during recovery from the respiratory illness^{1,2}. Muscle weakness is uncommon, enzyme elevation may be modest, and these signs resolve within a few days⁴. The cause of the higher incidence of influenzal myositis in early life is not known.

The clinical characteristics of 12 previously reported⁵⁻¹¹ cases of influenzal myositis in the elderly as well as the characteristics of the present patients are listed in **Table 1**. Their ages ranged from 61 to 87 years. There were 11 male and 3 female patients. Many reports revealed that the incidence of influenzal myositis was higher in male than in female^{3,4}. In these elderly cases, many authors did not mention myalgia as a clinical feature. Only 4 of the fourteen cases had myalgia. Numerous studies have described myalgia as a common feature of influenza in children³. Although the number of patients is small, the incidence of influenzal myositis with myalgia in the elderly may be lower than that in children. It is well-known that clinical features of many diseases in the elderly patients are more likely to be atypical and diagnoses less complete than in younger patients.

The prognosis was good, except for one case who died of pulmonary embolism⁷. However, in the review by Singh et al¹², 3 (12%) of 25 patients with influenza-induced rhabdomyolysis died. Acute renal failure from influenza-associated rhabdomyolysis has been described in adults^{13,14} and, rarely, in children¹⁵. In adults, symptoms vary from simple myalgia to tender-

ness to severe myoglobinuria⁸. In the previously mentioned review by Singh et al¹², 11 (44%) of 25 patients with influenza-induced rhabdomyolysis had acute renal failure.

Whether muscle damage is caused by a direct pathologic effect of viruses on muscle cells or is secondary to muscle cell damage with subsequent autoimmune process is unknown. In 1979, Gamboa et al.⁷ definitively documented influenza virus in a skeletal muscle specimen from patient with influenza virus infection. Subsequently, Kessler et al.⁹ also cultured influenza virus type A from a muscle specimen from a 72-year-old man with virus-induced myopathy. These evidences strongly suggest that direct viral invasion may have a causative role in precipitating acute myositis.

In conclusion, we report here two elderly patients with acute myositis resulting from Influenza A infection. Physicians should be aware of the association between influenza infection and acute myositis to facilitate optimal treatment of elderly patients.

References

1. Middleton PJ, Alexander RM, Szymanski MT: Severe myositis during recovery from influenza. *Lancet* 1970; 2: 533-535.
2. Dietzman DE, Schaller JG, Ray CG, Reed ME: Acute myositis associated with influenza B infection. *Pediatr* 1976; 57: 255-258.
3. Farrel MK, Partin JC, Bove KE, Jacobs R, Hilton PK: Epidemic influenza myopathy in Cincinnati in 1977. *J Pediatr* 1980; 96: 545-551.
4. Mckinlay IA, Mitchell I: Transient acute myositis in childhood. *Arch Dis Child* 1976; 51: 135-137.
5. Congy F, Hauw JJ, Wang A, Moulia R: Influenzal acute myositis in the elderly. *Neurol* 1980; 30: 877-878.
6. Yamakoshi M, Yamamoto T, Suzuki K, Yamamoto T: Four cases in the elderly of acute myositis associated with influenza A infection. *J J A Infect Dis* 1995; 69: 752-756 (in Japanese).
7. Gamboa ET, Eastwood AB, Hays AP, Maxwell J, Penn AS: Isolation of influenza virus from muscle in myoglobinuric polymyositis. *Neurol* 1979; 29: 1323-1335.
8. Cunningham E, Kohli R, Venuto RC: Influenza-associated myoglobinuric renal failure. *JAMA* 1979; 242: 2428-2429.
9. Kessler HA, Trenholme GM, Harris AA, Levin S: Acute myopathy associated with influenza A/Texas/1/77 infection. Isolation of virus from a muscle biopsy specimen. *JAMA* 1980; 243: 461-462.
10. Baine WB, Luby JP, Martin AM: Severe illness with influenza B. *Am J Med* 1980; 68: 181-189.
11. Honda K, Shirai H, Igarashi H, Sugawara Y: An elderly case of benign influenza A myositis. *Naika* 1993; 71: 565-567 (in Japanese).
12. Singh U, Scheld WM: Infectious etiologies of rhabdomyolysis: Three case reports and review. *Clin Infect Dis* 1996; 22: 642-649.
13. Gabow PA, Kaehny WD, Kelleher SP: The spectrum of rhabdomyolysis. *Medicine* 1982; 61: 141-152.
14. Berry L, Braude S: Influenza A infection with rhabdomyolysis and acute renal failure: A potentially fatal complication. *Postgrad Med J* 1991; 67: 389-390.
15. Goebel J, Harter HR, Boineau FG, El-Dahr SS: Acute renal failure from rhabdomyolysis following influenza A in child. *Clin Pediatr* 1997; 36: 479-481.

(Received, November 11, 1999)

(Accepted, December 8, 1999)