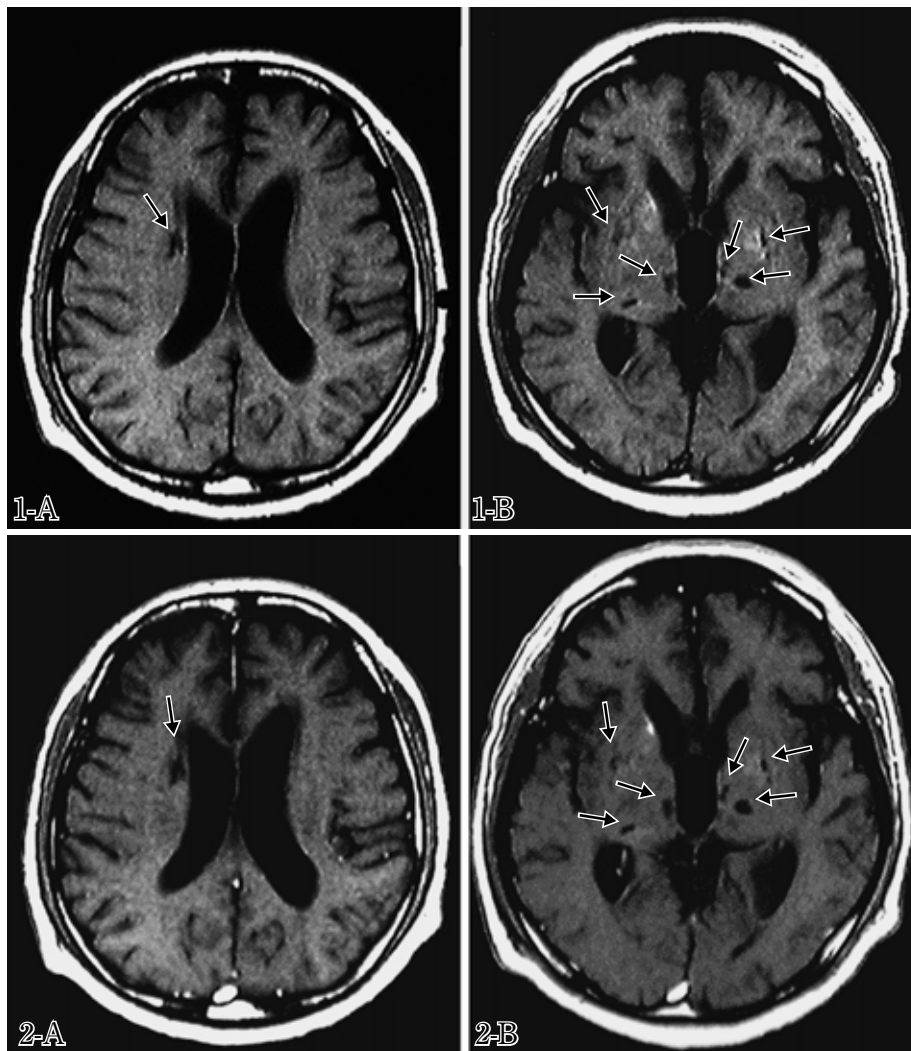


—Photogravure—

**Brain MRI Findings in Cryptococcal Meningoencephalitis**

Kazuhiro Usuda and Yasuo Katayama

Second Department of Internal Medicine, Nippon Medical School

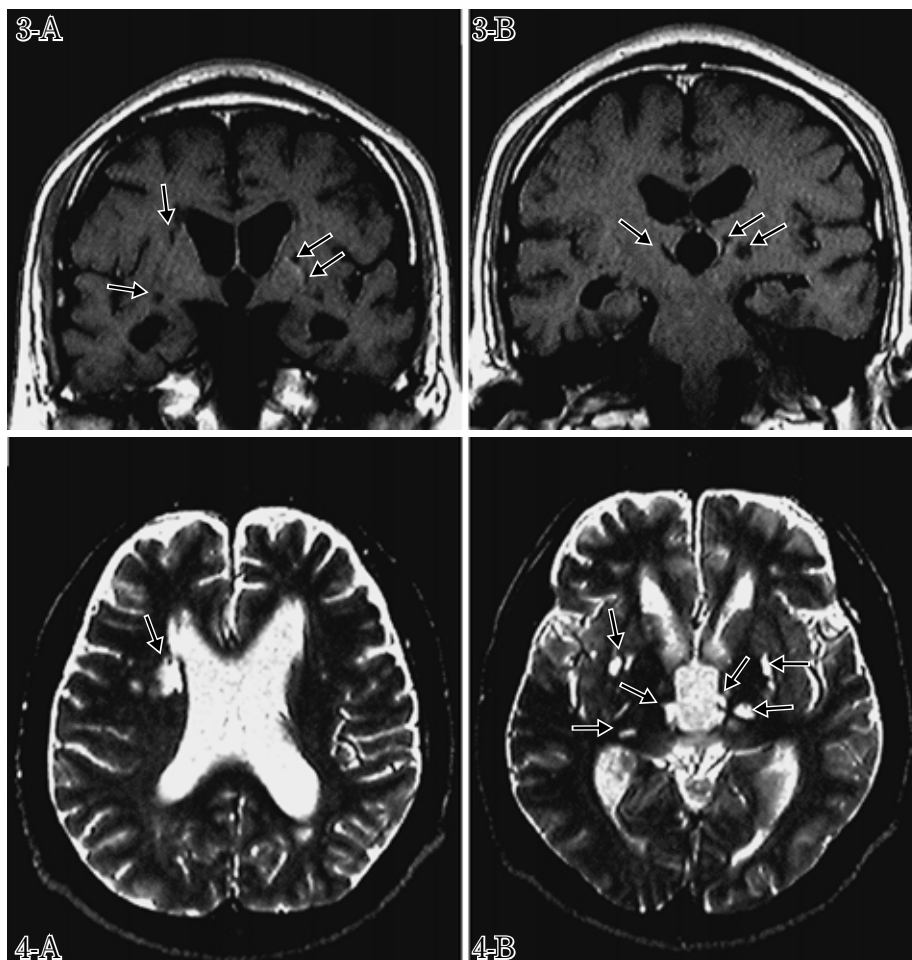


*Cryptococcus neoformans* is pathogenic in immunocompromised patients, such as acquired immune deficiency syndrome (AIDS) patients. Brain MRI findings in cryptococcal meningoencephalitis are described in this photogravure.

Inhalation is the usual mode of infection, and hematogenous spread to the central nervous system (CNS) results in diffuse subacute meningitis. The dural and leptomeningeal involvement and associated inflammatory reaction are mild, so dural and leptomeningeal enhancement can hardly be seen (**Fig. 1A·B, 2A·B and 3A·B**). An Arachnoid cyst filled with a mucoid material produced by the fungus can be seen within the subarachnoid space.

Spread of infection to the cortex and parenchyma occurs via Virchow-Robin (V-R) spaces. Dilated V-R spaces are perivascular spaces that become distended with the fungus and mucoid material, which promotes enlargement of the perivascular spaces. They are small punctate rounded lesions less than 3 mm in size, and are hyperintense on T2-weighted images and of low signal on T1-weighted images. They are most evident in the bilateral basal ganglia, and are often symmetric (**Fig. 1A·B and 4A·B**). Gadolinium enhancement is seldom seen in these lesions. The foci are not associated with edema or mass effect (**Fig. 2A·B and 3A·B**).

With disease progression these V-R spaces increase in size, resulting in the development of cryptococcomas, which extend into the parenchyma. These cryptococcomas are composed of gelatinous masses of cryptococcal



organisms. They are primarily seen in the basal ganglia, and may be bilateral. They are hyperintense on T 2-weighted images and of low signal on T 1-weighted images, and do not demonstrate edema or enhancement, although there may be mass effect depending on the size of the lesion. They vary in size from less than 3 mm to several centimeters.

Hydrocephalus is present among non-AIDS patients with CNS cryptococcal infection (**Fig. 1A·B, 2A·B, 3A·B and 4A·B**), but is less common in the immunocompromised population with CNS cryptococcosis because of the lack of inflammatory leptomeningeal reaction and the paucity of resulting adhesions within the basal cisterns.

**Fig. 1A·B** Axial T1-weighted images (450/15) of non-AIDS patient with CNS cryptococcal infection demonstrate foci of low signal in the bilateral basal ganglia and thalami without mass effect (arrows). While the majority of these lesions represent dilated V-R spaces filled with cryptococcal fungi and mucoid material, the larger lesions likely represent small cryptococcomas. These are difficult to distinguish radiographically. Hydrocephalus is present.

**Fig. 2A·B** Postgadolinium axial T1-weighted (450/15) scans of non-AIDS patient with CNS cryptococcal infection show the non-enhancing lesions in the basal ganglia and thalami (arrows). Dural and leptomeningeal enhancement is not detected.

**Fig. 3A·B** Postgadolinium coronal T1-weighted (450/15) images of non-AIDS patient with CNS cryptococcal infection demonstrate non-enhancing lesions in the basal ganglia and thalami (arrows). No abnormal dural or leptomeningeal enhancement is detected.

**Fig. 4A·B** Axial T2-weighted images (2500/100) of non-AIDS patient with CNS cryptococcal infection demonstrate foci of high signal in the bilateral basal ganglia and thalami without mass effect (arrows).

**解説：**クリプトコッカスは肺から血行性に造影効果のない髄膜炎を起こす。髄膜病変はムコイド様物質で満たした Virchow-Robin 腔に沿って進展し、T 1 強調画像で低信号、T 2 強調画像で高信号の造影効果のない 3 mm 以下の病変が脳基底核領域に認められる。さらに、Virchow-Robin 腔の病変は拡大し脳実質内に肉芽腫を形成し、T 1 強調画像で低信号、T 2 強調画像で高信号の造影効果のない 3mm 以上数 cm の病変が脳基底核領域にみられる。

#### References

Miszkiel KA, Hall-Craggs MA, Miller RF, Kendall BE, Wilkinson ID, Paley MN, Harrison MJG : The spectrum of MRI findings in CNS cryptococcosis in AIDS. *Clinical Radiology* 1996; 51: 842-850.