

—Report on Experiments and Clinical Cases—

An Elderly Patient with Gastric Carcinoma Developing Multiple Metastasis in Skeletal Muscle

Kenzo Oba¹, Tami Ito¹, Chizuko Nakatani¹, Kojiro Okamura¹, Hiroshi Yamaguchi¹,
Yumiko Ajiro¹, Tatsuya Suzuki¹, Hiroshi Nakano¹, Shohei Metori¹,
Kazufumi Sano², Hiko Hyakusoku² and Nobutaka Yamada³

¹Division of Geriatric Medicine, Nippon Medical School

²Department of Plastic and Reconstructive Surgery, Nippon Medical School

³Department of Pathology, Nippon Medical School

Abstract

We present a 70-year-old man with gastric carcinoma developing multiple metastasis in skeletal muscle. He had a right supraclavicular lymph node swelling. Brain, chest and abdomen CT scans revealed metastatic lesions in the brain, lung, liver and bilateral adrenal glands. Further, CT showed a ring enhanced soft-tissue mass in the left lumbar muscle. Needle aspirate of the mass in both the left lumbar muscle and the right enlarged supraclavicular lymph node revealed cells suggestive of poorly differentiated adenocarcinoma. Upper gastrointestinal endoscopic evaluation demonstrated an advanced gastric carcinoma. Two months after admission, the tumor in the left lumbar muscle had grown and some new lesions in the left iliopsoas muscles appeared. Intramuscular metastasis from gastric carcinoma is an extremely rare phenomenon.

(J Nippon Med Sch 2001; 68: 271—274)

Key words: gastric carcinoma, skeletal muscle, metastasis, elderly

Introduction

Gastric carcinoma occurs with high frequency and is a significant cause of cancer mortality in Japan. The most common metastatic sites of gastric carcinoma are the liver, regional lymph nodes, bone and adrenal gland. Intramuscular metastasis from gastric carcinoma is an extremely rare phenomenon. Only several sporadic cases have been reported¹⁻⁶.

We report here a case of a patient with gastric carcinoma developing multiple metastasis in the skeletal muscle.

Case report

A 70-year-old man was admitted on 21 February 2000 because of gait disturbance, dysarthria and fever following a 7-day history of cold-like symptoms. On admission, he was 162 cm in height and 44 kg in weight. He had a temperature of 36.4°C, a heart rate of 68 beats/min (regular), and blood pressure of 146/80 mmHg. He was drowsy and poorly oriented. The palpebral conjunctiva was not anemic and the bulbar conjunctiva was not icteric. No abnormalities were observed in the thorax. The abdomen was soft and flat, and the liver and the spleen were not palpable. Right supraclavicular lymph node swelling (5 cm in diame-

Correspondence to Kenzo Oba, MD, The Division of Geriatric Medicine, Nippon Medical School, 1-1-5 Sendagi, Bunkyo-ku, Tokyo, 113-8603, Japan

E-mail: ohba@nms.ac.jp

Journal Website (<http://www.nms.ac.jp/jnms/>)

ter) was present. Mild weakness with exaggerated deep tendon reflexes were observed in the left upper and lower extremities with no pathological reflex such as Babinski reflex.

Laboratory findings on admission: urinalysis was normal, C-reactive protein (CRP) 2.4 mg/dl, red blood cell (RBC) count $360 \times 10^4/\text{mm}^3$, hematocrit (Ht) 33.5%, hemoglobin (Hb) 11.7 g/dl, platelet count $41.1 \times 10^4/\text{mm}^3$ and white blood cell (WBC) count of $9,000/\text{mm}^3$ (polymorphonuclear leukocyte 77.7%, monocyte 9.1%, lymphocyte 8.4%, eosinophil 4.2%, basophil 0.6%). Serum values were aspartate aminotransferase (AST) 15 IU/l (normal: 10~30), alanine aminotransferase (ALT) 15 IU/l (normal: 5~33), and lactate dehydrogenase (LDH) 361 IU/l (normal: 180~460), uric acid 2.8 mg/dl, blood urea nitrogen (BUN) 12.8 mg/dl, creatinine (Cr) 0.94 mg/dl, total protein 6.2 g/dl, albumin 2.8 g/dl, total cholesterol 116 mg/dl, triglycerides 54 mg/dl, Na 129 mEq/l, K 4.3 mEq/l, Cl 93 mEq/l and Ca 8.5 mg/dl. Carcinoembryonic antigen (CEA) and carbohydrate antigen 19-9 (CA 19-9) were markedly elevated at 220 ng/ml (normal: not more than 2.5) and 110 U/ml (normal: not more than 37), respectively.

Chest X-rays demonstrated a round mass in the left middle lung field. Contrast computed tomography of the brain showed a highly enhanced mass (1 cm in diameter), together with edema around the area in the right temporal lobe. Chest and abdomen CT scans with enhancement revealed metastatic lesions in the lung, liver and bilateral adrenal glands. Further, CT showed a ring enhanced soft-tissue mass in the left lumbar muscle (**Fig. 1**). Needle aspirate of both the mass in the left lumbar muscle and the right enlarged supraclavicular lymph node revealed cells suggestive of poorly differentiated adenocarcinoma. These clinical and histological features were suggestive of metastatic carcinoma. Accordingly, we searched for an occult malignancy. Upper gastrointestinal endoscopic evaluation demonstrated an advanced gastric carcinoma. Biopsies revealed poorly differentiated adenocarcinoma (**Fig. 2**).

He was thus diagnosed as having gastric carcinoma with metastases to the brain, liver, lung, adrenal glands and skeletal muscle. Abdominal CT was taken two months after admission. The tumor in the left

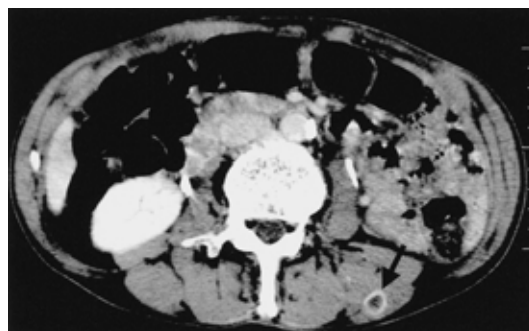

Fig. 1 Abdominal CT taken on admission showed a ring enhanced soft-tissue mass (1.5 cm in diameter) in the left lumbar muscle (arrow head)

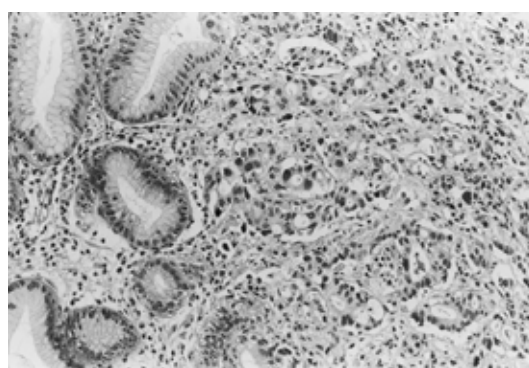


Fig. 2 A biopsy specimen from the stomach showed poorly differentiated adenocarcinoma (HE stain, $\times 150$)

lumbar muscle had grown in diameter from 1.5 cm to 2.5 cm and there were also some new lesions in the left iliopsoas muscles. The patient became increasingly cachectic and died with generalized metastasis 71 days after admission.

Discussion

Although it is generally recognized that tumors may disseminate via the blood-stream to produce distant metastases, the factors which determine the ultimate localization of metastatic lesions are not well established. Hematogenous metastases to the skeletal muscles are uncommon. Herring et al⁷ observed only 15 patients with metastasis to muscle during a 16-year period in which more than 54,000 new carcinomas were diagnosed. Sudo et al⁴ experienced four such cases during a 15-year period in which 147 patients

with primary soft-tissue sarcoma were treated. Autopsy series report a higher incidence of metastases to muscle. Wills⁸ found four cases (0.8%) of skeletal muscle metastases in his autopsy study of 500 cases of patients with malignancy. Pearson⁹ reported skeletal muscle metastases in six (15.8%) of 38 cases. These observations suggest that the phenomenon is uncommon but that it occurs as a late event in the progression of disease. Therefore it may be that only a fraction of patients with metastases to muscle survive long enough for clinical detection.

Although uncommon, many different types of cancer have been reported to metastasize to skeletal muscle. In a review of the literature by Herring et al⁷, tumor sites were found to be the lung in 18 of 52 patients (35%), gastrointestinal in 12 of 52 patients (23%): and the kidney in 10 of 52 patients (19%). Other primary sites included the skin, larynx, hypopharynx, tongue, cervix, breast, prostate, ovary, pancreas, bladder, and liver. As far as we are aware, there have been seven antemortem cases of gastric carcinoma with metastases to muscle, including the present case (**Table 1**).

Because skeletal muscle is vascular and comprises more than 50% of the body mass it is difficult to explain the rarity of haematogenous metastases to muscle. The reason for the rarity of metastatic tumors in skeletal muscle is unclear, but could be related to factors such as the prevention of settlement of tumor cells by changes in the blood flow, the mechanical destruction of tumor cells by muscle movements, and the inhibition of tumor cell proliferation by lactic acid, protease, and PH in the muscle.

The organs with a high incidence of metastases (the lungs, liver, and bones) are rich in capillary vas-

culature, and have relatively constant blood flow. In contrast, although skeletal muscles have a rich vasculature the flow is extremely variable. During exercise the capillaries dilate and the amount of blood they contain may be increased up to 800 times over that in resting state¹⁰. Blood turbulence and muscular contractions may dislodge the circulating tumor cells¹¹.

The acidic conditions within the muscle produced by various metabolites may be unfavorable to the growth of tumor cells. Some have suggested that lactic acid production by skeletal muscle inhibits the growth of tumor cells^{11,12}. Namba et al¹³ found inhibition of survival and colony formation of tumor cells in culture by saline extract of muscle. They suggest that tumor-inhibiting factor exists in muscle fibers. Connective tissues have been shown to possess diffusible proteases^{14,15} and other inhibitors¹⁶, which may block either enzyme-dependent processes of invasion or tumor development.

The differentiation between a primary soft-tissue sarcoma and metastatic carcinoma to muscle is important because the treatment and prognosis are markedly different. Shulz et al.¹⁷ reported CT findings of 12 cases of intramuscular metastasis in patients with a diagnosed primary tumor. They found that intramuscular metastatic tumors were visualized as well defined or poorly defined low-density lesions, the latter often representing necrosis. These appearances are non-specific, and similar appearances may be seen in primary malignant soft-tissue neoplasms. Herring et al⁷ also revealed that they were unable to find any clinical or radiographic characteristics that distinguish metastatic carcinoma to muscle from soft tissue sarcomas from their study and a review of 52 cases reported in the literature. Most authors think that MR

Table 1 Reported cases with gastric carcinoma developing metastasis in skeletal muscle

Author	Year	Age/sex	Pathology	Number of lesions
Rosenbaum LH ¹	1984	54/M	Mucin-producing adeno	Multiple
Porile JL ²	1990	65/M	Poorly differentiated adeno	Multiple
Van Gelderen WFC ³	1993	47/M	Poorly differentiated adeno	Multiple
Sudo A ⁴	1993	61/M	Not described	Solitary
Amano Y ⁵	1996	57/M	Not described	Multiple
Pestalozzi BC ⁶	1998	72/M	Poorly differentiated adeno	Solitary
Present case	2000	70/M	Poorly differentiated adeno	Multiple

adeno : adenocarcinoma

imaging is superior to CT scanning in its ability to detect muscle abnormalities. Metastatic lesions are usually of low signal intensity on T 1 weighted images and high signal intensity on T 2 weighted images, findings that are also observed in primary soft tissue sarcomas⁷. Amano et al⁵ revealed that MR images were useful for separation of the involved from the uninvolved muscles and were accurate in evaluating the adjacent bony and vascular structures without invasion.

We report a rare case of an elderly patient with gastric carcinoma developing multiple metastases in skeletal muscle. Better understanding of the mechanisms resulting in the relative resistance of skeletal muscle to metastases could have a bearing on therapeutic interventions for the prevention of metastases. Accumulation of data from more cases of carcinoma with metastases to muscles is needed.

References

1. Rosenbaum LH, Nicholas J, Simonslasky B, Obley D, Ellis LD: Malignant myositis ossificans: Occult gastric carcinoma presenting as an acute rheumatic disorder. *Ann Rheum Dis* 1984; 43: 95-97.
2. Porile JL, Olopade OI, Hoffman PC: Gastric adenocarcinoma presenting with soft tissue masses. *Am J Gastro* 1990; 85: 76-77.
3. Van Gelderen WFC: Gastric carcinoma metastases to extraocular muscles. *J Comput Assist Tomogr* 1993; 17: 499-500.
4. Sudo A, Ogihara Y, Shiokawa Y, Fujinami S, Sekiguchi S: Intramuscular metastasis of carcinoma. *Clin Orthop* 1993; 296: 213-217.
5. Amano Y, Kumazaki T: Gastric carcinoma metastasis to calf muscles: MR findings. *Radiat Med* 1996; 14: 35-36.
6. Pestalozzi BC, von Hochstetter AR: Muskelmetastase als erstmanifestation eines adenokarzinoms des magens. *Schweiz Med Wochenschr* 1998; 128: 1414-1417.
7. Herring CL Jr., Harrelson JM, Scully SP: Metastatic carcinoma to skeletal muscle: A report of 15 patients. *Clin Orthop* 1998; 355: 272-281.
8. Willis RA: Secondary tumors in sundry unusual situations. "In The spread of tumors in the human body" Willis RA ed. 1973; pp 281-282, Butterworths, London.
9. Pearson GM: Incidence and type of pathologic alternations observed in muscle in a routine autopsy survey. *Neurology* 1959; 9: 757-766.
10. Sinclair DC: Muscles and fasciae. "In Cunningham's Textbook of Anatomy." Romanes CF ed. 1981; pp265-409, Oxford University Press, New York.
11. Mulsow FW: Metastatic carcinoma of skeletal muscles. *Arch Pathol* 1943; 35: 112-114.
12. Seely S: Possible reasons for the high resistance of muscle to cancer. *Med Hypotheses* 1980; 6: 133-137.
13. Namba T, Hayashi K, Ueoka H, Grob D: Factors for low incidence of metastasis to skeletal muscle. *Fed Proc* 1986; 45: 947.
14. Eisenstein R, Kuettner KE, Neapolitan C, Soble LW, Sorgente N: The resistance of certain tissues to invasion. *Am J Pathol* 1975; 81: 337-348.
15. Sorgente N, Kuettner KE, Soble LW, Eisenstein R: The resistance of certain tissues to invasion. II. Evidence for extractable factors in cartilage which inhibit invasion by vascularized mesenchyme. *Lab Invest* 1975; 32: 217-222.
16. Brem H, Folkman J: Inhibition of tumor angiogenesis mediated by cartilage. *J Exp Med* 1975; 141: 427-439.
17. Schulz SR, Bree RL, Schwab RE, Raiss G: CT detection of skeletal muscle metastases. *J Comput Assist Tomogr* 1986; 10: 81-83.

(Received, Decemver 8, 2000)
(Accepted, January 15, 2001)