

—Report on Experiments and Clinical Cases—

Burns Caused by Dilute Hydrofluoric Acid in the Bleach

Kazuhisa Fujimoto¹, Naoaki Yasuhara¹, Harumichi Kawarada¹,
Sachiko Kosaka² and Seiji Kawana²

¹Department of Dermatology, Nippon Medical School Tama Nagayama Hospital

²Department of Dermatology, Nippon Medical School

Abstract

Two male cleaning workers aged 62 (patient 1) and 28 (patient 2) presented with red, swollen, aching hands and fingers. At the first interview, the fingers of the right hand of both patients were swollen from the proximal interphalangeal joint to the tip of the finger. The fingers were red and intensely painful. The bleach that both patients used contained 9.5% hydrofluoric acid, and therefore we diagnosed their symptoms as those of burns caused by this agent. We subcutaneously injected 8.5% calcium gluconate into the affected fingers and dressed them with gauze soaked in cooled 0.025% benzethonium chloride.

The patients did not use gloves at work, neither of them knew that the cleaning fluid contained dilute hydrofluoric acid, and they were unaware of the danger of this agent. They had not received proper education about the care and handling of poisons and deleterious substances such as hydrofluoric acid.

The doctors who had examined the patients in the emergency ward overlooked the possibility of hydrofluoric acid burns, although they suspected chemical burns and confirmed the trade name of the cleaning agent. In addition, although the patients presented with intense pain, no white areas of coagulation and blistering, or surrounding erythemas, which are characteristic symptoms of such burns, were evident.

The component of the cleaning agent was described on the container label in very small print. Had the words "poison" and "hydrogen fluoride" been printed in large characters, the examining doctors in the emergency ward would probably not have overlooked the presence of hydrofluoric acid, and the patients would perhaps have been more careful when using it.

Hydrofluoric acid can be easily obtained by anyone through the Internet, although general consumers could not obtain industrial quantities. Therefore, the number of burn patients who are not familiar with hydrofluoric acid may increase in the future.

(J Nippon Med Sch 2002; 69: 180–184)

Key words: hydrofluoric acid, burn, dilute, bleach

Introduction

Hydrofluoric acid is widely used for industrial,

research and domestic purposes¹⁻³. The fingers are the most frequent sites of hydrofluoric acid burns, and are simple to diagnose since patients may often be aware of the danger of this chemical². Neither of

Correspondence to Kazuhisa Fujimoto, MD, PhD, Department of Dermatology, Tama Nagayama Hospital, Nippon Medical School, 1-7-1 Nagayama, Tama-shi, Tokyo 206-8512, Japan
E-mail: funfun/derma@nms.ac.jp
Journal Website (<http://www.nms.ac.jp/jnms/>)

the two patients presented here knew that the cleaning agent they used contained dilute hydrofluoric acid. Furthermore, their condition was difficult to diagnose, since the clinical manifestations differed from burns caused by higher concentrations of hydrofluoric acid.

Case Report

A 62-year-old male cleaning worker developed an aching pain from the index finger of his right hand to the little finger after several hours of floor cleaning on August 17th, 1999. He visited the emergency and critical care medicine departments at our hospital, and an analgesic drug was prescribed. However, the pain did not improve, so he visited our clinic on the following day. At the first interview, his right index, middle, third and little fingers had swollen from the proximal interphalangeal joint to the tip, and all four fingers and the palm were red with scale and crust. The nails had turned brown, and he complained of intense pain (**Fig. 1**). As we suspected hydrofluoric acid burns, we asked to see the cleaning

agent that he used (**Fig. 2**). The label on the container noted in small print that the solution comprised 9.5% hydrofluoric acid, which confirmed our diagnosis. We administered a subcutaneous injection of 8.5% calcium gluconate and dressed the fingers with gauze soaked in cooled 0.025% benzethonium chloride. This strategy relieved the pain, and on the following day we applied clobetasol propionate to the fingers. Although bone destruction did not arise, the nails of the right middle and third fingers detached two weeks later. The patient recovered completely after three weeks.

Patient 2 was a 28-year-old male cleaner working at a building site where wooden housing was under construction. On October 29th, 1999, swelling and aches developed in his right hand and fingers after several hours of bleaching wood. His hands were washed with large volumes of cooled tap water. He visited the emergency department of surgery at our hospital, and antibiotics and analgesic drugs were prescribed. However, he visited our clinic on the following day since the aching was exacerbated. At the first interview, his right index, middle, third and little fingers were swollen from the proximal

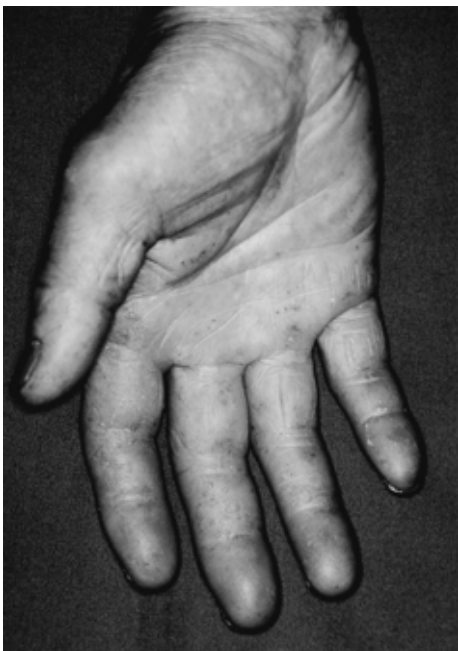

Fig. 1 First interview of patient 1
Right index, middle, third and little fingers are swollen from proximal interphalangeal joints to fingertips. All four fingers and palm were red with scale and crust.




Fig. 2 Label of the bleach used by both patients
The words "hydrofluoric acid 9.5%" are printed in very small characters.

interphalangeal joint to the tip of each finger, and erythema, epidermolysis and small scales were accompanied by a throbbing, intense pain (**Fig. 3**). We suspected hydrofluoric acid burns. The bleach he used at work was the same as that used by patient 1 (**Fig. 2**). Therefore, we confirmed our initial diagnosis and applied treatment similar to that received by patient 1. The pain was relieved after the second visit, so we applied clobetasol propionate. Bone destruction was absent, nail plate peeling and pigmentation receded, and the symptoms in the right middle and third fingers were resolved after one month.

Discussion

Hydrofluoric acid is extensively used to etch semiconductor devices, in cleaning and etching glass, cleaning bricks and aluminum, tanning leather and in petrochemical manufacturing¹⁻³. The sites of occupational trauma associated with this agent are usually the fingers. Patients understand the danger of hydrofluoric acid well, and most affected patients inform us that they use this agent. Therefore, diag-

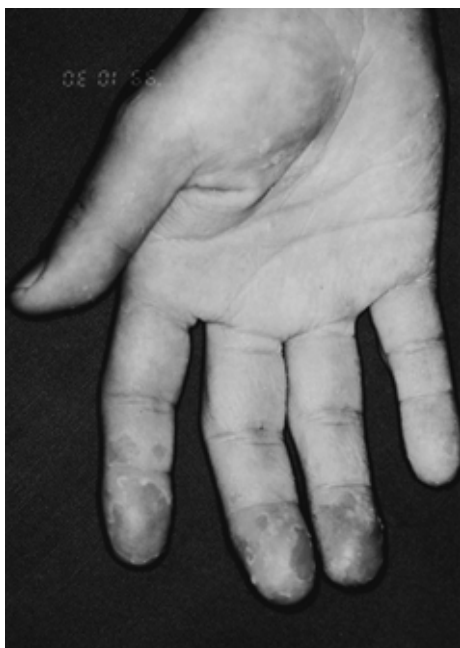

Fig. 3 First interview of patient 2
Right index, middle, third and little fingers are swollen from proximal interphalangeal joints to fingertips. Erythema, epidermolysis and small scales are evident.

nosis is comparatively easy, and quick and appropriate treatment can be applied. However, our patients did not wear gloves while performing their cleaning tasks. They did not know that hydrofluoric acid was included in the cleaning agent, and did not understand the nature of hydrofluoric acid. The doctors who had examined them in the emergency ward overlooked the possibility of hydrofluoric acid burns, although chemicals were the suspected agents and the trade name of the cleaning agents was confirmed. In addition, although they presented with intensely swollen, painful fingers, white areas of coagulation and blistering, and surrounding erythemas, which are characteristic symptoms of hydrofluoric acid burns, were absent. We had experienced a patient with burns caused by hydrofluoric acid as weapon in 1997⁴, which caused us to consider this agent as the cause of the symptoms in the present cases. We confirmed that "hydrofluoric acid 9.5%" was printed on the label of the bleach they used.

Hydrofluoric acid is weak, but when it comes into contact with proteins, discharged fluoride ions adhere to the skin, and calcium and insoluble salts form under the tissues^{2,3,5}. Since tissue destruction continues until all fluoride ions become insoluble salts, deep ulceration can arise that reaches the bone. By reacting with proteins in the skin, hydrofluoric acid produces white areas of coagulation and blistering. In addition, intense pain is caused by calcium ions discharged from the tissue causing membrane potential changes^{2,3,6,7}. Hypocalcemia can develop when the injured area is wide, and cardiac arrest can also occur⁸⁻¹⁰. Burns due to higher concentrations of hydrofluoric acid cause intense pain immediately after the injury. In addition, erythema is rapidly produced, and tissue destruction in white areas of coagulation and blistering, punching ulcers and necrosis quickly proceed. However, dilute concentrations of hydrofluoric acid take time to reach a crisis and white areas of coagulation and blistering do not always occur^{8,10-12}.

Primary care is very important for patients burned by hydrofluoric acid. We have developed a treatment plan as shown in **Table 1**⁸. By combining with free fluoride ions, calcium gluconate halts tissue destruction^{8,13}. However, calcium gluconate is difficult

Table 1 Treatment of hydrofluoric acid burns

-
1. Carry out copious washing with large volumes of cooled tap water and an alkali soap as first aid at the time of injury.
 2. Immediately dress the injury with gauze dressing soaked in cooled benzethonium chloride.
 3. If the concentration of the hydrofluoric acid is higher, or the burns appear to be deep, or if intense pain is evident, inject the painful area with 8.5% calcium gluconate (0.5 ml/cm²).
 4. Carefully debride area of severe burns.
 5. If pain recurs, administer additional calcium gluconate injections.
 6. Institute reconstructive procedures if appropriate.
-

to inject intradermally due to pain. A counterincision may be required into the fingertip to circumvent a circulatory disturbance. Intra-arterial infusions of calcium gluconate are also effective against burns caused by higher concentrations of hydrofluoric acid or when tissue destruction is severe^{1-3,5,14-16}. On the other hand, the application of a 2.5% calcium gluconate gel is recommended to treat burns caused by dilute hydrofluoric acid^{2,17-19}. However, we must be compounded calcium gluconate gel at hospital, since it is not yet available commercially in Japan. General hospitals that are not located near chemical plants probably do not maintain stocks of calcium gluconate gel. Benzethonium chloride or benzalkonium chloride is often used with calcium gluconate to replace fluoride with chloride ions and to deionize remaining fluoride^{8,12,20}.

Though the poison and deleterious substance regulatory laws regulate the use of hydrofluoric acid, it is in fact frequently used by laypersons. Our patients did not receive proper education about the care and handling of poisons and deleterious substances such as hydrofluoric acid. Furthermore, the component of the cleaning agent was described on the label of the container in very small print. Had the words "poison" and "hydrogen fluoride" been printed in large characters, the examining doctors in the emergency ward would probably not have overlooked the presence of hydrofluoric acid, and the patients would perhaps have been more careful when using it. Hydrofluoric acid can be easily obtained by anyone through the Internet, although general consumers could not obtain industrial quantities. Therefore, the number of burn patients who are not familiar with hydrofluoric acid may increase in the future. We consider it important to warn not only

dermatologists but also emergency doctors who may encounter patients with hydrofluoric acid burns so that they can be treated in an appropriate and timely fashion.

Acknowledgments: We are grateful to Dr. Miyako Yamamoto of the Division of Chem. -Bio Informatics, National Institute of Health Science for providing information about hydrofluoric acid burns.

References

1. Pegg SP, Siu S, Gillet G: Intra-arterial infusions in the treatment of hydrofluoric acid burns. *Burns* 1985; 11: 440-443.
2. Caravati EM: Acute hydrofluoric acid exposure. *Am J Emerg Med* 1988; 6: 143-150.
3. Upfal M, Doyle C: Medical management of hydrofluoric acid exposure. *J Occup Med*, 1990; 32: 726-731.
4. Kurihara K, Fujimoto K, Kawana S: A case of hydrofluoric acid burn. *Jpn J Clin Dermatol* 2001; 55: 929-931.
5. Mistry DG, Wainwright DJ: Hydrofluoric acid burns. *Am Fam Physician* 1992; 45: 1748-1754.
6. Bracken WM, Cuppage F, McLaury RL, Kirwin C, Klaassen CD: Comparative effectiveness of topical treatments for hydrofluoric acid burns. *J Occup Med* 1985; 27: 733-739.
7. Klauder JV, Shelanski L, Gabriel K: Industrial uses of compounds of fluoride and oxalic acid. *Arch Indust Health* 1955; 12: 412-419.
8. Dibbell DG, Iverson RE, Jones W, Laub DR, Madison MS: Hydrofluoric acid burns of the hand. *J Bone & Joint Surg* 1970; 52-A 5: 931-936.
9. Mayer TG, Gross PL: Fatal systemic fluorosis due to hydrofluoric acid burns. *Ann Emerg Med* 1985; 14: 149-153.
10. Tepperman PB: Fatality due to acute systemic fluoride poisoning following a hydrofluoric acid skin burn. *J Occup Med* 1980; 22: 691-692.
11. MacKinnon MA: Hydrofluoric acid burns. *Dermatol Clin* 1988; 6: 67-74.
12. Reinhardt CF, Hume WG, Lanch AL, Wetherhold JM: Hydrofluoric acid burn treatment. *Am Indust*

- Hygiene Assoc J 1966; 27: 166-171.
13. Carney SA, Hall M, Lawrence JC, Ricketts CR: Rationale of the treatment of hydrofluoric acid burns. *Br J Ind Med* 1974; 31: 317-321.
 14. Köhnlein HE, Achinger R: A new method of treatment of the hydrofluoric acid burns of the extremities. *Chir Plastica* 1982; 6: 297-305.
 15. Vance MV, Curry SC, Kunkel DB, Ryan PJ, Ruggeri SB: Digital hydrofluoric acid burns: Treatment with intraarterial calcium infusion. *Ann Emerg Med* 1986; 15: 890-896.
 16. Velvart J: Arterial perfusion for hydrofluoric acid burns. *Hum Toxicol* 1983; 2: 233-238.
 17. Anderson WJ, Anderson JR: Hydrofluoric acid burns of the hand: Mechanism of injury and treatment. *J Hand Surg* 1988; 13-A: 52-57.
 18. Browne TD: The treatment of hydrofluoric acid burns. *J Soc Occup Med* 1974; 24: 80-89.
 19. EL Saadi MS, Hall AH, Hall PK, Riggs BS, Augenstein WL, Rumack BH: Hydrofluoric acid dermatitis exposure. *Vet Human Toxicol* 1989; 31: 243-247.
 20. Johnstone RT, Miller SE: *Occupational Diseases and Industrial Medicine* 1960; pp 130-133, WB Saunders Company, Philadelphia.

(Received, November 8, 2001)

(Accepted, November 21, 2001)
