

## —Report on Experiments and Clinical Cases—

## A Dislocation of the Inner Head in Bipolar Prosthesis with a Self-centering System: A Case Report

Kouichi Tanaka<sup>1</sup>, Yoshihito Nakayama<sup>1</sup>, Ryoichi Murashige<sup>1</sup>, Hiromoto Ito<sup>2</sup>,  
Kiyoshi Yoshihara<sup>2</sup>, Kingo Obama<sup>3</sup> and Takeshi Nakase<sup>3</sup>

<sup>1</sup>Department of Orthopaedic Surgery, Daini Hospital, Nippon Medical School

<sup>2</sup>Department of Orthopaedic Surgery, Nippon Medical School

<sup>3</sup>Department of Orthopaedic Surgery, Kureha General Hospital

### Abstract

We present a case of inner head dislocation 11 years after the replacement of a bipolar prosthesis with a self-centering system. An 84-year-old woman with osteoarthritis of the left hip underwent a replacement of the Bateman UPF-II bipolar prosthesis in 1987. She fell off a chair on April 19 1998, and felt a sudden sharp pain in the left hip. Roentgenograms revealed that the inner head was dislocated from the outer head. Moreover, on June 19, when she stood up from the floor, the dislocation recurred. On July 23, a revision surgery was carried out. When the outer head was removed from the acetabulum, the bearing insert was markedly worn by the impingement of the femoral stem neck. Because there was no evidence of loosening of the femoral stem, a cemented replacement of the acetabular component was performed. At a 2-year follow-up, she had mild hip pain, but had returned fully to daily living. Our review of current published studies reveals that most inner head dislocations occurred in osteoarthritic patients. Thus, the occurrence of dislocations may be more dependent on patient selection than on failure of the bipolar prosthesis itself. (J Nippon Med Sch 2002; 69: 192–195)

**Key words:** bipolar prosthesis, self-centering system, impingement, osteoarthritis

### Introduction

In 1978, Bateman<sup>1</sup> reported the first clinical application of bipolar hip prosthesis (Bateman UPF-I) as an alternative to conventional unipolar prosthesis. Subsequently, the Bateman and other first-generation bipolar prostheses have been widely used for the treatment of femoral neck fractures as well as of various joint diseases. However, in long-term follow-up of these prostheses<sup>2–4</sup>, inner head dislocation has been reported as a rare complication. In order to prevent the dislocation, a second-generation bipolar

prosthesis with a self-centering system has been developed. With this modification, the occurrence of dislocations has been decreased. However, recent studies demonstrate that it remains as an unresolved complication<sup>5–7</sup>. We present an inner head dislocation 11 years after the replacement of a bipolar prosthesis with a self-centering system.

### Case

An 84-year-old woman with osteoarthritis of the left hip underwent replacement of a Bateman UPF-II bipolar prosthesis in 1987. Subsequently, she

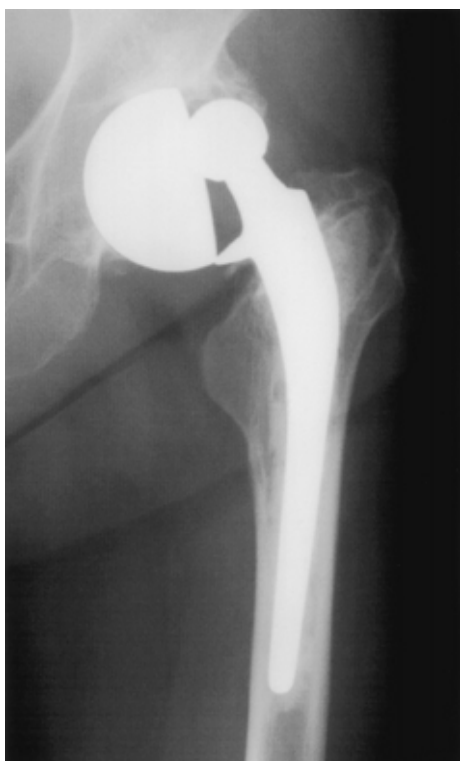---

Correspondence to Kouichi Tanaka, Department of Orthopaedic Surgery, Daini Hospital, Nippon Medical School, 1–396 Kosugi-cho, Nakahara-ku, Kawasaki, Kanagawa 211–8533, Japan  
Journal Website (<http://www.nms.ac.jp/jnms/>)

was doing well with a relief of pain. However, on April 19, 1998, when she fell off a chair, she felt a sudden sharp pain in the left hip and visited our hospital. On physical examination, the left hip was fixed due to pain in a flexion of  $20^{\circ}$  and adduction of  $10^{\circ}$ . Roentgenograms revealed that the outer head was locked in the varus position within the acetabulum, and the inner head was dislocated from the outer head (**Fig. 1**).


After closed reduction under image intensification, she had an immobilization of the hip for 3 weeks. However, on June 19, when she stood up from the floor, the dislocation recurred. She underwent 3-week traction therapy for the left lower limb. However, roentgenograms showed signs of recurrent dislocation and that the outer head remained fixed in the varus position.

On July 23, revision surgery was carried out. When the outer head was removed from the acetabulum, there was a loss of the acetabular cartilage with a proliferation of granular tissues.

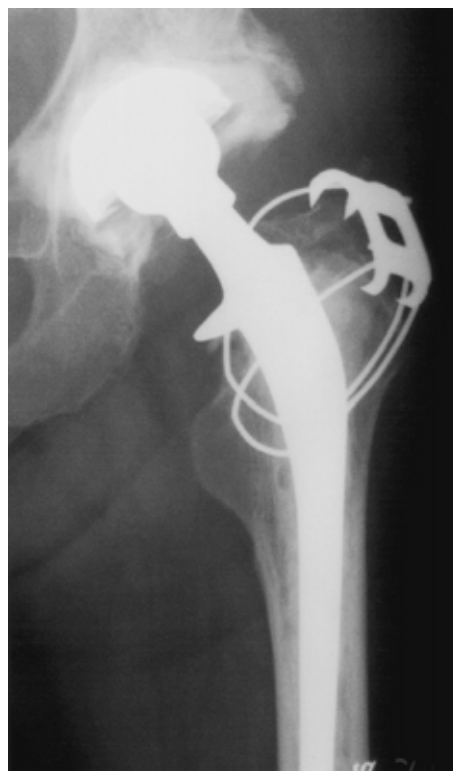

**Fig. 1** X-ray findings of the left hip at the time of first visit of our hospital:  
X-ray examination revealed that the outer head was fixed in varus position, and the inner head dislocated from the outer head.

The bearing insert was markedly worn in its inferior margin (**Fig. 2**). Because there was no evidence of loosening of the femoral stem, a cemented replacement of the acetabular component was performed. At a 2-year follow-up, the acetabular component was placed



**Fig. 2** Macroscopic findings of the outer head removed  
A marked wear of the bearing insert was observed in its inferior margin.



**Fig. 3** X-ray findings of the left hip at a 2-year follow-up  
The acetabular component was placed at the desired  $45 \pm 5$  degree in relation to the log axis of the body, and no radiolucent zone around femoral and acetabular components was observed.

Table 1 Reported cases with a dislocation of the inner head in bipolar prosthesis with the self-centering system

	Age at the time of replacement (year)	Time from replacement to dislocation (year)	Disease
Kasahara	54	5	OA
Suga	59	5	OA
Muramatsu	unknown	3	OA
Morishita	62	10	AN
Morita	64	9	OA
Aramaki	51	10	OA
Tamura	70	6	OA

OA: osteoarthritis, AN: avascular necrosis of the femoral head

at the desired  $45 \pm 5$  degree in relation to the log axis of the body and no radiolucent zone was observed around the femoral or acetabular components (**Fig. 3**). She had a mild hip pain, but returned fully to daily living.

### Discussion

Theoretically, the design of the bipolar prosthesis is aimed at reducing friction and impact forces on the acetabular cartilage by allowing motion both at the outer head-the acetabulum interface and at the inner head-bearing insert interface. However, Phillips et al<sup>8</sup> and Eiskjaer et al.<sup>9</sup> stated in fluoroscopic studies of bipolar prosthesis motion that the Bateman UPF-I bipolar prosthesis functions as a unipolar prosthesis moving at the outer head—the acetabulum interface. They also found that, in arthritic patients, some of the outer heads tended to be fixed in extremely varus position when the hip was abducted. In this context, the Bateman UPF-I bipolar prosthesis underwent some important modifications. In the new Bateman UPF-II prosthesis, the center of the inner head was located 2 mm proximally to the center of the outer head. With polar offset, a self-centering torque is created, which prevents the outer head from setting extreme varus (a self-centering system).

However, recent studies have described how inner head dislocation remains as an unresolved complication in a second-generation bipolar prosthesis with the self-centering system. To our knowledge, 7 cases with inner head dislocation have been previously

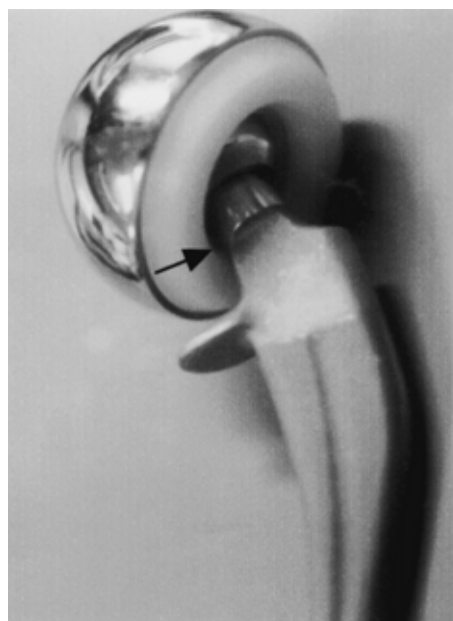


Fig. 4 The mechanism of wear of the bearing insert

If the outer head is fixed in varus position, a wear of the bearing insert in inferior margin may be caused by the impingement of femoral stem neck.

reported in Japan<sup>5-7,10-13</sup> (**Table 1**). Time intervals from replacement to dislocation ranged from 3 to 10 years with a mean of 6.9 years. Surprisingly, 6 of the 7 patients had undergone a prosthetic replacement for the treatment of osteoarthritis.

The exact mechanism of failure of the self-centering system remains obscure. Aramaki et al<sup>9</sup> stated that it might involve an increase in friction at the outer head-the acetabulum interface due to a loss of the acetabular cartilage, or a limitation of the

outer head motion due to a proliferation of granular tissues and osteophyte formation around the acetabulum. In addition, Muramatu et al<sup>7</sup> speculated that, if the outer head is placed in the varus position, wearing of the bearing insert is caused by the impingement of the femoral stem neck, resulting in dislocation of the inner head. Also in our case, the inner head dislocation might have occurred through the mechanism mentioned above (**Fig. 4**). In addition, a stem inserted and fixated in the valgus position might be a cause of the impingement.

The most common indication for use of a bipolar prosthesis is displaced femoral neck fractures. Bateman added as indications for primary prosthetic replacement: avascular necrosis of the femoral head, rheumatoid arthritis and osteoarthritis. However, it is important to remember that not all prosthetic replacements are asymptomatic and that serious complications occur in some of these patients. Our review of published studies reveals that most of the inner head dislocations occurred in osteoarthritic patients. Thus, the occurrence of dislocations may be more dependent on patient selection than on failure of the bipolar prosthesis itself.

### References

1. Bateman JE: Single assembly total hip prosthesis: Preliminary report. *Orthop Digest*, 1974; 2: 15-22.
2. Barmada R, Mess D: Bateman hemiarthroplasty component disassembly. A report of three cases of high-density polyethylene failure. *Clin Orthop*, 1987; 224: 147-149.
3. Herzenberg JE, Harrelson JM, Campbell II DC, Lachiewicz PF: Fractures of the polyethylene bearing insert in Bateman bipolar hip prostheses. *Clin Orthop*, 1988; 228: 88-93.
4. Hirotsu H, Saito H, Abe J, Masaoka S: Fracture of bearing insert in Bateman bipolar hip prosthesis. *Seikeigeka*, 1991; 42: 412-413. (Japanese)
5. Morishita T, Mizuno H, Tanaka T, Yamada T, Higashikura M: Shaving down of stemneck due to outer cup impingement of bipolar endoprosthesis; A case report of two cases. *Rinsho Seikei Geka*, 1997; 32: 205-208.
6. Morita K, Yanagimoto S, Inoue K, Oyama Y: Dislocation of the inner head in Omnifit type bipolar endoprosthesis due to osteolysis; A case report. *Kanto Seikeisaigaikeka Gakkai Zasshi*, 1998; 29: 405-409. (Japanese)
7. Muramatsu T, Tachibana S, Mikami T, Kawai M, Hirota H, Nakamichi K: Dislocation of the inner head of bipolar hip prosthesis with self centering system; A case report. *Seikei Saigaikeka Zasshi*, 37:1403-1407. (Japanese)
8. Phillips TW: The Bateman bipolar femoral head replacement; A fluoroscopic study of movement over a four-year period. *J Bone Joint Surg*, 1987; 69 B: 761-764.
9. Eiskjaer S, Boll K, Gelineck J: Component motion in bipolar cemented hemiarthroplasty. *J Orthop Trauma* 1989; 3: 313-316.
10. Aramaki K, Takeshita M, Ogami T, Hirata O, Iwamoto H: Recurrent dislocation of the inner head in bipolar hip prostheses due to high density polyethylene liner failure; A case report. *Seikeigeka Saigaikeka*, 1996; 45: 4-8. (Japanese)
11. Kasahara T, Murata T, Nohira K, Harada Y, Tachida T, Moriya H: Dislocation of the inner head in bipolar hip prostheses due to the high density polyethylene liner failure. *J Joint Surg*, 1993; 12: 1079-1084. (Japanese)
12. Suga T, Tokunaga H, Okamura T, Nishimoto T, Ogawa R: Femoral head dislocation of bipolar hip prosthesis with self-centering system; report of two cases. *J Joint Surg*, 1993; 12: 1487-1490. (Japanese)
13. Tamura M, Takahashi K, Takeda M, Takahashi M, Nakamichi M: Dislocation of the inner head in bipolar hip prosthesis due to the bearing insert failure. *Kanagawa J Orthop Traumatol*, 1998; 11: 89-92. (Japanese)

(Received, September 26, 2001)

(Accepted, November 27, 2001)