

—Original—

Is Transvaginal Ultrasonography at Mid-trimester Useful for Predicting Early Spontaneous Preterm Birth?

Takehiko Fukami¹, Kaisuke Ishihara¹, Takao Sekiya² and Tsutomu Araki¹

¹Department of Obstetrics and Gynecology, Nippon Medical School

²Department of Obstetrics and Gynecology, Fujita Health University Banbuntane Houtokukai Hospital, Aichi

Abstract

Numerous reports have examined the relationship between sonographically determined cervical length and spontaneous preterm birth. Moreover, large screening studies have consistently demonstrated that the shorter the cervical length, the higher the rate of spontaneous preterm delivery. However, the sensitivity and positive predictive value of the cervical length for detecting preterm birth were low. Subsequently, we developed a new sonographic parameter termed “cervical gland area (CGA)”. The purpose of this study was to determine whether sonographic cervical findings (shortened cervical length or absence of CGA) at 16~19 weeks’ gestation could predict spontaneous preterm birth. The absence of CGA as compared to the shortened cervical length showed a higher sensitivity (75.0% vs. 50.0%) and a significantly elevated positive predictive value (54.5% vs. 8.3%) for preterm birth before 32 weeks’ gestation. It was concluded that the absence of CGA was a novel and useful sonographic parameter for predicting early spontaneous preterm birth.

(J Nippon Med Sch 2003; 70: 135–140)

Key words: cervical gland area, cervical length, preterm birth, transvaginal ultrasonography, cervical ripening

Introduction

Most preterm births (90~95%) are after 32 weeks’ gestation. The neonatal outcomes are generally good. However, since the development of neonatal intensive units, most neonatal deaths associated with prematurity occur in infants born at less than 32 weeks’ gestation and significant morbidities abate after 32 weeks’ gestation¹⁻⁴. Therefore, it is highly important for obstetricians to prevent spontaneous preterm birth before 32 weeks’ gestation. A logical strategy for the

prevention of spontaneous preterm labor begins with the identification of patients at risk, and instituting medical intervention as soon as possible.

There have been numerous studies that have examined the relationship between cervical sonography and the outcome of singleton gestations⁵⁻¹⁷. It is assumed that vaginal sonographic evaluation of the uterine cervix is useful for predicting pregnancy outcome. In addition, examination in early pregnancy becomes necessary to predict early preterm birth. In these studies the main sonographic cervical parameter used to predict the pregnancy outcome was the cervical length. The

Correspondence to Takehiko Fukami, MD, Department of Obstetrics and Gynecology, Nippon Medical School Second Hospital, 1-396 Kosugi-cho, Kawasaki-shi, Kanagawa 211-8533, Japan

E-mail: fukami@nms.ac.jp

Journal Website (<http://www.nms.ac.jp/jnms/>)

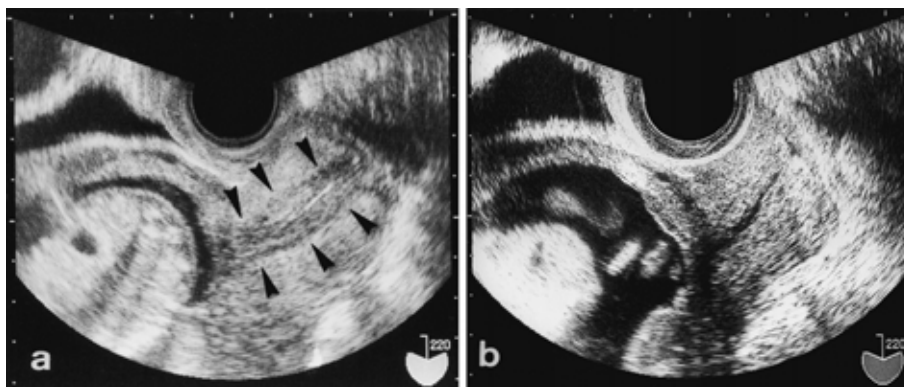


Fig. 1 “Cervical gland area (CGA)” is defined as the sonographically hypoechoic zone surrounding the cervical canal (arrow-heads), which is assumed to correspond to the histological cervical gland area; CGA present (a). The cervix appear sonographically isoechoic; CGA absent (b).

sensitivity and positive predictive value of cervical length for detecting preterm birth are relatively good in high-risk patients^{8,9,11,13,17}, but are poor in the general population^{10,12,14,15}.

In order to overcome such problems, we developed a new sonographic parameter, termed “cervical gland area (CGA)”^{18,19}. The present prospective study was performed to compare shortened cervical length and absence of CGA assessed at early mid-trimester for their ability to predict spontaneous preterm birth before 32 weeks’ gestation.

Materials and Methods

This prospective study was performed on patients who underwent ultrasonographic examination at the Department of Obstetrics and Gynecology, Nippon Medical School Second Hospital between April 1998 and September 2001. The study population consisted of patients scanned between 16 weeks’ and 19 weeks’ gestation. Women with singleton pregnancies were eligible to participate, and those with chronic medical or obstetric problems that might result in an indicated preterm birth, or uterine and fetal anomalies were ineligible. Women who received a cerclage because of a clinical history of cervical incompetence were also excluded. Informed consent was obtained before performing transvaginal sonography. Gestational age was determined from the comparing last menstrual period and sonographic

evaluation.

Vaginal sonography was performed using MOCHIDA SONOVISTA EX and ET (7.5-MHz TVprobe) models at an angle of 220° (MOCHIDA Co., Tokyo Japan) which were operated at a constant output power of -0 dB and a total gain control of 35 to -40 dB to avoid false positive or negative detection. Sonographic examinations were performed by 6 house staff doctors who were well-trained specialists. Each sonographic examination was performed according to a defined protocol: the patient was asked to empty her bladder and then was placed in a dorsal lithotomy position. The transvaginal probe was inserted and advanced along the vaginal canal until the sagittal image of the cervix could be visualized. The probe was withdrawn slowly and stopped when an adequate image was obtained. An adequate image was defined as the visualization of the internal os, external os, and endocervical canal. Cervical length was measured with electric calipers as the linear distance between the external os and the internal os along a closed endocervical canal. A shortened cervix was defined as ≤ 30 mm in length. This cut-off value had been shown to be less than the mean cervical length minus 1.5 SD between 16 weeks’ and 19 weeks’ gestation^{6,18}. CGA was defined as the sonographically hyperechoic or hypoechoic zone surrounding the cervical canal, which is assumed to correspond to the histological CGA^{16,17}. If the cervix appeared sonographically isoechoic, we defined it as

Table 1 Maternal demographic data (n = 3,030)

Mean maternal age (years) \pm SD	29.5 \pm 4.9
Parity (n(%))	
Nulliparous	1,573 (51.9)
Multiparous	1,457 (48.1)
Preterm birth (n(%))	
Total	96 (3.2)
22w0d-31w6d (Group A)	8 (0.3)
32w0d-36w6d (Group B)	88 (2.9)

SD, standard deviation.

Table 2 The efficacy of sonographic cervical parameters for predicting preterm birth before 32 weeks' gestation (group A)

	Shortened cervical length		Absence of CGA		Shortened cervical length and absence of CGA	
	n	%	n	%	n	%
Sensitivity	4/8	50.0	6/8	75.0	4/8	50.0
Specificity	2,978/3,022	98.5	3,017/3,022	99.8	3,016/3,022	99.8
PPV	4/48	8.3	6/11	54.5	4/10	40.0
NPV	2,978/2,982	99.9	3,017/3,019	99.9	3,017/3,019	99.9

PPV, positive predictive value; NPV, negative predictive value.

absence of CGA (**Fig. 1**).

The primary outcome criterion for this study was a spontaneous preterm birth. Multivariate analyses were performed to examine the relationship between ultrasonographic variables and the likelihood of preterm delivery. Preterm birth was categorized according to the gestational age at delivery (group A: 22~31 weeks' gestation and group B: 32~36 weeks' gestation). The sensitivity, specificity, positive and negative predictive values were calculated for cervical length of ≤ 30 mm and absence of CGA.

Results

A total of 3,367 women met the inclusion criteria and underwent cervical assessment at 16~19 weeks' gestation as a screening test for preterm delivery. Of the 3,367 pregnancies, 312 were lost to follow-up, 25 had iatrogenic preterm delivery and these pregnancies were excluded from further analysis. In the remaining 3,030, the mean (\pm SD) cervical length was 41.8 ± 7.2 mm, nulliparous were 1,573 (51.9%) and multiparous were 1,457 (48.1%).

The mean (\pm SD) maternal age was 29.5 ± 4.9 years (range 17~43 years). The overall rate of preterm delivery (22~36 weeks' gestation) was 3.2% (96/3,030) and that of group A (22~31 weeks' gestation) was 0.3% (8/3,030) and group B (32~36 weeks' gestation) was 2.9%. Most (91.7%: 88/96) preterm births were after 32 weeks' gestation (group B) (**Table 1**).

Tables 2 and 3 show the efficacy of sonographic cervical parameters for predicting the two stages (group A, B) of preterm birth. In group A, shortened cervical length, absence of CGA, or the combined two parameters respectively had a sensitivity of 50.0%, 75.0% or 50.0%, a positive predictive value of 8.3%, 54.5% or 40.0%, a specificity of 98.5%, 99.8% or 99.8%, and a negative predictive value of 99.9% for each. In group B, shortened cervical length, absence of CGA, or the combined two parameters respectively had a sensitivity of 18.2%, 2.3% or 2.3%, a positive predictive value of 33.3%, 18.2% or 20.0%, a specificity of 98.9%, 99.7% or 99.7%, and a negative predictive value of 97.6%, 97.2% and 97.2%. The absence of CGA showed a significantly higher

Table 3 The efficacy of sonographic cervical parameters for predicting preterm birth after 32 weeks' gestation (group B)

	Shortened cervical length		Absence of CGA		Shortened cervical length and absence of CGA	
	n	%	n	%	n	%
Sensitivity	16/88	18.2	2/88	2.3	2/88	2.3
Specificity	2,910/2,942	98.9	2,933/2,942	99.7	2,934/2,942	99.7
PPV	19/48	33.3	2/11	18.2	2/10	20.0
NPV	2,910/2,982	97.6	2,933/3,019	97.2	2,935/3,020	97.2

PPV, positive predictive value; NPV, negative predictive value.

positive predictive value for preterm birth before 32 weeks' gestation (54.5% vs. 8.3%).

Discussion

A large number of studies have evaluated the relationship between cervical sonography and the likelihood of spontaneous preterm birth of singleton gestations⁵⁻¹⁶. In several reports⁷⁻⁹, the patient populations were symptomatic women and the criterion for preterm birth analysis was after 32 weeks' gestation. In these studies, most preterm births were after 32 weeks' gestation. In fact, our study led to the same result. Thus, in several reports the likelihood of spontaneous preterm birth was more dependent on populations after 32 weeks' gestation⁵⁻¹³. To date in spite of the development of neonatal intensive units, preterm birth has been the most important cause of infant morbidity and mortality, especially at less than 32 weeks' gestation, because this group of neonates is at particular risk for short- and long-term morbidity and mortality¹⁻⁴. Therefore, the critical point of predicting preterm birth is considered to be at 32 weeks' gestation and the prediction of delivery before 32 weeks to be more clinically relevant than the traditional 37 week end point.

Sonographic measurement of cervical length provides a useful prediction of the risk of spontaneous preterm birth¹⁰⁻¹⁷. Another sonographic finding in pregnancies at risk of preterm delivery is funneling or dilatation of the internal os^{6,8,9,20} and several investigators have suggested that funneling is an early sign of cervical incompetence²¹⁻²⁴. However Owen *et al.*²⁴, indicated that funneling at

the internal os had a wide range of biological variability, which might limit the reproducibility of this finding and that the measurement of cervical length should be reproducible and clinically useful. Hassan *et al.*¹⁴, described that the difficulty in obtaining a reproducible mean had forced most investigators to use cervical length as a screening method. On the other hand, CGA has been reported as a new sonographic cervical finding^{18,19}. The absence of CGA reflects cervical maturation and could be considered as a predictor of spontaneous preterm birth in patients symptomatic for preterm labor¹⁹.

We performed this prospective study in a general population to compare shortened cervical length and absence of CGA assessed at 16~19 weeks' gestation for their ability to predict spontaneous preterm birth before 32 weeks' gestation. Our findings support previous reports that cervical length is a useful predictor of preterm birth. Absence of CGA had a higher sensitivity and positive predictive value than shortened cervical length. Among those in whom CGA was not detected at 16~19 weeks' gestation, 54.5% delivered before 32 weeks' gestation. On the other hand the sensitivity of shortened cervical length in predicting preterm birth before 32 weeks' gestation was relatively good (50%), but its positive predictive value was very low (8%). This is consistent with the findings of Heath *et al.*¹⁴. In predicting preterm birth after 32 weeks' gestation, the sensitivity and the positive predictive value of each parameter was low. All parameters had high specificity and negative predictive value. Therefore, women with detectable CGA or with normal cervical length (>30 mm) should be successful in avoiding

preterm birth. Overall, our findings strongly suggested that as a screening test of predicting preterm birth before 32 weeks' gestation, the absence of CGA was a better predictor than shortened cervical length, at least in a general population of singleton gestations. However, it is necessary to address why the absence of CGA is the most appropriate sonographic cervical parameter for the prediction of prematurity.

The human uterine cervix is composed of smooth muscle, collagen, and connective tissue or ground substance. Cervical collagen appears to be the major structural component maintaining the integrity of the cervix prior to parturition²⁶. During gestation, the cervix maintains a firm consistency, forming a long, tight sphincter to ensure the integrity of the pregnancy. But near the end of the term, the cervix normally undergoes a process called "ripening" or "maturation", which causes it to become softer, shorter, more pliable and ultimately dilated to allow the passage of the fetus²⁷. The cervical ripening process is believed to be the result of biochemical changes that cause a breakdown of the collagen and a change in the glycosaminoglycans and water content of the matrix²⁸. Ripening that occurs too early in gestation often leads to preterm birth. Therefore, a logical strategy for the prediction of spontaneous preterm birth begins with identification of early cervical ripening. Then, when a cervical ripening advances, why does CGA disappears?

Cervical mucosa is lined with tall columnar epithelium and contains many large, highly branched glands. This mucosa penetrates into the stroma, where it gives rise to glands lined by columnar cells²⁹. According to Flumann and Dickmann³⁰, these glands, which actually represent infoldings of endocervical mucosa, will present new and more pronounced invaginations in the course of pregnancy. He defined this formation as "tunnel clusters". Our definition was that CGA is the sonographical contrast between tunnel clusters of cervical mucosa and the cervical stroma¹⁸. Subsequently, we regarded the absence of CGA as the disappearance of this contrast sonographically due to an increase in water content and biochemical changes in connective tissue and breakdown of

tunnel clusters by effacement of the cervix.

In conclusion, the absence of CGA at second-trimester ultrasonography appeared to be a new and powerful predictor of spontaneous preterm birth before 32 weeks' gestation. Especially predicting early preterm birth contributes to a decrease in early spontaneous preterm delivery, therefore the development of this parameter should be considered to have highly clinical significance.

Acknowledgements: We thank Dr. M. Ghazizadeh, Associate Professor, Department of Molecular Pathology, Institute of Gerontology, Nippon Medical School, for his careful review and revision of our manuscript.

References

1. Tucker JM, Goldenberg RL, Davis RO, Cooper RL, Winker CL, Hauth JC: Etiologies of preterm birth in an indigent population: is prevention a logical expectation? *Obstet Gynecol* 1991; 77: 343-347.
2. Robertson PA, Sniderman SH, Laros RK Jr, Cowan R, Heilbron D, Goldenberg RL, Iams JD, Creasy RK: Neonatal morbidity according to gestational age and birth weight from five tertiary care centers in the United States, 1983 through 1986. *Am J Obstet Gynecol* 1992; 166: 1629-1645.
3. Seubert DE, Stetzer BP, Wolfe HM, Treadwell MC: Delivery of the marginally preterm infant: what are the minor morbidities? *Am J Obstet Gynecol* 1999; 181: 1087-1091.
4. Fujii E, Murata Y: Management of pregnancy with history of preterm delivery. *Acta Obstet Gynaecol Jpn* 2000; 52: 1281-1291.
5. Andersen HF, Nugent CE, Wanty SD, Hayashi RH: Prediction of risk for preterm delivery by ultrasonographic measurement of cervical length. *Am J Obstet Gynecol* 1990; 163: 859-867.
6. Okitsu O, Murakawa T, Nakayama T, Aono T: Early prediction of preterm delivery by transvaginal ultrasonography. *Ultrasound Obstet Gynecol* 1992; 2: 402-409.
7. Murakawa H, Utsumi T, Hasegawa I, Tanaka K, Fujimori R: Evaluation of threatened preterm delivery by transvaginal ultrasonographic measurement of cervical length. *Obstet Gynecol* 1993; 82: 829-832.
8. Gomez R, Galasso M, Romero R, Mazor M, Sorokin Y, Goncalves M: Ultrasonographic examination of the uterine cervix is better than cervical digital examination as a predictor of the likelihood of premature delivery in patients with preterm labor and intact membranes. *Am J Obstet Gynecol* 1994; 171: 956-964.
9. Rizzo G, Capponi A, Arduini D, Lorido C, Romanini C: The value of fetal fibronectin in cervical and vaginal secretions and of ultrasonographic

- examination of the uterine cervix in predicting premature delivery in patients with preterm labor and intact membranes. *Am J Obstet Gynecol* 1996; 175: 1146-1151.
10. Iams JD, Goldenberg RL, Meis PJ, Mercer BM, Moawad A, Das A, Thom E, McNellis D, Copper RL, Johnson F, Roberts JM: The length of the cervix and the risk of spontaneous preterm delivery. *N Engl J Med* 1996; 334: 567-572.
 11. Berghella V, Tolosa JE, Kuhlman K, Weiner S, Bolognese RJ, Wapner RJ: Cervical ultrasonography compared with manual examination as a predictor of preterm delivery. *Am J Obstet Gynecol* 1997; 177: 723-730.
 12. Taipale P, Hiilesmaa V: Sonographic measurement of uterine cervix at 18-22 weeks' gestation and the risk of preterm delivery. *Obstet Gynecol* 1998; 92: 902-907.
 13. Berghella V, Daly SF, Tolosa JE, DiVito MM, Chalmers R, Garg N, Bhullar A, Wapner R: Prediction of preterm delivery with transvaginal ultrasonography of the cervix in patients with high-risk pregnancies: Does cerclage prevent prematurity? *Am J Obstet Gynecol* 1999; 181: 809-815.
 14. Heath VCF, Southall TR, Souka AP, Elisseou A, Nicolaides KH: Cervical length at 23 weeks of gestation: prediction of spontaneous preterm delivery. *Ultrasound Obstet Gynecol* 1998; 12: 312-317.
 15. Hassan SS, Romero R, Berry SM, Dang K, Blackwell SC, Treadwell MC, Wolfe HM: Patients with an ultrasonographic cervical length ≤ 15 mm have nearly a 50% risk of early spontaneous preterm delivery. *Am J Obstet Gynecol* 2000; 182: 1458-1467.
 16. To MS, Skentou C, Liao AW, Cacho A, Nicolaides KH: Cervical length and funneling at 23 weeks of gestation in the prediction of spontaneous early preterm delivery. *Ultrasound Obstet Gynecol* 2001; 18: 200-203.
 17. Guzman ER, Walters C, Ananth CV, O'Reilly-Green C, Benito CW, Palermo A, Vintzileos AM: A comparison of sonographic cervical parameters in predicting spontaneous preterm birth in high-risk singleton gestations. *Ultrasound Obstet Gynecol* 2001; 18: 204-210.
 18. Sekiya T, Ishihara K, Yoshimatsu K, Fukami T, Kikuchi S, Araki T: Detection rate of the cervical gland area during pregnancy by transvaginal sonography in the assessment of cervical maturation. *Ultrasound Obstet Gynecol* 1998; 12: 328-333.
 19. Yoshimatsu K, Sekiya T, Ishihara K, Fukami T, Otabe T, Araki T: Detection of the cervical gland area in threatened preterm labor using transvaginal sonography in the assessment of cervical maturation and the outcome of pregnancy. *Gynecol Obstet Invest* 2002; 53: 149-156.
 20. Berghella V, Kuhlman K, Weiner S, Texeira L, Wapner RJ: Cervical funneling: sonographic criteria predictive of preterm delivery. *Ultrasound Obstet Gynecol* 1997; 10: 161-166.
 21. Bartolucci L, Hill WC, Katz M, Gill PJ, Kitzmiller JL: Ultrasonography in preterm labor. *Am J Obstet Gynecol* 1984; 149: 52-56.
 22. Michaels WH, Montgomery C, Karo J, Temple J, Ager J, Olson J: Ultrasound differentiation of the competent from the incompetent cervix: Prevention of preterm delivery. *Am J Obstet Gynecol* 1986; 154: 537-546.
 23. Varma TR, Patel RH, Pillai U: Ultrasound assessment of the cervix in 'at risk' patients. *Acta Obstet Gynecol Scand* 1986; 65: 147-152.
 24. Podobnik K, Bulic M, Smiljanic N, Bistricki J: Ultrasonography in the detection of cervical incompetency. *J Clin Ultrasound* 1988; 13: 383-391.
 25. Owen J, Yost N, Berghella V, Thom E, Swain M, Gary A, Miodovnik M, Langer O, Sibai B, McNellis D: Mid-trimester endovaginal sonography in women at high risk for spontaneous preterm birth. *JAMA* 2001; 286: 1340-1348.
 26. Danforth DN: The morphology of the human cervix. *Clin Obstet Gynecol* 1983; 26: 7-13.
 27. Leppert PC: Cervical softening, effacement and dilatation: A complex biochemical cascade. *Journal of Maternal and Fetal Medicine* 1992; 1: 213-223.
 28. Danforth DN, Buckingham JC, Roddick JW: Connective tissue incident to cervical effacement. *Am J Obstet Gynecol* 1960; 80: 939-945.
 29. Topkins P: Histologic appearance of endocervix during menstrual cycle. *Am J Obstet Gynecol* 1949; 58: 654-663.
 30. Fluhmann CF, Dickmann Z: The basic pattern of the glandular structures of the cervix uteri. *Obstet Gynecol* 1958; 11: 543-555.

(Received, October 18, 2002)

(Accepted, November 7, 2002)