

—Report on Experiments and Clinical Cases—

A Case of Adversive Seizures Induced by Hyperventilation

Yasuhiko Kawakami¹, Tsunenori Hirayama¹, Kiyoshi Hashimoto¹,
Kentaro Kuwabara², Takehisa Fujita¹ and Osamu Fujino²

¹Department of Pediatrics, Nippon Medical School Second Hospital

²Department of Pediatrics, Chiba-Hokuso Hospital, Nippon Medical School

Abstract

We report a case of adversive seizures featuring neck rotation and conjugate deviation induced by the hyperventilation maneuver. At the age of 6 years the patient suffered from conjugate deviation to the left. She herself felt no symptoms other than oculomotor symptoms. Hyperventilation induced an adversive seizure and ictal EEG showed sharp waves in the right frontal, central, and parietal areas. No brain image showed abnormal findings. Zonisamide completely attenuated her attacks. It is well known that hyperventilation induces absence seizures, and it has been reported that hyperventilation can induce complex partial seizures. However, no previous reports have described patients diagnosed as having adversive seizures with conjugate deviation induced by hyperventilation. We report the present case because, although its epileptogenesis is unknown, the patient is a rare case not only clinically but also electrophysiologically. (J Nippon Med Sch 2003; 70: 351–354)

Key words: adversive seizure(s), hyperventilation, conjugate deviation, neck rotation

Introduction

Adversive seizures featuring neck rotation and conjugate deviation are occasionally encountered. Adversive seizures with focal paroxysmal discharges on EEG should be classified as partial seizures¹. Though it is well known that absence seizures are induced by the hyperventilation², almost no clinical manifestations other than absence seizures are induced by the hyperventilation maneuver. We present an epileptogenetically interesting case of adversive seizures induced by hyperventilation.

Case Report

Case: T.K., a 6-year-old female.

The patient was born uneventfully at 40 weeks' gestation and weighed 2,964 gm at birth. There was no family history of epileptic or neurological disorders, and her developmental milestones were normal. At the age of 6 years she suffered from conjugate deviation to the left. This occurred suddenly, and she herself felt no symptoms other than oculomotor symptoms.

At first, the frequency of episodes was once or twice a day, but the frequency increased gradually. The attacks lasted as long as several seconds and there seemed to be no particular activities in her

Correspondence to Yasuhiko Kawakami, MD, Department of Pediatrics, Nippon Medical School Second Hospital, 1-396 Kosugi-cho, Nakahara-ku, Kawasaki, Kanagawa 211-8533, Japan

E-mail: kawakami@nms.ac.jp

Journal Website (<http://www.nms.ac.jp/jnms/>)

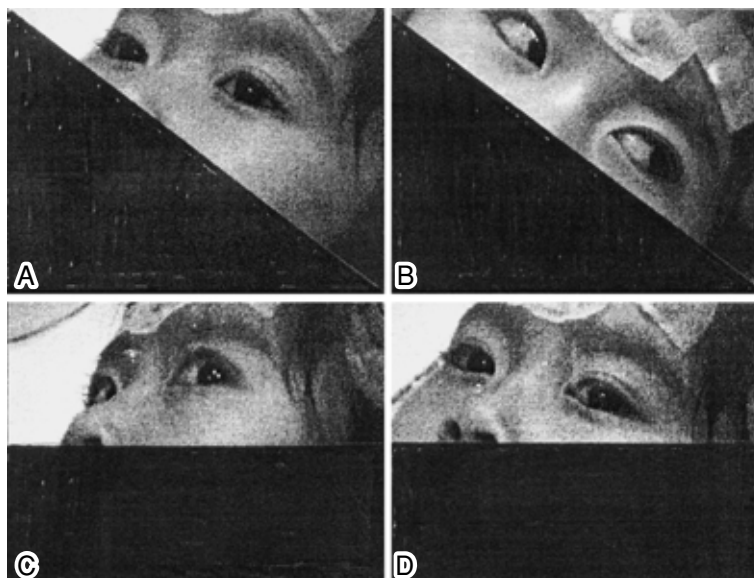


Fig. 1 During an EEG recording three minutes after the patients hyperventilated (A), she suffered from an attack. Right after the attack, she turned both her neck and eyes to the left (B). During the first moments, she did not respond to her name being called. She seemed to have a brief loss of consciousness. Several seconds later she turned her neck to the right and said, "It's happening now" with her eyes deviated (C). The attack lasted twenty seconds (D).

daily life that would induce them. She denied loss of consciousness. She herself felt her eyes' involuntary movement and could speak voluntarily during the attacks.

Examinations by an ophthalmologist and an otorhinolaryngologist revealed no significant findings. On referral to our clinic, she was normal both physically and neurologically, and no abnormalities were found in blood or urine tests. However, during hyperventilation, she suffered from an adverse seizure consisting of both conjugate deviation and neck rotation to the left and nystagmus to the right followed by a moment of disturbance to her consciousness (during the first moments of the attack she did not react to her name being called).

Both waking and sleeping EEG tests were normal, but hyperventilation induced an adverse seizure (Fig. 1) and ictal EEG showed sharp waves in the right frontal, central, and parietal areas (Fig. 2). Brain images (MRI, MR angiography, and SPECT using ^{99m}Tc -ECD) showed no abnormal findings. We diagnosed her as having partial epilepsy with adverse seizures.

She did not suffer from adverse seizures every time she hyperventilated, and some attacks happened with no apparent inducible events. Zonisamide was chosen as an antiepileptic agent, and it completely attenuated her attacks. Since her treatment was started, she has not suffered from any further attacks.

Discussion

Ocular movement is generally recognized as one of the symptoms of epileptic events of occipital origin³⁴. Previously reported cases had both focal epileptiform discharges on EEG and some organic lesions in the CNS³⁴. The present case was diagnosed as having adverse seizures with right frontal, central, and parietal spikes without intracranial lesions. She had the same clinical manifestations as previously described in an adverse seizure patient⁵.

The physiology of EEG changes induced by hyperventilation has often been reported on. Some reports have referred to the mechanism of activated slow waves caused by hyperventilation^{6,7}, and it has

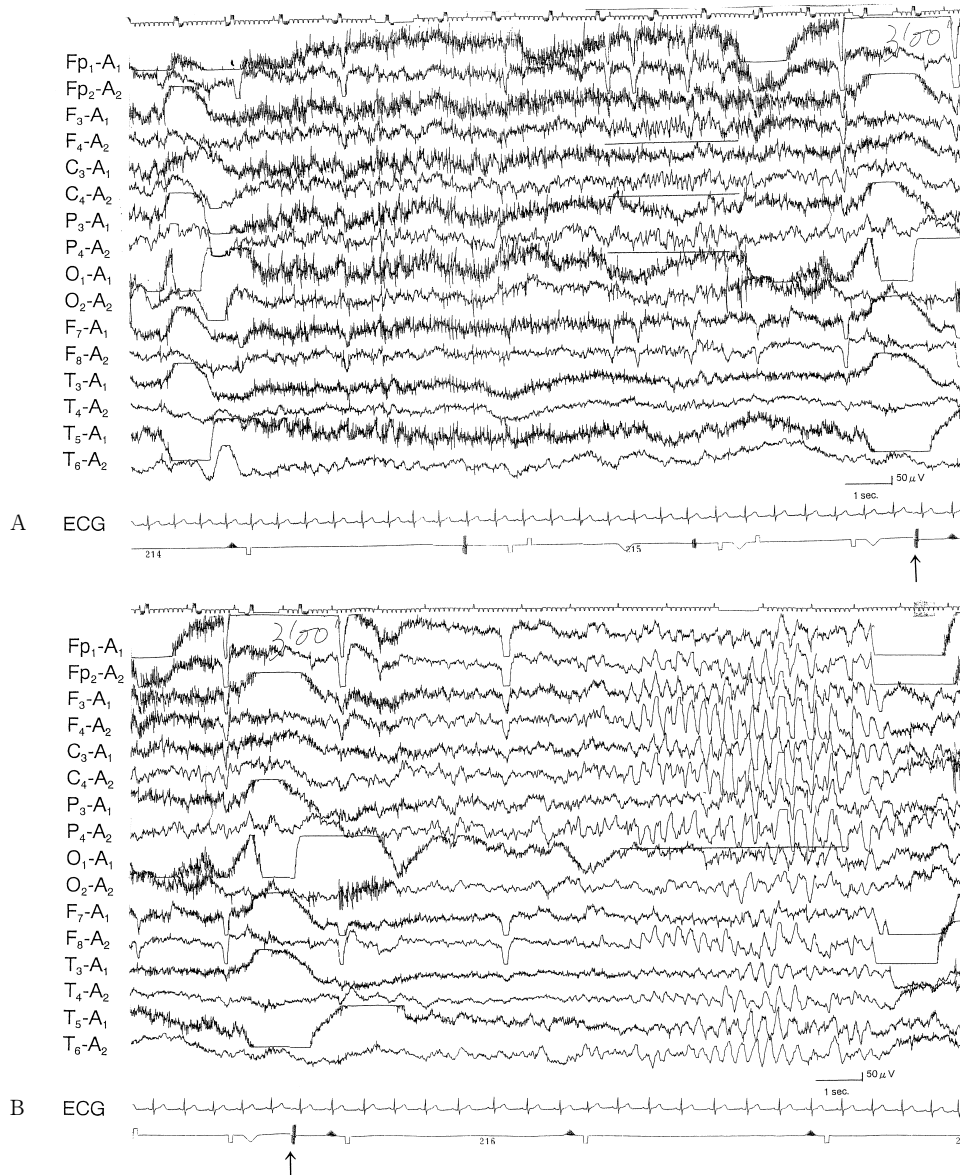


Fig. 2 Ictal EEG during hyperventilation demonstrated consecutive sharp waves following build-up discharges in the right frontal, central, and parietal areas (A) and sharp & wave complex in the right parietal area (B). The arrows indicate 3 minutes of hyperventilation.

been reported that CO₂ vasoreactivity in the temporal lobe during hyperventilation may be related to the mechanism of complex partial seizures⁸. However, the mechanism that epileptiform discharges on EEG are induced by hyperventilation still seems to be unknown.

From the clinical point of view, Aicardi reported that hyperventilation could induce brief complex partial seizures⁹. Needless to say, it is well known that absence seizures can be easily induced by hyperventilation. However, no previous reports have described patients diagnosed as having adverse

seizures with conjugate deviation induced by hyperventilation maneuver. The present case is not only clinically but also electrophysiologically suggestive of the inducement of epileptiform discharges by hyperventilation.

We report a female patient having partial epilepsy with adverse seizures. However, the pathophysiology of the conjugate deviation apparently induced by hyperventilation remains unknown. Further researches into this matter will be carried out.

References

1. The Commission on Classification and Terminology of the International League Against Epilepsy: Protocol for revised clinical and electroencephalographic classification of epileptic seizures. *Epilepsia* 1981; 22: 489-501.
2. Wolf P: Juvenile absence epilepsy. *Epileptic Syndrome in Infancy, Childhood and Adolescence*. 2 nd ed, 1992; pp 307-312, John Libbey, London.
3. Robert NNH, Eli SG: Sensations of ocular movement in seizures originating in occipital lobe. *Neurology* 1977; 27: 554-556.
4. Kivity S, Lerman P: Stormy onset with prolonged loss of consciousness in benign childhood epilepsy with occipital paroxysms. *J Neurol Neurosurg Psychiatry* 1992; 55: 45-48.
5. Thomas RB, Gregory LH: Types of seizures. *Handbook of Epilepsy*. 2 nd ed, 2000; pp 19-41, Lippincott Williams & Wilkins, Philadelphia.
6. Patel VM, Maulsby RL: How hyperventilation alters the electroencephalogram; A review of controversial view points emphasizing neurophysiological mechanisms. *J Clin Neurophysiol* 1987; 4 : 101-120.
7. Shervin I: Hyperventilation; Mode of action in electroencephalography. *Am J EEG Technology* 1984; 24: 201-211.
8. Katayama S, Momose T, Sano I, Nakashima Y, Nakajima T, Niwa S, Matsushita M: Temporal lobe CO₂ vasoreactivity in patients with complex partial seizures. *Jpn J Psychiatry Neurol* 1992; 46: 379-385.
9. Aicardi J: Epilepsies with typical absence seizures. *Epilepsy in Children* 2 nd ed, 1994; pp 94-117, Raven Press, New York.

(Received, October 15, 2002)

(Accepted, December 26, 2002)
