

—Photogravure—

Trial of Targeting Therapy Against Malignant Glioma Using Monoclonal Antibody

Hiroshi Takahashi and Akira Teramoto
Department of Neurosurgery, Nippon Medical School

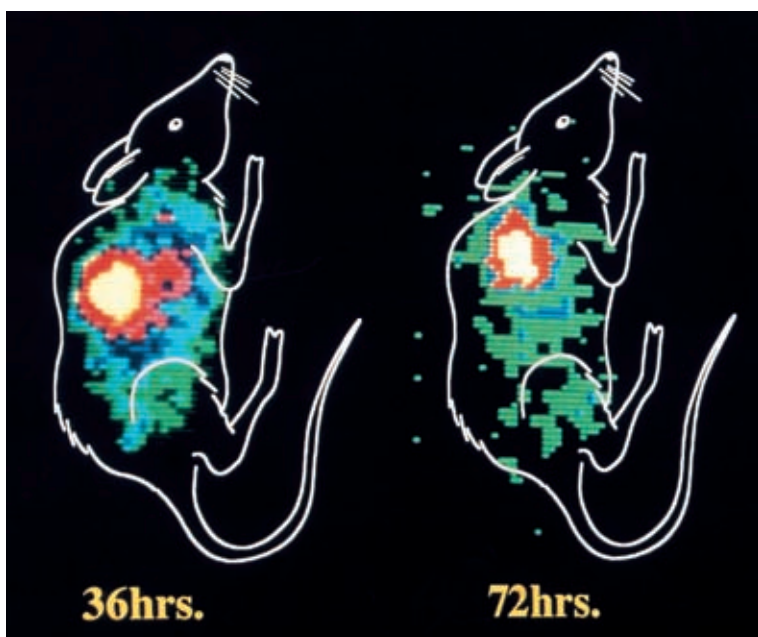


Fig. 1

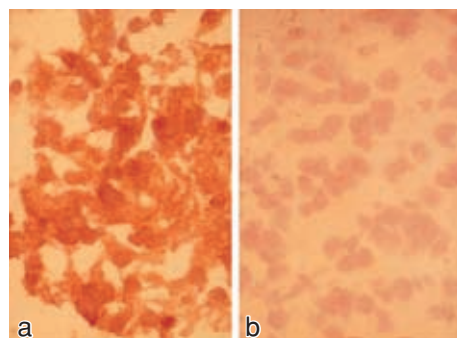


Fig. 2

Abstract

Although the conventional treatment of malignant gliomas including surgery, radiotherapy and systemic chemotherapy has advanced, their current prognosis remains poor. The reactivity of monoclonal antibodies (mAbs) with human tumor cells may allow precise localization and appropriate therapy. We have developed several mAbs against malignant gliomas, and have reported the results of the experimental studies aimed at their clinical application as targeting therapy. The initial results of employing murine mAb 425 which binds to specifically to the epidermal growth factor (EGF) receptor in glioma therapy have been excellent, but less satisfactory, possibly due to the immunogenicity of the murine mAbs, and limitations of the efficacy of the unmodified antibodies. Therefore, we also investigated the accumulation and the tumor suppression effect of human mAb CLNIgG and CLNIgG-drug (DXR: doxorubicin) conjugates to the tumor. The human mAb CLNIgG, derived from human uterine cancer lymph node cells, was found to bind strongly to human malignant glioma cells.

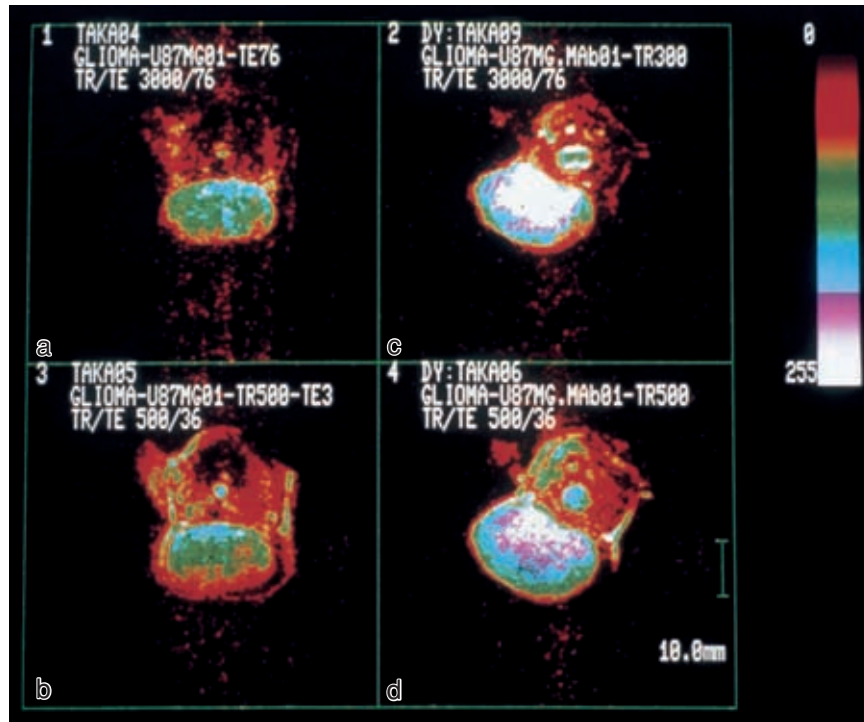


Fig. 3

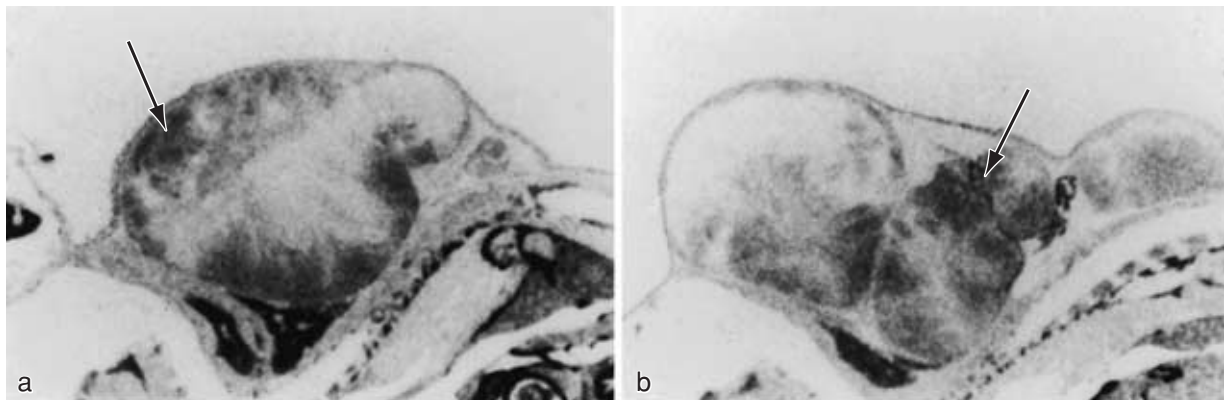


Fig. 4

Fig. 1 γ -Scintigraphy in U-87MG malignant glioma-bearing nude mice given intraperitoneal injections of 100 μ Ci of 125 I-labeled 425 F (ab')₂. Right lateral view images clearly demonstrate the tumor xenografts 36 and even 72 hours after injection of mAb 425 F (ab')₂.

Fig. 2 Immunoperoxidase staining of frozen sections of malignant glioma reacted with (a) anti-EGF receptor mAb 425, where staining of malignant cells is seen as dark areas, and (b) negative control myeloma antibody P3X63Ag8, where no staining is observed.

Fig. 3 Magnetic resonance imaging (MRI) of U-87MG malignant glioma-bearing nude mice given intraperitoneal injections of human mAb CLNIgG (c, d) or not given CLNIgG (a, b) 3 weeks before. T1 (c) and T2 (d) weighted images (WI) show the necrotic changes in the central part of the transplanted tumors with mAb as compared with T1 (a) and T2 (b) WI of the tumor without mAb.

Fig. 4 Autoradiography of subcutaneously transplanted human glioma (U-87MG) given intraperitoneal injection of [14-¹⁴C] DXR-CLNIgG or [14-¹⁴C] DXR 24 hours before. Right lateral view images of nude mice show that [14-¹⁴C] DXR-CLNIgG accumulates homogeneously in the transplanted tumor (arrow) (b), but [14-¹⁴C] DXR accumulates only in the peripheral part of the tumor (arrow) (a).