

—Original—

## Significance of Preserving the Posterior Branch of the Great Auricular Nerve in Parotidectomy

Kazuhiko Yokoshima, Munenaga Nakamizo, Chika Ozu, Akira Fukumoto,  
Shunta Inai, Shunkichi Baba and Toshiaki Yagi

Department of Otolaryngology, Nippon Medical School

### Abstract

**Objective:** Sensory disturbance due to excision of the great auricular nerve in patients who have undergone parotidectomy sometimes causes discomfort to the patients. In order to reduce the postoperative discomfort of the pinna, we tried to preserve the posterior branch of the great auricular nerve.

**Methods:** Forty patients with parotid tumor were included in this study. Twenty-one of these patients had pleomorphic adenoma, 16 had adenolymphoma and 3 had a low grade malignant tumor. Sensations of the pinna and the quality of life (QOL) after parotidectomy were evaluated using a 0–100 Visual Analogue Scale (VAS) assessed at 2 weeks, 1 month, 2 months, 3 months and 6 months after parotidectomy.

**Results:** The posterior branch of the great auricular nerve was preserved in 26 out of 40 patients (65%). No difference was observed in the incidence of complications except sensory disturbance of the pinna with this surgical procedure as compared to the surgical technique where the great auricular nerve was excised. The VAS score for the sensation was significantly higher in the group of patients whose great auricular nerve was preserved at 2 months ( $35.0 \pm 20.8$  vs.  $18.5 \pm 9.2$ ), 3 months ( $64.4 \pm 18.3$  vs.  $26.4 \pm 13.8$ ) and 6 months ( $66.9 \pm 16.2$  vs.  $26.6 \pm 11.4$ ) after parotidectomy. The VAS score for the QOL was also significantly higher in the group of patients whose great auricular nerve was preserved at 2 months ( $50.3 \pm 21.8$  vs.  $35.1 \pm 14.5$ ), 3 months ( $69.5 \pm 27.5$  vs.  $45.9 \pm 22.6$ ) as well as 6 months ( $71.9 \pm 24.1$  vs.  $45.7 \pm 19.1$ ) after parotidectomy.

**Conclusion:** Preservation of the posterior branch of the great auricular nerve during parotidectomy is valuable in order to reduce the postoperative sensory disturbance of the pinna that follows conventional surgery. It further helps to improve the QOL of these patients after parotidectomy.

(J Nippon Med Sch 2004; 71: 323–327)

**Key words:** great auricular nerve, parotid tumor, preservation, complication

### Introduction

The great auricular nerve is an important

anatomical landmark during various surgical procedures of the head and neck<sup>1</sup>. However, less attention has been paid to the original function of the nerve itself. In parotidectomy, the great

---

Correspondence to Kazuhiko Yokoshima, Department of Otolaryngology, Nippon Medical School, 1–1–5 Sendagi, Bunkyo-ku, Tokyo 113–8603, Japan

E-mail: kyok@nms.ac.jp

Journal Website (<http://www.nms.ac.jp/jnms/>)

auricular nerve is usually cut at the level of the inferior pole of the parotid gland for a wider exposure of the operative field and for avoiding the dissemination of tumor cells even if it is a benign tumor. Great attention has been paid to preserving the facial nerve, but less attention has been paid to the preservation of the great auricular nerve and the morbidity associated with its excision.

Sensory disturbance of the pinna as a result of excising the great auricular nerve often reduces the quality of life (QOL) of the patients who have undergone parotidectomy<sup>2</sup>. The unnecessary sacrifice of anatomical structures is not justified, mainly if it implies significant post-operative dysfunction. Besides the discomfort provoked by the sacrifice, post-parotidectomy hyposensitivity of the pinna has been associated with traumatic lesion, sometimes associated with difficulty in wearing earrings. Therefore, we studied the possibility and validity of preservation of the posterior branch of the great auricular nerve in parotidectomy.

### Subjects

From January 2001 to March 2003, 40 patients underwent surgery for parotid tumor without neck dissection at Nippon Medical School Chiba Hokusio Hospital. Among them, 25 were males and 15 were females. The mean and standard deviation of age of these patients were 55.3 and 12.5, ranging from 27 to 78 years. Twenty-one of these cases had pleomorphic adenoma, 16 had adenolymphoma, 2 had acinic cell carcinoma and 1 had mucoepidermoid carcinoma. In all cases, the tumors were unilateral. Thirty-seven patients underwent superficial parotidectomy whereas 3 patients underwent total parotidectomy with facial nerve preservation. No adjuvant cancer therapy was performed for 3 patients with malignant tumor. None of the patients had any sensory disturbance of the pinna preoperatively.

### Surgical Procedure

All surgeries were performed under general anesthesia. A typical S-shaped skin incision was

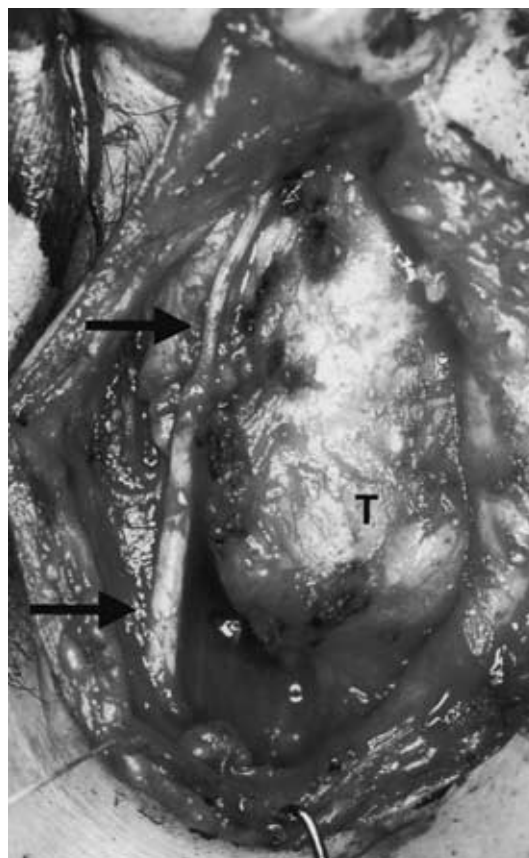


Fig. 1 Surgical procedure for preserving the posterior branch of the great auricular nerve: The great auricular nerve was identified at two points, just beneath the lobule and on the sternocleidomastoid muscle. The nerve was preserved with fine dissection.

**Arrow:** isolated posterior branch of the great auricular nerve

**T:** tumor of right parotid gland

designed. The operation was standardized and began with a vertical skin incision in front of the tragus, continuing beneath the lobule of the auricle and down to the sternocleidomastoid muscle. We identified the great auricular nerve at two points, at the point just beneath the lobule and at the point on the sternocleidomastoid muscle beside the external jugular vein. During elevation of the flap, the superficial layer of the great auricular nerve was dissected and visualized. The nerve was preserved with fine dissection around the nerve using a surgical knife. After cutting the anterior branches, the posterior branch was isolated and preserved (**Fig. 1**). When we found adhesions between the nerve and the tumor, the posterior branch was also

Table 1 The VAS score for the sensation of the pinna after parotidectomy: VAS score was significantly higher in the group of patients whose great auricular nerve was preserved at 2 months, at 3 months and 6 months after parotidectomy. GAN: the posterior branch of the great auricular nerve

	2 weeks	1 month	2 months	3 months	6 months
GAN preserved n=26	4.4 ± 6.8	16.5 ± 11.6	35.0 ± 20.8	64.4 ± 18.3	66.9 ± 16.2
GAN excised n=14	4.4 ± 5.3	10.1 ± 3.7	18.5 ± 9.2	26.4 ± 13.8	26.6 ± 11.4
p-value	0.99 n.s.	0.054 n.s.	0.008	0.001	0.001

cut and excised in order to avoid the dissemination of tumor cells. The great auricular nerve has many anatomical variations in terms of its thickness and length. In some cases, the nerve could not be preserved because it was so thin.

After isolating the nerve, superficial parotidectomy or total parotidectomy was performed in the standard way. During that period, the preserved nerve was covered with a saline-soaked moist gauze with saline. In identifying the main trunk of the facial nerve, the ear lobule was gently retracted. After the removal of the tumor, a drainage tube was inserted

### Methods of Analysis

The sensation of the pinna was evaluated at 2 weeks, 1 month, 2 months, 3 months and 6 months postoperatively. At the time after surgery, patients were interviewed and asked to answer using a Visual Analog Scale (VAS). Sensory disturbance of the pinna was evaluated by touching the pinna using a cotton swab. Grade 0 of the VAS indicated no sensation of the pinna, and Grade 100 indicated no difference in sensation of the pinna as compared with that of the other side.

The QOL after parotidectomy was also evaluated. Grade 0 of the VAS indicated a feeling of most severe discomfort, and Grade 100 indicated no discomfort. Besides the discomfort provoked by the sacrifice, frequent difficulty in wearing earrings and unexpected traumatic lesion due to hyposensitivity of the pinna might be implied.

Statistical analysis of the VAS score was analyzed using the one-way ANOVA. The incidence of

complications was analyzed using the Fischer's exact test. All statistical analyses were performed using SPSS software (Release 10.0, SPSS Inc., Chicago, Illinois).

## Results

### 1) Rate of Preservation

The posterior branch of great auricular nerve was preserved in 26 out of 40 patients (65%). These comprised 12 patients with pleomorphic adenoma, 12 patients with adenolymphoma, 1 patient with acinic cell carcinoma and 1 patient with mucoepidermoid carcinoma. Two patients with carcinoma were diagnosed to have low grade malignancy pre-operatively and the facial nerve was preserved.

In fourteen patients, the great auricular nerve was excised. These comprised 9 patients with pleomorphic adenoma, 4 patients with adenolymphoma and 1 patient with acinic cell carcinoma. The patient with acinic cell carcinoma was misdiagnosed as a high grade malignancy pre-operatively by fine needle aspiration cytology and the great auricular nerve was excised. In the cases with pleomorphic adenoma, the nerve was excised to avoid tumor capsule injury, meaning dissemination of the tumor cells. In cases with adenolymphoma, the nerve was excised mainly due to inflammatory adhesions.

### 2) VAS Score for the Sensation (Table 1)

Two groups, a group in which the posterior branch of the great auricular nerve was preserved (n = 26) and a group in which it was excised (n = 14), were compared for sensory disturbance of the pinna.

Table 2 The VAS score for the QOL after parotidectomy: VAS score was significantly higher in the group of patients whose great auricular nerve was preserved at 2 months, at 3 months and at 6 months after parotidectomy. GAN: the posterior branch of the great auricular nerve

	2 weeks	1 month	2 months	3 months	6 months
GAN preserved n=26	12.7 ± 5.3	30.0 ± 15.0	50.3 ± 21.8	69.5 ± 27.5	71.9 ± 24.1
GAN excised n=14	10.1 ± 5.0	21.1 ± 11.3	35.1 ± 14.5	45.9 ± 22.6	45.7 ± 19.1
p-value	0.148 n.s.	0.058 n.s.	0.025	0.009	0.001

Mean and standard deviation of the VAS score in the preserved and excised groups were  $4.4 \pm 6.8$  and  $4.4 \pm 5.3$  at 2 weeks,  $16.5 \pm 11.6$  and  $10.1 \pm 3.7$  at 1 month,  $35.0 \pm 20.8$  and  $18.5 \pm 9.2$  at 2 months,  $64.4 \pm 18.3$  and  $26.4 \pm 13.8$  at 3 months and  $66.9 \pm 16.2$  and  $26.6 \pm 11.4$  at 6 months after parotidectomy, respectively. The VAS score was significantly higher in the group of patients whose great auricular nerve was preserved, at 2 months ( $p = 0.008$ ), 3 months ( $p = 0.001$ ) and 6 months ( $p = 0.001$ ).

### 3) VAS Score for the QOL (Table 2)

Two groups were compared for the QOL. Mean and standard deviation of VAS score in the preserved and excised groups were  $12.7 \pm 5.3$  and  $10.1 \pm 5.0$  at 2 weeks,  $30.0 \pm 15.0$  and  $21.1 \pm 11.3$  at 1 month,  $50.3 \pm 21.8$  and  $35.1 \pm 14.5$  at 2 months,  $69.5 \pm 27.5$  and  $45.9 \pm 22.6$  at 3 months, and  $71.9 \pm 24.1$  and  $45.7 \pm 19.1$  at 6 months after parotidectomy, respectively. The VAS score was significantly higher in the group of patients whose great auricular nerve was preserved, at 2 months ( $p = 0.025$ ), 3 months ( $p = 0.009$ ) and 6 months ( $p = 0.001$ ).

### 4) Complications of This Procedure

The incidence of complications in this surgical procedure including facial paralysis, postoperative hemorrhage and salivary fistula was analyzed. Two patients with postoperative facial paralysis had paralysis of the marginal branch and recovered within 2 months. In one patient with postoperative hemorrhage, the bleeding was stopped surgically. Two patients with salivary fistula recovered with conservative therapy.

The number of patients with each complication in

the group of patients where the great auricular nerve was preserved ( $n = 26$ ) was 2 (7.7%), 0 (0%) and 1 (3.8%). In the other group ( $n = 14$ ), it was 0 (0%), 1 (7.1%) and 1 (7.1%) respectively. No significant difference was noted between these two groups.

### Discussion

Potential complications of parotidectomy include hemorrhage, infection, salivary fistula, keloid formation, facial nerve paralysis, Frey syndrome and great auricular nerve analgesia. Among them, much attention has been paid to facial paralysis, even its incidence is not so high. Surgeons must take intense care to preserve the facial nerve, however, other complications are also important. Almost all patients undergone parotidectomy suffer from sensory disturbance of the pinna and preauricular region<sup>2</sup>. However, consequences of great auricular nerve sacrifice have not been well studied. Several studies showed the importance of preservation of the nerve<sup>3-6</sup>. However, there have been unresolved problems, such as the details of indication, technique and neurological outcomes. To overcome these unresolved problems, we studied our experiences retrospectively about the preservation of the posterior branch of the great auricular nerve. In this study, we have highlighted the surgical procedure and the neurological outcome of preservation of the greater auricular nerve during parotidectomy.

The great auricular nerve is a useful landmark for identifying the accessory nerve<sup>1</sup> and other organs. Also this nerve is frequently used as a graft for facial nerve reconstruction<sup>7,8</sup>. Its original neurological

function has been commonly neglected. To have a wider exposure, the great auricular nerve is usually excised. Some reports indicated that preservation of the posterior branch of great auricular nerve in parotidectomy is necessary, however, the exact surgical procedure and neurological outcomes are not well known<sup>9</sup>.

When we try any new surgical procedure, the low incidence of adverse events is the most important point to consider. In addition, the surgical technique should be easy to perform and should not be time-consuming. This simple surgical procedure is feasible since it takes less than 30 minutes to complete. Important points of this procedure are how to preserve the nerve gently without retraction stress to it. We usually identify the posterior branch of the great auricular nerve at two points, just beneath the lobule and on the sternocleidomastoid muscle. The nerve is preserved under orientation of these two points. This method is useful as a gentle surgical procedure. We must take much care in identifying the nerve beneath the lobule, because it is very thin at that point. Fine dissection using a surgical knife is thought to be useful. Furthermore, retraction of the pinna must be done gently and carefully in order to avoid inducing tension to the preserved nerve.

The possibility of preservation of the great auricular nerve was finally judged during surgery. In principle, the criteria is similar to that for preservation of the facial nerve in parotidectomy<sup>10,11</sup>. In other words, in the surgery for low grade malignant tumor or benign tumor, it is judged based on the extent of adhesions between the tumor and the nerve. Sometimes, it also depends on the size and location of the tumor. The most important point is to avoid injuries to the capsule and secondly to avoid dissemination of tumor cells<sup>12,13</sup>.

There are some previous reports<sup>3-6</sup> about the neurological outcome of preservation of the great auricular nerve, however, the QOL meaning the comfort of the region was not evaluated. In this study, both neurological outcome and the QOL were evaluated to show that these two were closely related. Therefore, the results of this study indicate

that the surgical procedure for preservation of the posterior branch of the great auricular nerve is important in order to keep the sensation of the pinna. In addition, it further helps to improve the quality of life of the patients after parotidectomy. For these reasons, this surgical procedure should be widely used.

## References

1. Ando M, Beppu M, Nagao M, Miyoshi K, Kohda M: Anatomy of the accessory nerve and its innervation of the Trapezius. *J Jpn Soc Surg Hand* 1992; 9: 288-291.
2. Patel N, Har-El G, Rosenfeld R: Quality of life after great auricular nerve sacrifice during parotidectomy. *Arch Otolaryngol Head Neck Surg* 2001; 127: 884-888.
3. Bozzetti A, Biglioli F, Salvato G, Brusati R: Technical refinements in surgical treatment of benign parotid tumors. *J Cranio-facial surgery* 1999; 27: 289-293.
4. Christensen NR, Jacobsen SD: Parotidectomy. Preserving the posterior branch of the great auricular nerve. *J Laryngol Otolaryngol* 1997; 111: 556-559.
5. Vieira MBM, Maia AF, Ribeiro JC: Randomized prospective study of the validity of the great auricular nerve preservation in parotidectomy. *Arch Otolaryngol Head Neck Surg* 2002; 128: 1191-1195.
6. Hui Y, Wong DSY, Wong LY, Ho WK, Wei WI: A prospective controlled double-blind trial of great auricular nerve preservation at parotidectomy. *Am J Surg* 2003; 185: 574-579.
7. Raddy PG, Arden RL, Mathog RH: Facial nerve rehabilitation after radical parotidectomy. *Laryngoscope* 1999; 109: 894-899.
8. Kerrebijn JD, Freeman JL: Facial nerve reconstruction. *J Otolaryngol* 1998; 27: 183-186.
9. Porter MJ, Wood SJ: Preservation of the great auricular nerve during parotidectomy. *Clin Otolaryngol* 1997; 22: 251-253.
10. Spiro JD, Spiro RH: Cancer of the parotid gland; Role of the 7<sup>th</sup> nerve preservation. *World J Surg* 2003; 14: eub ahead of print.
11. Carinci F, Farina A, Pelucchi S, Calearo C, Pastore A: Parotid gland carcinoma: Surgical strategy based on local risk factors. *J Craniofac Surg* 2001; 12: 434-437.
12. Witt RL: The significance of the margin in parotid surgery for pleomorphic adenoma. *Laryngoscope* 2002; 112: 2141-2154.
13. Becelli R, Perugini M, Mastellone P, Frati R: Surgical treatment of recurrences of pleomorphic adenoma of the parotid gland. *J Exp Clin Cancer Res* 2001; 20: 487-489.

(Received, June 10, 2004)

(Accepted, July 22, 2004)