

A Case of Simultaneous Bilateral Spontaneous Pneumothorax Developed into Tension Pneumothorax

Satoshi Takahashi¹, Takatoshi Yokoyama¹, Norifumi Ninomiya²,
Hiroyuki Yokota² and Yasuhiro Yamamoto²

¹Emergency Care Unit, Seichikai Memorial Hospital

²Department of Acute Medicine, Nippon Medical School

Abstract

Spontaneous pneumothorax is a relatively common disease in the clinical practice setting and is generally recognized to occur most often in slender young men. However, spontaneous pneumothorax that occurs bilaterally and simultaneously and progresses to tension pneumothorax has rarely been documented. Although spontaneous pneumothorax can be diagnosed based on the patient's medical history or information from ambulance personnel, it should be remembered that there are some rare cases of bilateral tension pneumothorax. Prompt and appropriate diagnosis and treatment are necessary for patients with such conditions, which may be life-threatening.

(J Nippon Med Sch 2006; 73: 29–32)

Key words: simultaneous bilateral spontaneous pneumothorax, tension pneumothorax, young male patient

Introduction

Spontaneous pneumothorax is a relatively common condition that occurs most often in slender young men. However, spontaneous pneumothorax that occurs bilaterally and simultaneously and progresses to tension pneumothorax has rarely been documented. We recently encountered a young man with simultaneous bilateral spontaneous tension pneumothorax that developed suddenly. This report describes the case with a review of the literature.

Case Report

The patient was a 19-year-old man. He suddenly

had difficulty breathing while strolling in the park and was transported to this hospital by ambulance.

When emergency personnel arrived, the patient's consciousness was clear, with a blood pressure of 140/100 mmHg, a heart rate of 120 beats/min, a respiratory rate of 30/min, and an SpO₂ of 93%.

Upon arrival at the hospital, the patient's consciousness was clear with a blood pressure of 157/85 mmHg, a heart rate of 86 beats/min, a respiratory rate of 30/min, and an SpO₂ of 89%. The patient looked to be having some difficulty breathing, and with decreased breath sounds bilaterally. The patient's medical and family history was unremarkable.

The results of hematologic and biochemical tests were as follows: white blood cell (WBC), 9,300; red

Correspondence to Satoshi Takahashi, Department of Emergency Medicine, Nippon Medical School, 1-1-5 Sendagi, Bunkyo-ku, Tokyo 113-8603, Japan
E-mail: satosi-emd@jcom.home.ne.jp
Journal Website (<http://www.nms.ac.jp/jnms/>)

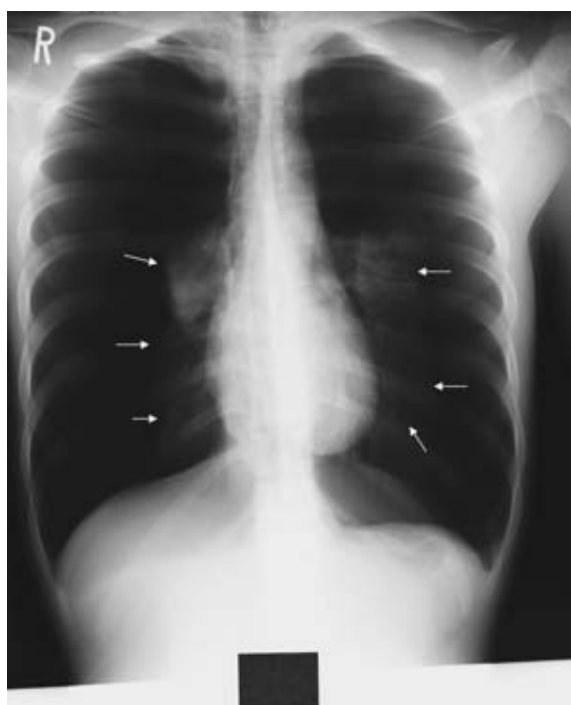

Fig. 1 An x-ray film of the chest on admission. Both lungs are markedly collapsed(white arrow), and the mediastinum is compressed bilaterally. The chest cavity is markedly expanded. The diaphragm has descended bilaterally to an abnormally low position.

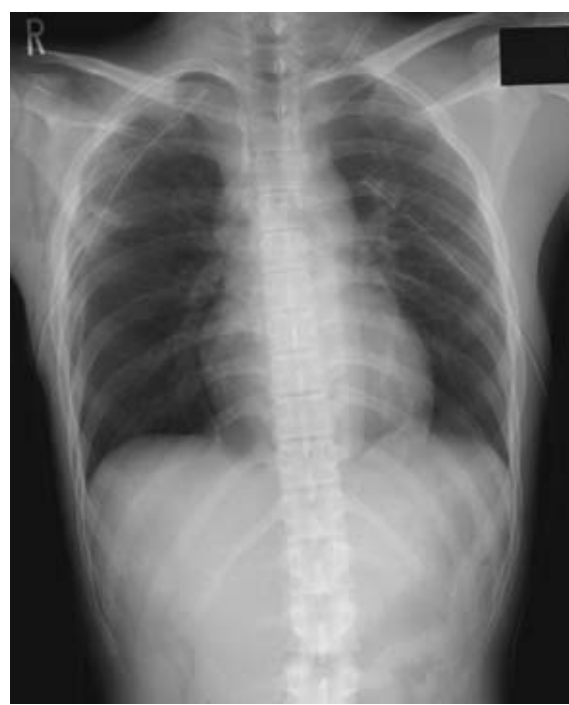

Fig. 2 An chest x-ray film just after simultaneous bilateral pleural drainage. The improvement of the pulmonary collapses is noted.

blood cell (RBC), 529×10^4 ; hemoglobin, 17.0g/dl; hematocrit, 49.0%; platelet count, 31.2×10^4 ; glutamic oxaloacetic transaminase (GOT), 29IU/L; glutamic pyruvic transaminase (GPT), 35IU/L; lactic dehydrogenase (LDH), 258 IU / L; creatin phosphokinaaze (CPK), 517IU/L; total protein (TP), 7.8g/dl; blood urea nitrogen (BUN), 12mg/dl; creatinine, 0.83mg/dl; sodium, 140mEq/l; potassium, 3.6mEq/l; and chloride, 99mEq/l.

Oxygen administration was started immediately, and an x-ray film of the chest was obtained (**Fig. 1**). The patient showed no improvement in dyspnea, still showing difficulty breathing, or in SpO_2 . While waiting for the development of the x-ray film, the blood pressure fell to 90/mmHg by palpitation, and SpO_2 also decreased to 86%.

A diagnosis of bilateral tension pneumothorax (grade III collapse of both lungs) was made on the basis of radiographic findings, and two physicians simultaneously placed pleural drains in both hemithoraces (**Fig. 2**). Subsequently, the blood pressure and SpO_2 were noted to have increased to

120/74mmHg and 96%, respectively, dyspnea improved. The patient was then transferred to the high care unit (HCU), however, air leaks in the pleural drains persisted thereafter. A computed tomography (CT) scan of the chest revealed blebs in both lungs (**Fig. 3**). Because bilateral pneumothorax had developed, the ruptured blebs were sutured via video-assisted thoracoscopic surgery (VATS) at the Department of Thoracic Surgery.

Histopathological examination revealed a continuous airspace in the alveoli of both lungs, and the presence of blebs was thus confirmed.

A postoperative chest x-ray film is shown in **Fig. 4**. The patient had a favorable prognosis after surgery and was discharged home without complications on the 24th hospital day.

Operation Procedures

Using automatic sewing machine (E-GIA[®] × 3), a partial pneumonectomy was performed at the bleb site of the left lung apex. In the right lung, another partial pneumonectomy using E-GIA[®] × 3 was performed on two blebs on the lateral side of the S2

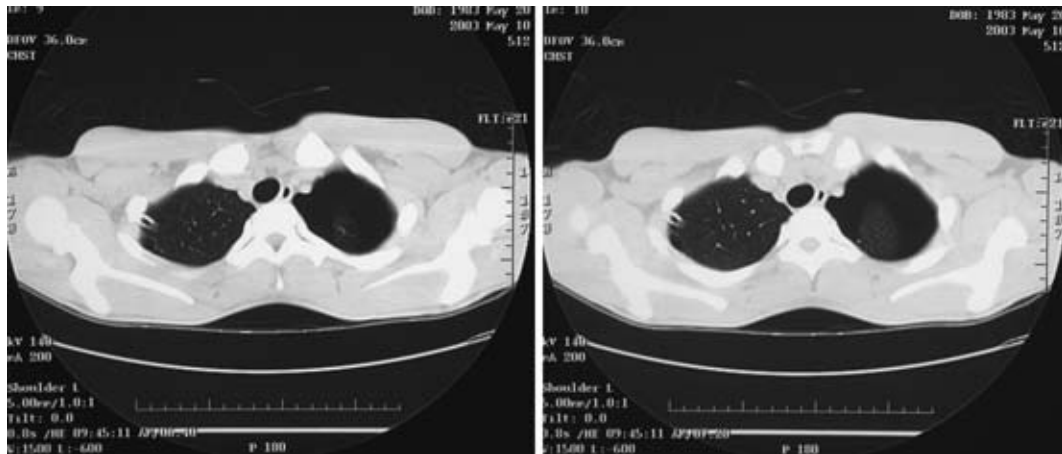


Fig. 3 A computed tomography of the chest obtained after hospitalization. Blebs are seen in the upper lobes of both lungs.

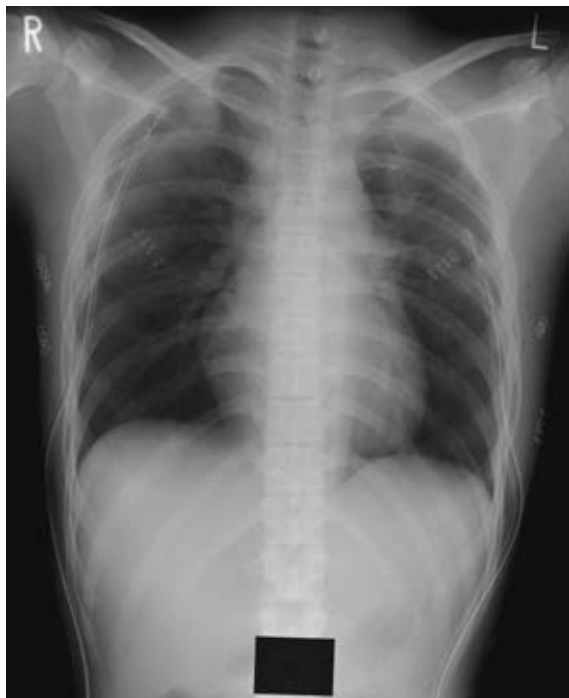

Fig. 4 An x-ray film of the chest just after thoracoscopic surgery. Partial pneumonectomies were performed in both lungs.

region. The surgery was completed by placing a 24-Fr pleural drain in each hemithorax.

Discussion

Spontaneous pneumothorax is common condition. Primary pneumothorax occurs owing to the rupture of pulmonary blebs or bullae, often generally recognized that many patients with this disease are

tall, slender young men. Secondary spontaneous pneumothorax develops from a variety of underlying lung diseases, such as pulmonary tuberculosis and emphysema. Menstruation-associated pneumothorax, or catamenial pneumothorax, is also known as a secondary pneumothorax¹⁻³.

In contrast, simultaneous bilateral spontaneous pneumothorax as in the present case has rarely been reported. A search of the literature revealed some summaries of data on spontaneous pneumothorax, which showed overall incidences of simultaneous bilateral spontaneous pneumothorax is as low as 1.4% or 7.6%²⁴. The incidence of unilateral tension pneumothorax was reported to be 0.5%⁶, whereas few cases of simultaneous bilateral tension pneumothorax have been reported. In these reports, the patients had severe systemic illnesses and were transported to the hospital owing to respiratory arrest⁴⁵. In the present case, dyspnea suddenly developed when the patient was strolling in the park after driving, and no particular factors that may cause spontaneous pneumothorax had been noted. In addition, the patient was a young man who had no significant medical history or underlying lung diseases such as pulmonary tuberculosis and emphysema. However, preoperative CT revealed ruptured blebs in both lungs, and the presence of blebs was also confirmed by the postoperative histopathological examination. These findings were consistent with the most common causes of spontaneous pneumothorax. While pneumothorax is

relatively easily suspected from the patient's medical history and physical findings, the diagnosis was delayed in the present case because we had to wait for the results of the chest x-ray despite the patient's diminished breath sounds, difficulty breathing, and decrease in oxygen saturation.

Furthermore, since the patient had simultaneous bilateral pneumothorax, the chest x-ray film did not reveal any contralateral shift of mediastinum, which is usually observed in unilateral tension pneumothorax, but did show the lungs being compressed bilaterally, as in bathycardia. The physician initially treated the patient then called another emergency specialist to seek a consultation on these unusual findings. However, the patient is condition continued to deteriorate, but fortunately, did not become serious. The present case indicates that when initially treating a patient with suspected pneumothorax based on the medical history or information from ambulance personnel, an emergency care physician should not exclude the possibility of simultaneous bilateral pneumothorax or tension pneumothorax.

The outline of this report was already presented at the 30th General Conference of the Japanese Association for Acute Medicine held in Tokyo in 2003.

References

1. Graf-Deuel E, Knoblauch A: Simultaneous Bilateral Spontaneous Pneumothorax. *CHEST* 1994; 105: 1142–1146.
2. Yano M, Kurisu S, Abe Y, Komagata K, Ogawa N, Morita T, Inagaki K, Arai T: A Study on Surgical Treatment for Spontaneous Pneumothorax. *Jpn J Chest Dis* 1990; 49: 283–288.
3. Tsukioka K: Spontaneous Pneumothorax. *Jpn J Acute Med* 1999; 23: 1329–1331.
4. Taira Y, Osada H, Yokote K, Enami T, Noguchi T, Ko S: A Case of Initial Simultaneous Bilateral Idiopathic Spontaneous Pneumothorax Followed by Acute Asphyxia. *St Marianna Univ Med J* 1986; 14: 532–535.
5. Tamba A, Saito Y, Shibata K, Ohno N, Sasaki N, Hara M, Kato T, Kado-oka H: A Case of Simultaneous Bilateral Pneumothorax in which Acute Suffocation Developed. *Jpn J Acute Med* 1993; 17: 1733–1735.
6. Lang-Lazdunski L, Chapuis O, Bonnet P-M, Pons F, Jancovici R: Videothoroscopic Bleb Excision and Pleural Abrasion for the Treatment of Primary Spontaneous Pneumothorax: Long-Term Results. *Ann Thorac Surg* 2003; 75: 960–965.

(Received, September 14, 2005)

(Accepted, November 7, 2005)