

## Computed Tomography-guided Mediastinal Drainage for Iatrogenic Perforation of the Esophagus

Masao Miyashita<sup>1</sup>, Tsutomu Nomura<sup>1</sup>, Hiroshi Makino<sup>1</sup>, Nobutoshi Hagiwara<sup>1</sup>,  
Ken Takahashi<sup>1</sup>, Yoshinori Sakata<sup>1</sup>, Kazuhiro Nagata<sup>2</sup>, Katsuhiko Iwakiri<sup>2</sup>,  
Hiroyuki Tajima<sup>3</sup> and Takashi Tajiri<sup>1</sup>

<sup>1</sup>Surgery for Organ Function and Biological Regulation, Nippon Medical School Graduate School of Medicine

<sup>2</sup>Department of Gastroenterology, Nippon Medical School

<sup>3</sup>Department of Radiology, Nippon Medical School

### Abstract

We report a case of perforation of the esophagus associated with mediastinitis and pneumomediastinum during endoscopic treatment. The patient was successfully treated by means of nonsurgical computed tomography-guided mediastinal drainage. Esophagoscopy demonstrated a scar on the 14<sup>th</sup> day at the perforation site. This nonsurgical treatment with computed tomography-guided mediastinal drainage is proposed as a less invasive treatment for iatrogenic perforation of the esophagus.

(J Nippon Med Sch 2006; 73: 337–340)

**Key words:** esophageal perforation, endoscopy, nonsurgical treatment

### Introduction

The causes of esophageal perforation are various, and the mortality rate is relatively high. Surgical treatment is often suggested in emergency cases, but postoperative complications are not infrequent<sup>1</sup>. Therefore, the therapeutic strategy remains controversial<sup>2,3</sup>. We report a case of iatrogenic perforation of the esophagus associated with mediastinitis and pneumomediastinum that was successfully treated by nonsurgical computed tomography (CT)-guided drainage of the mediastinum. Despite the small amount of fluid obtained, drainage was effective for treating the pneumomediastinum.

### Case Report

A 66-year-old woman was transferred to our hospital because of iatrogenic perforation of the cervical esophagus associated with mediastinitis. The perforation had occurred at the referring hospital when the over-tube of the endoscope was inserted in the esophagus for endoscopic mucosal resection (EMR) of a gastric tumor. When the endoscope was withdrawn from the stomach, a large perforation was confirmed on the left side of the cervical esophagus (**Fig. 1a**). A plain chest X-ray film showed a translucent area along the esophagus indicating air accumulation (**Fig. 2a**). A CT scan revealed air accumulation in the neck and the

---

Correspondence to Masao Miyashita, MD, Department of Surgery, Nippon Medical School, 1-1-5 Sendagi, Bunkyo-ku, Tokyo 113-8603, Japan

E-mail: miyashit@nms.ac.jp

Journal Website (<http://www.nms.ac.jp/jnms/>)

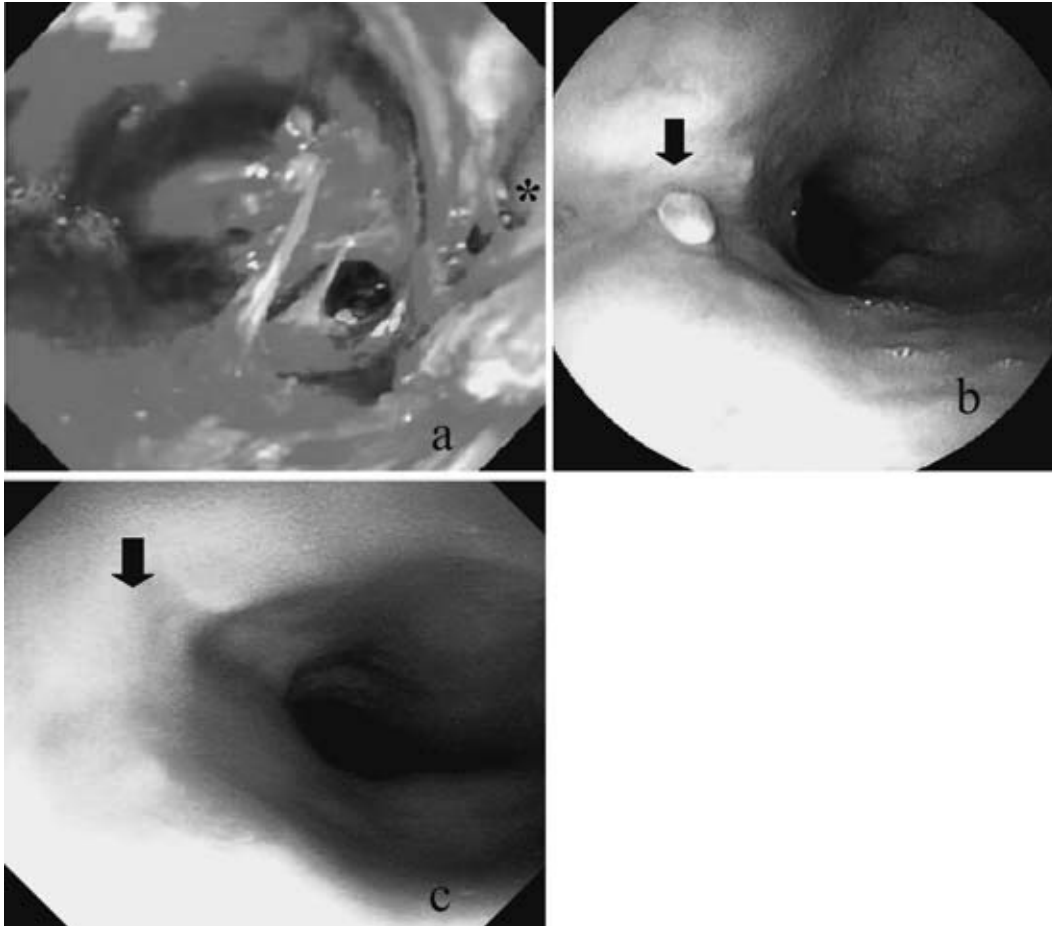


Fig. 1 **a**; Endoscopy revealed a large extraesophageal space from a large perforation of the cervical esophagus. The true esophageal lumen was compressed (**asterisk**). **b**; A linear white-coated ulceration was shown at the site of perforation after 14 days. **c**; The perforation was completely healed after 18 days.

mediastinum which was especially notable around the esophagus and trachea (**Fig. 3a**). Approximately 2 hours after the perforation occurred, the patient was transferred to our hospital. Upon admission, she complained of severe pain of the left side of the neck, and marked tenderness and swelling with subcutaneous emphysema were noted. However, vital signs were normal. The patient had been treated with a calcium antagonist for hypertension and an antidepressant for depression for more than a decade.

Body temperature was 38°C. Laboratory studies showed a peripheral leukocyte count of 17,500/mm<sup>3</sup> but showed no other abnormalities. A CT scan revealed no significant increase in the accumulation of air and exudates in the neck and mediastinum. Eating and drinking were not permitted, and the patient received antibiotics by infusion. On the

following day, the pain and swelling of the neck continued and laboratory studies showed a peripheral blood leukocyte count of 22,800/mm<sup>3</sup> and an elevated serum C-reactive protein concentration of 9.0 mg/ml. Therefore, CT-guided mediastinum drainage using a 5-Fr catheter was performed through the left side of the neck (**Fig. 2b**). Only 20 ml of a dark brownish exudate, indicating pooled blood, was drained during the first 2 days, but the drainage resulted in a significant reduction in inflammatory signs and the resolution of the pneumomediastinum (**Fig. 3b**). On the 8<sup>th</sup> day of drainage, the catheter was removed. On the 14<sup>th</sup> hospital day, esophagography was performed, and a small amount of soluble contrast medium pooled in the injury location in the cervical esophagus. On the same day, esophagoscopy revealed linear, white-coated ulceration in the injured esophageal mucosa

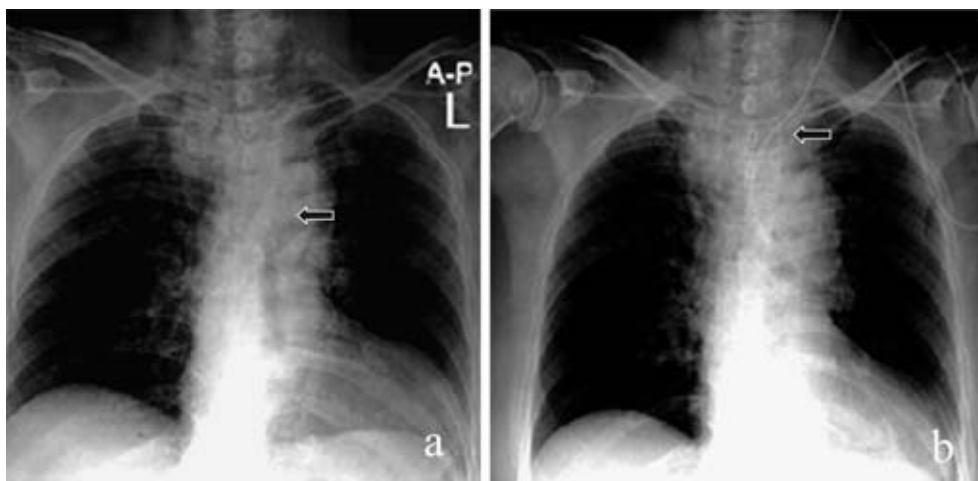


Fig. 2 **a**: A plain chest X-ray film immediately after perforation showed a translucent area along the esophagus indicating air accumulation (**arrow**), **b**: Mediastinal drainage tube along the trachea is shown (**arrow**).

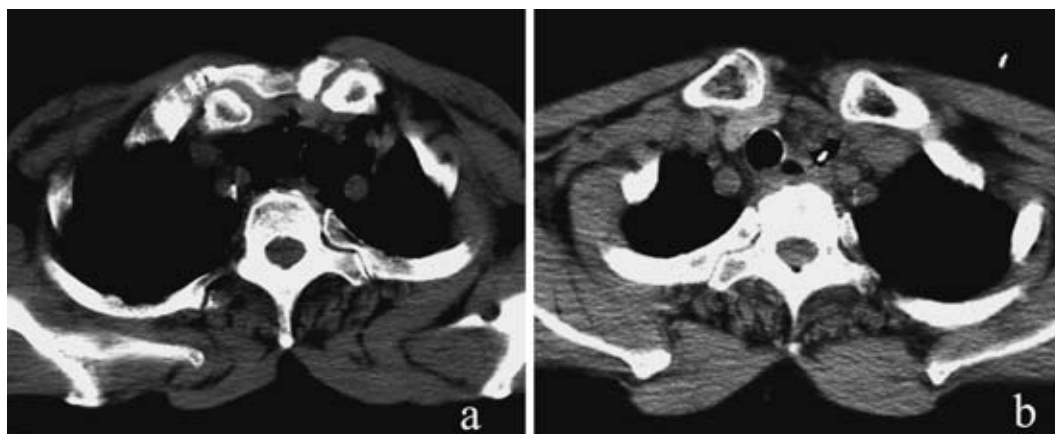


Fig. 3 **a**: A CT scan after perforation revealed marked air accumulation in the neck and mediastinum, especially notable around the esophagus and trachea, **b**: Mediastinal drainage resulted in a significant reduction of air in the mediastinum.

(**Fig. 1b**), and liquid food was permitted. Esophagoscopy performed on the 18<sup>th</sup> hospital day showed only a scar in the same location (**Fig. 1c**). Solid food was then permitted. Because of the patient's depression, the hospital stay was lengthened, but she was finally discharged on the 32<sup>nd</sup> hospital day.

### Discussion

There are several causes of perforation of the esophagus. It is reported that among benign disorders, foreign bodies and idiopathic esophageal rupture are the most frequent causes of esophageal

perforation (Boerhaave's syndrome)<sup>4</sup>. However, the incidence of iatrogenic perforation has recently increased along with endoscopic treatments for gastrointestinal tumors. EMR is the most frequent cause of perforation of the esophagus and the stomach. However, esophageal perforation caused by the over-tube of the endoscope, as in the present case, is extremely rare<sup>5,6</sup>. In this case, the endoscope had been positioned in the stomach when the over-tube was inserted through the endoscope and injured the cervical esophagus. Since such a perforation is unlikely to occur methodologically in this procedure, the exact reason remains unknown.

For treatment of the esophageal perforation,

closure of the perforation and drainage for mediastinitis and pyothorax are most important. When perforation occurs during EMR, clipping of the perforation is recommended<sup>7</sup>. However, because severe pneumomediastinum might develop while clipping is performed, critical judgment is required. In this case, the perforation was too large and was located in the cervical esophagus and, therefore, endoscopic closure might have been extremely dangerous. Whether esophageal perforation is treated surgically or conservatively is still controversial. For Boerhaave's syndrome, surgical closure is recommended within several hours after perforation. As surgical procedures, simple closure of the perforation and patching with the omentum are recommended<sup>8-13</sup>. The prognosis of surgical treatment is not favorable when the patients' general condition is poor or when a considerable time has passed since the perforation, because infection may occur<sup>14,15</sup>. This present patient was transferred to our hospital within several hours after the perforation. A CT scan at admission revealed no fluid and no increase in air accumulation in the mediastinum when compared with scans obtained at the referring hospital. Since the perforation was probably too large for simple closure, and more importantly, since surgery might have increased the risk of infection and delayed wound healing, we selected nonsurgical treatment. However, CT-guided drainage through the neck was performed. Despite the small amount of fluid obtained, drainage was effective for treating the pneumomediastinum and successfully improved the inflammatory signs and symptoms. Because CT-guided puncture is a less-invasive technique for drainage of deep tissues, it is beneficial for patients, such as the present patient, requiring upper mediastinal drainage. Esophagoscopy demonstrated 10 to 14 days of the healing process from the large perforation to the scar; thus, it is thought the wound healing is not delayed with nonsurgical treatment if drainage is sufficient.

In conclusion, the combination of nonsurgical treatment and CT-guided mediastinal drainage is

proposed as a less-invasive treatment for iatrogenic perforation of the esophagus.

## References

1. Michel L, Grillo HC, Malt RA: Operative and nonoperative management of esophageal perforations. *Ann Surg* 1981; 194: 57-63.
2. Amir AI, van Dullemen H, Plukker JT: Selective approach in the treatment of esophageal perforations. *Scand J Gastroenterol* 2004; 39: 418-422.
3. Vogel SB, Rout WR, Martin TD, Abbitt PL: Esophageal perforation in adults: aggressive, conservative treatment lowers morbidity and mortality. *Ann Surg* 2005; 241: 1016-1021.
4. Janjua KJ: Boerhaave's syndrome. *Postgrad Med J* 1997; 73: 265-270.
5. Kitano S, Iwanaga T, Iso Y, et al: A transparent over-tube for endoscopic injection sclerotherapy and results in patients with esophageal varices. *Jpn J Surg* 1987; 17: 256-262.
6. Inci I, Ozcelik C, Nizam O, et al: Traumatic oesophageal perforation. *Scand Cardiovasc J* 1997; 31: 97-100.
7. Sriram PV, Rao GV, Reddy ND: Successful closure of spontaneous esophageal perforation (Boerhaave's syndrome) by endoscopic clipping. *Indian J Gastroenterol* 2006; 25: 39-41.
8. Port JL, Kent MS, Korst RJ, et al: Thoracic esophageal perforations: a decade of experience. *Ann Thorac Surg* 2003; 75: 1071-1074.
9. Ayed AK, Al-Din HJ, Asfar SK: Reinforced primary repair of early distal oesophageal perforation. *Eur J Surg* 2000; 166: 938-941.
10. Huetting WE, van Laarhoven CJ, Gooszen HG: Surgical treatment of distal esophageal perforation not due to a malignancy: results in 11 patients. University Medical Center Utrecht, 1994-1998. *Ned Tijdschr Geneesk* 2000; 144: 1276-1279.
11. Zumbro GL, Anstadt MP, Mawulawde K, et al: Surgical management of esophageal perforation: role of esophageal conservation in delayed perforation. *Am Surg* 2002; 68: 36-40.
12. Avanoğlu A, Ergun O, Mutaf O: Management of instrumental perforations of the esophagus occurring during treatment of corrosive strictures. *J Pediatr Surg* 1998; 33: 1393-1395.
13. Orringer MB, Stirling MC: Esophagectomy for esophageal disruption. *Ann Thorac Surg* 1990; 49: 35-42.
14. Lawrence DR, Ohri SK, Moxon RE, et al: Primary esophageal repair for Boerhaave's syndrome. *Ann Thorac Surg* 1999; 67: 818-820.
15. Sung SW, Park JJ, Kim YT, Kim JH: Surgery in thoracic esophageal perforation: primary repair is feasible. *Dis Esophagus* 2002; 15: 204-209.

(Received, August 14, 2006)

(Accepted, October 10, 2006)