

Two Cases of True Exfoliation of the Lens Capsule after Cataract Surgery

Hideaki Oharazawa¹, Hisaharu Suzuki¹, Hironori Matsui¹,
Toshihiko Shiwa¹, Hiroshi Takahashi¹ and Kunitoshi Ohara²

¹Department of Ophthalmology, Nippon Medical School

²Kichijyoji Minamicho Eye Clinic, Tokyo

Abstract

True exfoliation of the lens capsule is known to be associated with glassblower's cataract, which is caused by extended exposure to excessive heat. Furthermore, inflammation and trauma are also considered to be predisposing factors. We report two cases of true exfoliation that were confirmed after cataract surgery. Neither patient exhibited true exfoliation before cataract surgery. In addition, neither patient had a history of occupation with exposure to excessive heat, inflammation or trauma. We observed the anterior lens capsules of these two patients with slit-lamp microscopy before and after cataract surgery. True exfoliation disappeared by adhering to the anterior capsule in both cases, and there were no complications during the observation period.

(J Nippon Med Sch 2007; 74: 55–60)

Key words: true exfoliation, lens capsule, cataract surgery

Introduction

True exfoliation of the lens capsule is a rare disorder in which the superficial layers of the anterior lens capsule delaminate and float as a clear, thin membrane in the anterior chamber. Elschinig first described true exfoliation of the lens capsule in three glassblowers in 1922¹. True exfoliation was not clearly distinguished from pseudoexfoliation at that time, and these two entities were often confused. True exfoliation and pseudoexfoliation were first described as distinct clinical and pathologic entities by Theobald in 1954². Although exposure to excessive heat, intense infrared radiation,

inflammation, and trauma are all considered to be predisposing factors, the incidence of true exfoliation due to excessive heat and intense infrared radiation has been reduced due to improvements in working conditions. However, idiopathic true exfoliation in elderly persons without the expected occupational history has also been described^{3–5}. In the present report, we describe two cases of true exfoliation that were considered to have developed during, but not before, cataract surgery. These two cases were followed by slit-lamp microscopy for 6 months postoperatively, and these slit-lamp images were recorded on a computer system through a charge-coupled device camera that was connected to the slit-lamp microscope.

Correspondence to Hideaki Oharazawa, MD, Ph D, Department of Ophthalmology, Nippon Medical School Musashi Kosugi Hospital, 1-396 Kosugi-cho, Nakahara-ku, Kawasaki, Kanagawa 211-8533, Japan
E-mail: hideaki@nms.ac.jp
Journal Website (<http://www.nms.ac.jp/jnms/>)

Case Reports

Case 1

An 83-year-old woman was followed up until 1995 for a cataract that was treated without drugs. However, she had been followed up for a gastric ulcer since 1996 and was admitted to the internal medicine department of our hospital. She reported gradual visual loss to her internist during her stay, and we were consulted regarding her ocular disease on April 3, 2002. She had also been treated for polycythemia vera and angina pectoris since 1996. There was no family history of noteworthy systemic or ocular disease. She managed a restaurant, had never been exposed to intense infrared radiation or toxic substances and had no history of trauma, uveitis, or other ocular problems. The best corrected visual acuity (BCVA) was 20/200 in the right eye and 20/40 in the left eye. Tension was 12 mmHg in the right eye and 16 mmHg in the left eye. Slit-lamp examination showed no corneal haze, a clear and deep anterior chamber, and cortical and nucleus cataracts bilaterally. Furthermore, the right eye showed pseudoexfoliation and the right pupil showed poor mydriasis. However, true exfoliation was not confirmed under mydriasis (**Fig. 1**). Ophthalmoscopic examination showed asteroid hyalosis in the left eye.

Visual acuity loss was advanced by cataract progression. After informed consent was obtained from the patient, phacoemulsification and intraocular lens (IOL) implantation were performed in the right eye on April 23, 2002. Immediately after the IOL was implanted in the capsular bag, we observed a cellophane-like clear membrane floating from the superficial layers of the anterior lens capsule at the 9-o'clock position. We then unsuccessfully attempted to remove the membrane using capsular forceps. The surgery was completed without further complications. The postoperative BCVA was 20/25 in the right eye, and the cellophane-like clear membrane, which continued to the superficial layers of the anterior lens capsule at the 9-o'clock position, was observed by slit-lamp examination on the first day postoperatively, and, thus, we diagnosed true

exfoliation (**Fig. 2A**). Two weeks postoperatively, the capsulorhexis edge at the 9-o'clock position turned over, and the fold of the anterior capsule appeared in this area, but true exfoliation could not easily be seen on slit-lamp examination (**Fig. 2B**). One month postoperatively, the anterior capsule contraction had advanced, and fibrotic opacification appeared on the lens capsule, but true exfoliation had disappeared by adherence to the underlayer of the lens capsule, apparent on slit-lamp examination (**Fig. 3**). Six months postoperatively, anterior capsule contraction and fibrotic opacification had advanced further, but true exfoliation was not seen on slit-lamp examination.

Case 2

An 86-year-old man had been followed up for cataracts at another clinic, but visual acuity loss was advanced by cataract progression. The patient was admitted to our hospital for bilateral cataract surgery on March 18, 2002. He had a history of pulmonary emphysema and had been treated for atrial fibrillation in 1990 for which he was receiving medication. There was no family history of noteworthy systemic or ocular disease. He worked as an architect, had never been exposed to intense infrared radiation or toxic substances, and had no history of trauma, uveitis, or other ocular problems. The preoperative BCVA was 20/30 in the right eye and 20/40 in the left eye. Tension was 11 mmHg in the right eye and 12 mmHg in the left eye. Slit-lamp examination showed no corneal haze, a clear and deep anterior chamber, cortical and nucleus cataracts bilaterally, and a posterior capsular cataract in the left eye. However, true exfoliation was not confirmed under mydriasis (**Fig. 4**). Ophthalmoscopic examination showed hard drusen in the left eye.

After informed consent was obtained from the patient, phacoemulsification and IOL implantation were performed in the right eye on April 23, 2002. Immediately after the IOL was implanted in the capsular bag, we observed a cellophane-like clear membrane that curled up in a scroll-like manner from the superficial layers of the anterior lens capsule at the 1-o'clock position, but the surgery was completed without further complications.




Fig. 1 Slit-lamp photograph of the right eye in Case 1. Pseudoexfoliation is shown (arrow), but true exfoliation is not seen preoperatively.

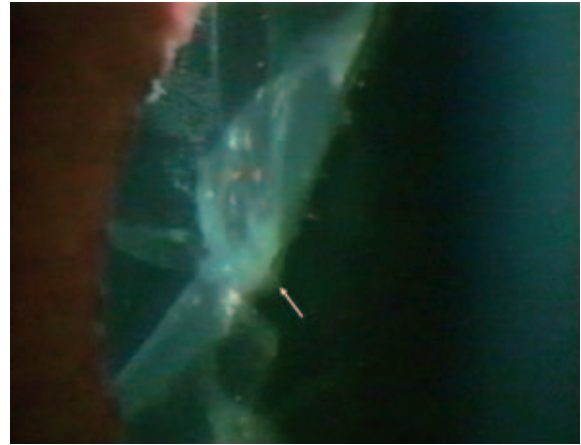


Fig. 3 Slit-lamp photograph of Case 1. One month postoperatively, fibrotic opacification is present, and true exfoliation has disappeared (arrow).

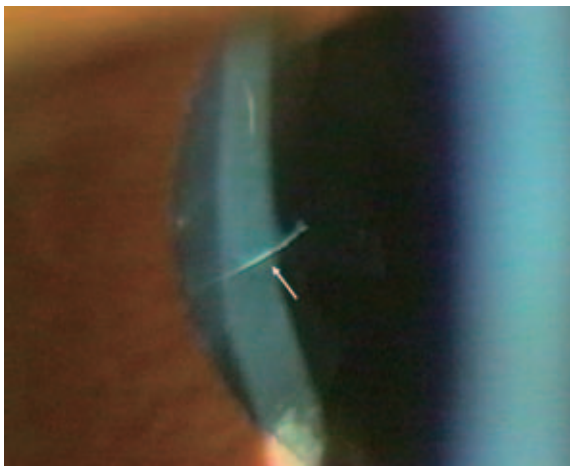


Fig. 2A Slit-lamp photograph of Case 1. First postoperative day, true exfoliation is shown at the 9-o'clock position of the lens capsule (arrow).

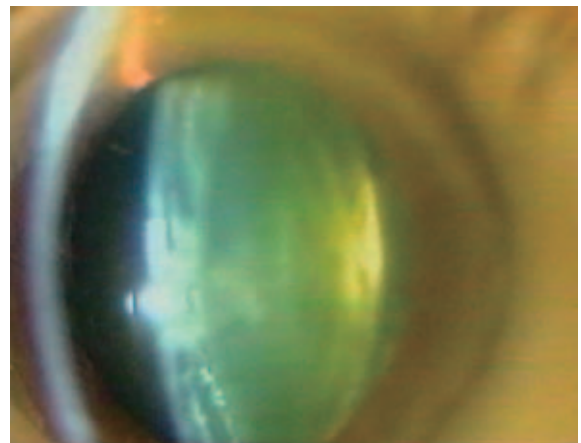


Fig. 4 Slit-lamp photograph of the right eye in Case 2. True exfoliation is not seen preoperatively.




Fig. 2B Slit-lamp photograph of Case 1. Two weeks postoperatively, the capsulorhexis edge is turned over, and the fold of the anterior capsule is seen (arrow).

Postoperative BCVA was 20/20 in the right eye, but the cellophane-like clear membranes remained visible in the superficial layers of the anterior lens capsule at the 1-o'clock and 12-o'clock positions on slit-lamp examination the first day after surgery (Fig. 5A and 5B). The membranes at the 1-o'clock position separated into three layers. We also confirmed that these clear membranes were true exfoliation. One week postoperatively, true exfoliation remained present on slit-lamp examination. One month postoperatively, true exfoliation was unchanged on slit-lamp examination (Fig. 5C). Three months postoperatively, anterior capsule contraction and fibrotic opacification were

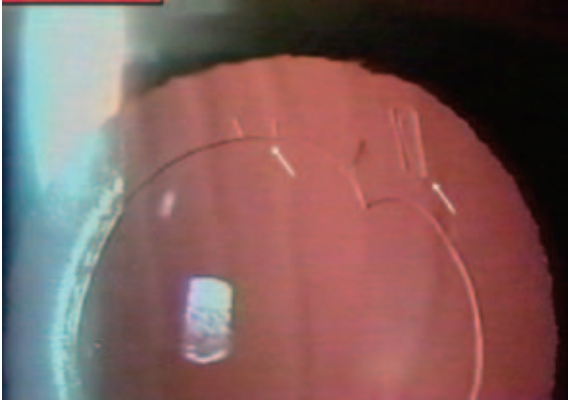


Fig. 5A Retroillumination photograph of Case 2. First postoperative day, true exfoliations are seen at the 1-o'clock and 12-o'clock positions of the lens capsule (arrows).



Fig. 5C Retroillumination photograph of Case 2. One month postoperatively, separation of the membrane into three layers at 1-o'clock position can be observed clearly.



Fig. 5B Slit-lamp photograph of Case 2. First postoperative day, membranes at the 1-o'clock position are observed to be curled up.

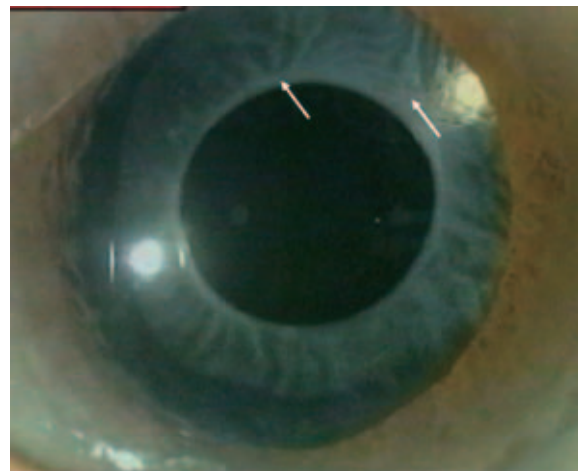

Fig. 6 Slit-lamp photograph of Case 2. Three months postoperatively, capsular contraction and fibrotic opacification are present, and true exfoliation has disappeared.

observed, and true exfoliation had disappeared (**Fig. 6**).

Discussion

Elschnig originally described true exfoliation in three glassblowers in 1922¹. It was previously believed that true exfoliation was associated with a history of exposure to excessive heat and intense infrared radiation. Initially, true exfoliation was not clearly distinguished from pseudoexfoliation and these two entities were often confused. However, the clinical and pathologic differences between true exfoliation and pseudoexfoliation were first described by Theobald in 1954². It was reported that

pseudoexfoliation is composed of fibrillar material, which is produced by aging epithelial or mesenchymal cells, flocculi, and a membrane of accretions of fibrillar material deposited on the surface of the basement membrane⁶. Subsequently, it has been reported that inflammation, trauma, and idiopathic senility are also predisposing factors. Increases in idiopathic true exfoliation in elderly patients have recently been noted³⁻⁵. In the present report, we describe two patients without histories of exposure to excessive heat, intense infrared radiation, uveitis, or trauma and in whom true exfoliation was not observed on slit-lamp

examination before cataract surgery. However, cellophane-like clear membranes that continued to the superficial layers of the anterior lens capsule were confirmed by slit-lamp examination after cataract surgery. We determined that these clear membranes represented true exfoliation.

The lens capsule is composed of layers of collagen fibrils that are joined by interfibrillary cement. Lens epithelial cells continue synthesizing collagen fibrils throughout their lifetime. Although the cause of true exfoliation remains unknown, possible causes include cement substance failure between the collagen fibrils that constitute the lens capsule, regressive changes in the collagen fibrils themselves, and degeneration of lens epithelial cells^{7,8}. Exposure to excessive heat and intense infrared radiation, uveitis, and trauma merely promote these mechanisms⁵.

The layer structure of the lens capsule, which is composed of thin laminated collagen fibrillar sheets, disappears with aging⁹. Although the cause of true exfoliation is not yet known, histochemical studies suggest the involvement of degeneration of fibrillar constituents of the membrane or damage to the interfibrillar cement^{7,8}. It has been considered that age-related changes in the lens play a role in true exfoliation of the lens capsule because true exfoliation appears in older patients and because idiopathic cases in the absence of history are more common in older patients^{3,10,11}. Ultrastructural studies have shown that the lamellar construction, even in the normal lens capsule, changes with age, and it was suggested that delamination of the anterior lamella might develop as a result of degeneration of the fibrillar constituents of the membrane or damage to the interfibrillar cement^{7,8}. Cashwell et al. have reported on 7 patients with idiopathic true exfoliation who were an average age of 85.4 years at the time of diagnosis³. Fiore et al. have also reported idiopathic true exfoliation in an elderly patient (age, 86 years) and suggested that the cause was aging¹². In Japan, idiopathic true exfoliation has been reported in four elderly patients, all of whom were older than 80 years^{5,10,13}.

In our patients, true exfoliation was observed after cataract surgery. Braude and Wallensak et al. have reported that the double-ring sign in the remaining

capsular margins can be observed after continuous curvilinear capsulorhexis in cataract surgery^{14,15}. Furthermore, Wallensak et al. have suggested that there is a weak point in the capsular tissue in the border zone between the zonular lamella of the lens and the capsule proper and that the superficial splits that they observed histologically in this region might be a precursor or forme fruste of true exfoliation¹⁵.

Our present patients were both older than 80 years. We hypothesize that split formation in the lens capsule layer was already present owing to age-related degeneration of the fibrillar constituents in the membrane or damage to the interfibrillar cement. It is possible that the external force exerted on the anterior lens capsule during capsulorhexis delaminated the superficial layer of the anterior lens capsule.

True exfoliation in these patients disappeared during the postoperative follow-up period. As for the mechanism, we hypothesize that the lens epithelial cells migrated and produced extracellular matrix components, such as collagen fiber, between the splits, and we believe that the extracellular matrix adhered to the delaminated membranes to the lower layers of the anterior lens capsule. Clinically, however, there were no complications resulting from true exfoliation formation.

References

1. Elshnig A: Detachment of the zonular lamella in glassblowers. *Klin Monatsbl Augenheilkd* 1922; 69: 732-734.
2. Theobald GD: Pseudo-exfoliation of the lens capsule. *Am J Ophthalmol* 1954; 37: 1-12.
3. Cashwell LF Jr, Holleman IL, Weaver RG, et al: Idiopathic true exfoliation of the lens capsule. *Ophthalmology* 1989; 96: 348-351.
4. Fiore PM, Shingleton BJ: Senile lens exfoliation. *JAMA* 1990; 264: 2755.
5. Asakage H, Ijichi H, Ishiwata T, et al: Report of two cases with idiopathic true exfoliation of lens capsule. —histopathological and electron microscopical study—. *Nippon ganka gakkai zasshi (J Jpn Ophthalmol Soc)* 1994; 98: 664-671.
6. Schlötzer-Schrehardt U, Küchle M, Naumann GOH: Electron-microscopic identification of pseudoexfoliation material in extrabulbar tissue. *Arch Ophthalmol* 1991; 109: 565-570.
7. Callahan A, Klien BA: Thermal detachment of the anterior lamella of the anterior lens capsule. *Arch Ophthalmol* 1958; 59: 73-80.

8. Brodrick JD, Tate GW Jr: Capsular delamination (true exfoliation) of the lens. Report of a case. *Arch Ophthalmol* 1979; 97: 1693-1698.
9. Seland JH: Ultrastructural changes in the normal human lens capsule from birth to old age. *Acta Ophthalmol* 1974; 52: 688-706.
10. Sakai T, Bun J, Okubo K: A case of true exfoliation of the lens capsule. *Atarashii Ganka (J Eye)* 1992; 9: 1761-1764.
11. Shinjo M, Hokama H: Angle closure glaucoma in three cases of true exfoliation of the lens capsule. *Rinsho Ganka (Jpn J Clin Ophthalmol)* 1997; 51: 1091-1094.
12. Fiore PM, Shingleton B: Senile lens exfoliation. *JAMA* 1990; 264: 2755.
13. Fujisawa K, Nakaizumi H: A case of true exfoliation of the lens capsule was confirmed by analysis of Scheimpflug camera image. *Ganka (Ophthalmol)* 1933; 35: 277-279.
14. Braude LS: Partial splitting of the anterior lens capsule giving a double-ring sign. *Arch Ophthalmol* 1995; 113: 705-706.
15. Wollensak G, Wollensak J: Double contour of the lens capsule edges after continuous curvilinear capsulorhexis. *Graefe's Arch Clin Exp Ophthalmol* 1997; 235: 204-207.

(Received, October 25, 2006)

(Accepted, November 21, 2006)