

## Argon Plasma Coagulation for the Treatment of Superficial Esophageal Carcinoma

Tsutomu Nomura, Masao Miyashita, Hiroshi Makino, Hiroshi Maruyama,  
Miwako Katsuta, Moto Kashiwabara, Ken Takahashi, Koji Sasajima,  
Kiyohiko Yamashita and Takashi Tajiri

Surgery for Organ Function and Biological Regulation, Graduate School of Medicine, Nippon Medical School

### Abstract

**Aims:** Recently, endoscopic mucosal resection (EMR) has become the first choice of treatment for superficial esophageal cancer without metastasis. However, EMR is not safe for all patients. Argon plasma coagulation (APC) is a noncontact electrocoagulation technique that creates tissue damage. The risk of bleeding may be lower with APC than with EMR. Therefore, we selected APC for the treatment of patients with superficial esophageal cancer who could not undergo EMR. The aim of the present study was to describe these cases and analyze the results of this treatment.

**Patients and Methods:** Ten patients with superficial esophageal cancer underwent APC at our institution from February 2001 through January 2002. None of the patients could undergo EMR because of complications. Ablation was performed using an APC probe (ERBE APC probe; ERBE Elektromedizin, Tübingen, Germany), a high-frequency electro-surgical generator (ERBE ICC200), and an argon delivery unit (ERBE APC 300). All patients had uneventful recoveries.

**Results:** No incidents of bleeding from the ablated lesion or infection occurred. Oral intake was resumed on the day after treatment. The mean duration of the procedure was 20 minutes (range, 10 to 40 minutes). Disease recurred in two patients. Two patients died of laryngeal cancer and liver failure, respectively.

**Conclusion:** APC is a safe and easy to perform procedure, but the effect of therapy is inferior to that of EMR in terms of the complete resection of the lesion. In conclusion, APC should be limited to cases of superficial esophageal cancer without metastasis in which EMR has been deemed difficult.

(J Nippon Med Sch 2007; 74: 163–167)

**Key words:** argon plasma coagulation, esophageal cancer

### Introduction

Argon plasma coagulation (APC) is a noncontact

electrocoagulation technique that creates tissue damage. Recently, APC has been widely used for therapeutic endoscopy<sup>1</sup>. APC has been used for the treatment of gastric antral vascular ectasia<sup>2</sup>. Yusoff

---

Correspondence to Tsutomu Nomura, MD, Department of Surgery, Nippon Medical School, 1-1-5 Sendagi, Bunkyo-ku, Tokyo 113-8603, Japan

E-mail: nomura-t@nms.ac.jp

Journal Website (<http://www.nms.ac.jp/jnms/>)

et al. have described the usefulness of APC for the treatment of gastric antral vascular ectasia and has reported medium-term outcomes after ablation<sup>3</sup>. Barrett esophagus and Barrett adenocarcinoma in situ can also be successfully treated with APC<sup>4,5</sup>. Morris et al. have reported that endoscopic ablation with APC prevents the neoplastic progression of Barrett esophagus<sup>6</sup>.

Recently, endoscopic mucosal resection (EMR) has been the standard therapeutic procedure for mucosal cancer of the stomach, colon, and esophagus. Operations for esophageal cancer sometimes involve a risk of postoperative complications because of the great surgical stress. More recently, EMR has become the first choice of treatment for superficial esophageal cancer without metastasis. Narahara et al. have reported that 25 superficial esophageal cancers lesions in 21 patients were completely removed using EMR<sup>7</sup>. Fujita et al. have reported that mortality and morbidity rates are lower after EMR than after esophagectomy among patients with mucosal cancer<sup>8</sup>. However, EMR is not safe for all patient. For example, patients with liver cirrhosis often cannot undergo EMR because of hemorrhagic diathesis and esophageal varices. APC may have a lower risk of bleeding than EMR. Therefore, we selected APC for the treatment of patients with superficial esophageal cancer who could not undergo EMR. However, few reports have described the utility of APC for the treatment of superficial squamous cell carcinoma (SCC) of the esophagus. The aim of the present study was to describe these cases and to analyze the results of this treatment based on our experience, thereby evaluating the efficacy and risk of APC for the treatment of superficial SCC of the esophagus.

### Patients and Methods

APC was performed in the Endoscopy Unit of our hospital. Patients were sufficiently informed of the related effects and complications, and their consent was obtained. All patients were hospitalized before APC. Patients were sedated with 7.5 to 15 mg of benzodiazepine during the procedure. Noninvasive monitoring of blood pressure and pulse and pulse

oximetry were routinely performed. The patients were usually given a single dose of the antibiotic cefazolin immediately before endoscopy. We used a single-channel gastroscope. An iodine staining procedure using 3% iodine solution was used to confirm the area of the superficial cancer of the esophagus. Ablation was performed using an APC probe (ERBE APC probe; ERBE Elektromedizin, Tübingen, Germany), a high-frequency electrosurgical generator (ICC200, ERBE), and an argon delivery unit (APC 300, ERBE). The flow of argon gas and the power were set at 2.0 L/min and 60 W, respectively. The APC probe was positioned 1 to 2 mm from the mucosa, and 1- to 2-second pulses of ablation were repeated until the lesion was completely coagulated. The goal of ablation was the formation of a pale yellow coagulum over the unstained area (**Fig. 1b**). Insufflated argon gas was aspirated at regular intervals to prevent excessive distension of the stomach and small intestine. After treatment, the patients received an injection of flumazenil to neutralize the benzodiazepine. All patients were given proton-pump inhibitors for approximately 4 weeks to reduce the risk of gastric acid reflux.

Ten patients with superficial esophageal cancer underwent APC at our institution from February 2001 through January 2002. Endoscopy revealed non-iodine-stained superficial lesions that were histologically diagnosed as either SCC or high-grade dysplasia. The patients' characteristics are summarized in **Table 1**. Nine men and one woman with a mean age of 70 years (range, 65 to 74 years) were treated. Four patients (patients 1 to 4) could not undergo EMR because of liver cirrhosis with esophageal varices. Patient 1 had a superficial cancer that had recurred 3 years after being treated with 60 Gy of radiation. APC was selected as an easy treatment for superficial esophageal cancer in three other patients with incurable advanced cancer (patients 5 to 7). In patients 8 and 9, extended high-grade dysplasia around an EMR scar was treated with APC. Recurrent SCC after EMR ablation was treated with APC in patient 10. The first endoscopic examination after APC was performed on postoperative day 7, and follow-up examinations

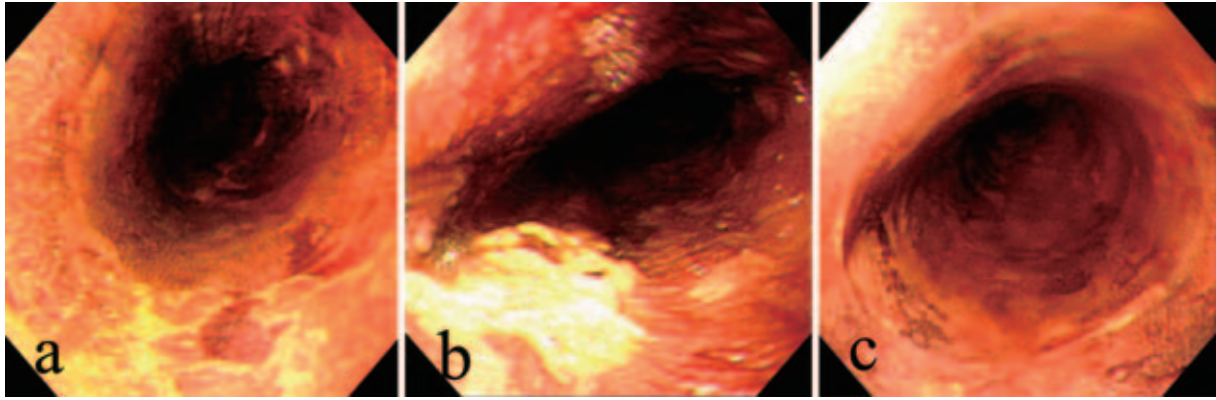


Fig. 1  
 a: Before APC  
 b: After APC  
 c: 3 months after APC

Table 1

Case	Sex	Age	Type	Complication	Treatment before APC	Outcome
1.	M	64	0-IIc	Liver Cirrhosis, Varix	Radiation	31 months, recurrence
2.	M	71	0-IIb	Liver Cirrhosis	Radiation	26 months
3.	M	69	0-IIb	Liver Cirrhosis	Radiation	38 months
4.	M	71	0-IIa	Liver Cirrhosis, Hepatoma	CRT (after-APC)	12 months, dead
5.	M	69	0-IIb	Gastric Ca., Angina, Cerebral infarction	None	26 months, recurrence
6.	M	73	0-IIb	Liver Cirrhosis, Hepatoma	None	38 months
7.	F	74	0-IIc	lower Laryngeal Ca.	EMR	4 months, dead
8.	M	65	0-IIb	Liver Cirrhosis, Hepatoma	EMR	26 months
9.	M	72	0-IIb	Gastric Ca., Pancreatic Ca	EMR	26 months
10.	M	71	0-IIb	Prostate Ca.	EMR	26 months

M, male; F, female; Ca, carcinoma; APC, argon plasma coagulation; EMR, Endoscopic mucosal resection; CRT, Chemoradiotherapy

were repeated at intervals of 2 to 3 months thereafter (**Fig. 1c**).

### Results

All the patients had uneventful recoveries. No incidents of bleeding from the ablated lesion or infection occurred. Oral intake was resumed on the day after treatment.

The mean duration of the procedure was about 20 minutes (range, 10 to 40 minutes). Two patients (patients 1 and 4) underwent two APC procedures within 1 week because lesions were too wide to be ablated during a single procedure, but additional ablation was not required in the other patients. The mean follow-up period was  $28 \pm 5.1$  months (range,

23 to 38 months).

Disease recurred in two patients (patients 1 and 5). High-grade dysplasia developed at the ablated area 5 months after the first APC treatment in patient 1. Endoscopic iodine staining revealed an unstained area that was similar to the appearance of the lesion before APC, and a second APC procedure was performed. Patient 5 underwent APC because of a tendency to bleed caused by medication for cerebral infarction and angina pectoris. The recurrence was observed 6 months after the initial treatment, and a second APC procedure was performed. Two patients died of other diseases: laryngeal cancer (patient 7) and liver failure (patient 4). No recurrence after APC was observed in these patients.

## Discussion

The APC treatments were successful in 6 cases. Ablation of the esophageal mucosa in the horizontal and perpendicular directions was thought to be sufficient in these cases. The depth of degeneration in the esophageal wall caused by APC at the setting used in this study is thought to be the submucosal layer<sup>9</sup>; therefore, the present report's method should be sufficient to treat superficial cancer of the esophagus. Deep tissue damage leading to perforation has been reported to be rare at ordinary APC settings<sup>9</sup>, and no incidents of perforation or bleeding occurred in the present series.

Recurrences were observed in two cases. The cause of the recurrences was thought to be insufficient ablation because the shapes of the recurrent lesions were similar to those observed before ablation in both cases. Cancer cells that survived the initial treatment may have been covered by regenerating epithelium. Consequently, the recurrences were not detected with endoscopic examination for several months. The risk of recurrence is thought to be higher for wider lesions. Therefore, sufficient ablation is necessary, especially for wide lesions.

The present indications for APC for the treatment of esophageal cancer should be limited to patients who are unable to undergo EMR because of severe complications, such as severe bleeding diathesis. EMR should continue to be the endoscopic therapy of first choice for superficial cancer of the esophagus.

Barrett adenocarcinoma in situ has been successfully treated using APC. Regarding long-term survival, Attwood et al. have reported that 22 of 29 patients showed complete remission after APC, and none of the patients died of esophageal adenocarcinoma during a 7-year follow-up period<sup>10</sup>. Van Laethem et al. have also reported that 8 of 10 patients with histologically proven high-grade dysplasia or adenocarcinoma associated with Barrett esophagus showed complete remission after APC, with no evidence of local recurrence during a median follow-up period of 24 months (range, 12 to 36 months)<sup>5</sup>. In our study, disease recurred in 2 of 10

patients; however, none of the patients died of esophageal SCC during a mean follow-up period of  $28 \pm 5.1$  months (range, 23 to 38 months). APC appears to be as effective for treating esophageal SCC as for treating esophageal adenocarcinoma. However, this assumption has not yet been confirmed because of the scarcity of reports of superficial esophageal SCC being treated with APC.

Radiotherapy is sometimes considered as a treatment for superficial esophageal cancer when EMR is difficult to perform. Histological examination is impossible with both radiotherapy and APC. However, radiotherapy has been associated with both pulmonary fibrosis and severe esophagitis. Furthermore, esophageal stenosis (3%) and esophagoaortic or esophagobronchial fistulae (3%) developed after chemoradiotherapy (CRT) in patients with superficial cancer<sup>11</sup>. Therefore, we selected APC for cases in which EMR was deemed difficult. The question of whether endoscopic treatment is possible is of critical importance for the management of esophageal cancer because other treatments, such as surgery, radiation, and chemotherapy, can cause serious complications. An accurate diagnosis of the clinical stage is indispensable for appropriate treatment selection.

## Conclusion

APC has both advantages and disadvantages as an endoscopic treatment for superficial esophageal cancer. APC is a safe procedure, but its therapeutic effect is inferior to that of EMR in terms of complete resection of the lesion.

In conclusion, although APC is technically safe and easy to perform, its indications should be limited to cases of superficial esophageal cancer without metastasis in which EMR has been deemed difficult. Nevertheless, the indications for APC may be extended in the future.

## References

1. Akhtar K, Byrne JP, Bancewicz J, et al: Argon beam plasma coagulation in the management of cancers of the esophagus and stomach. *Surg Endosc* 2000; 14: 1127-1130.

2. Wahab PJ, Mulder CJ, den Hartog G, et al: Argon plasma coagulation in flexible gastrointestinal endoscopy: pilot experiences. *Endoscopy* 1997; 29: 176-181.
3. Yusoff I, Brennan F, Ormonde D, et al: Argon plasma coagulation for treatment of Water melon stomach. *Endoscopy* 2002; 34: 407-410.
4. May A, Gossner L, Gunter E, et al: Local treatment of early cancer in short Barrett's esophagus by means of argon plasma coagulation: initial experience. *Endoscopy* 1999; 31: 497-500.
5. Van Laethem JL, Jagodzinski R, Peny MO, et al: Argon plasma coagulation in the treatment of Barrett's high-grade dysplasia and in situ adenocarcinoma. *Endoscopy* 2001; 33: 257-261.
6. Morris CD, Byrne JP, Armstrong GRA, et al: Prevention of the neoplastic progression of Barrett's oesophagus by endoscopic argon beam plasma ablation. *Br J Surg* 2001; 88: 1357-1362.
7. Narahara H, Ishi H, Tatsuta M, et al: Effectiveness of endoscopic mucosal resection with submucosal saline injection technique for superficial squamous carcinomas of the esophagus. *Gastrointest Endosc* 2000; 52: 730-734.
8. Fujita H, Sueyoshi S, Yamana H, et al: Optimum treatment strategy for superficial esophageal cancer: endoscopic mucosal resection versus radical esophagectomy. *World J Surg* 2001; 25: 424-431.
9. Watson JP, Bennett MK, Griffin SM, et al: The tissue effect of argon plasma coagulation on esophageal and gastric mucosa. *Gastrointest Endosc* 2000; 52: 342-345.
10. Attwood SE, Lewis CJ, Caplin S, Hemming K, Armstrong G: Argon beam plasma coagulation as therapy for high-grade dysplasia in Barrett's esophagus. *Clin Gastroenterol Hepatol* 2003; 1: 258-263.
11. Yamada K, Murakami M, Okamoto Y, et al: Treatment results of chemoradiotherapy for clinical stage I (T1N0M0) esophageal carcinoma. *Int J Radiat Oncol Biol Phys* 2006; 64: 1106-1111.

(Received, December 19, 2006)

(Accepted, February 21, 2007)