

## Successful Use of Endoscopic Argon Plasma Coagulation for Patients with Early Gastric Cancer and Diabetes Mellitus

Masao Ogata<sup>1</sup>, Kentaro Maejima<sup>1</sup>, Naoto Chihara<sup>1</sup>, Satoshi Mizutani<sup>1</sup>,  
Osamu Komine<sup>1</sup>, Hideki Bo<sup>1</sup>, Takeshi Shioya<sup>1</sup>, Masanori Watanabe<sup>1</sup>,  
Akira Tokunaga<sup>1</sup> and Takashi Tajiri<sup>2</sup>

<sup>1</sup>Institute of Gastroenterology, Nippon Medical School Musashi Kosugi Hospital

<sup>2</sup>Surgery for Organ Function and Biological Regulation, Graduate School of Medicine, Nippon Medical School

### Abstract

We report on two patients with gastric tumors (early cancer and adema) and diabetes mellitus who were treated with argon plasma coagulation (APC) therapy. Case 1. A 78-year-old woman visited the Nippon Medical School Musashi Kosugi Hospital because of epigastric pain. An early gastric cancer (IIc) in the anterior wall of the gastric antrum was diagnosed on the basis of the results of a gastric endoscopy examination. The patient had had diabetes mellitus for 18 years and had injected insulin (NovoRapid 30 Mix<sup>®</sup>, 72 units/day) by herself everyday for 10 years. Case 2. A 61-year-old man was referred to our hospital because of a gastric tumor. A gastric adenoma in the anterior of the gastric antrum was diagnosed on the basis of the results of a gastric endoscopy examination. The patient had had diabetes mellitus for 12 years and had been taking oral medication for 2 years. Endoscopic APC was performed in both patients to remove the gastric tumors. These patients have been well for 28 months and 30 months, respectively, after undergoing APC treatment. APC therapy appears to be a safe and useful treatment for patients with diabetes and gastric mucosal lesions.

(J Nippon Med Sch 2007; 74: 246-250)

**Key words:** early gastric cancer, gastric adenoma, diabetes mellitus, argon plasma coagulation

### Introduction

Argon plasma coagulation (APC) was introduced to endoscopic therapy in 1991 and has been used in Japan since 1997<sup>1-3</sup>. APC is a noncontact technique that can be used for rapid tissue coagulation. APC has been used to treat many gastrointestinal diseases, including bleeding peptic ulcer, watermelon stomach, hemorrhagic proctitis, and esophageal and

colonic varices<sup>4-6</sup>. Recently, APC has also been used for the treatment of early gastric cancers; however, standard indications for APC are lacking<sup>7-9</sup>. Patients with diabetes mellitus require careful treatment because of the increased risk of complications such as hemorrhage and impaired wound healing. Here, we describe two patients with gastric tumors and diabetes mellitus who were treated with APC therapy.

---

Correspondence to Masao Ogata, MD, Institute of Gastroenterology, Nippon Medical School Musashi Kosugi Hospital, 1-396 Kosugi-cho, Nakahara-ku, Kawasaki, Kanagawa 211-8533, Japan

E-mail: masao@nms.ac.jp

Journal Website (<http://www.nms.ac.jp/jnms/>)

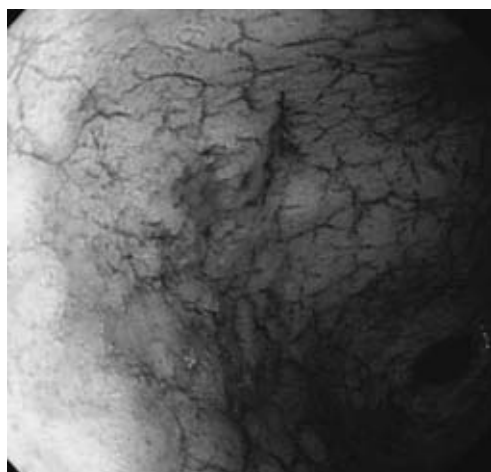


Fig. 1 A gastroscopy reveals a IIc lesion in the anterior wall of the gastric antrum.

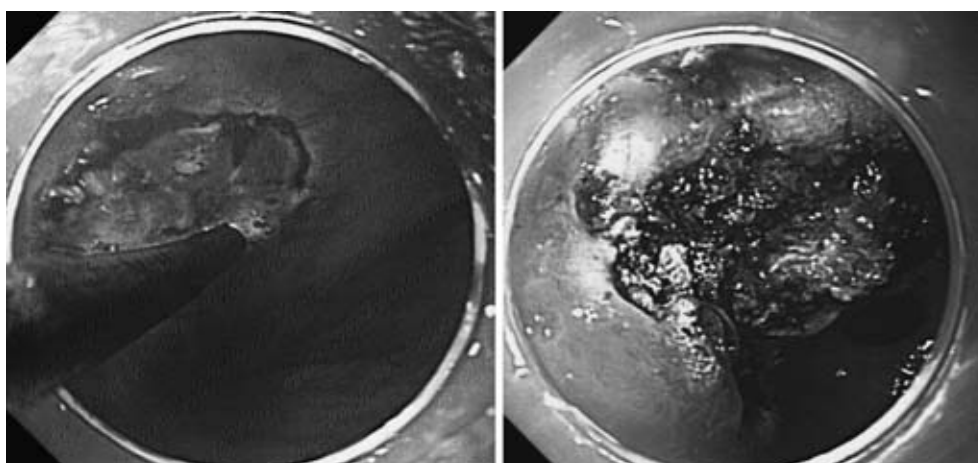


Fig. 2 APC therapy is used to a IIc lesion in the anterior wall of the gastric antrum after marking.

### Case Reports

Case 1: A 78-year-old woman visited our hospital in June 2004 because of epigastric pain. She did not smoke cigarettes or drink alcohol. She had undergone surgery for an ovarian cyst at the age of 73 years and had had diabetes mellitus for 18 years. She had been self-injecting insulin (NovoRapid 30 Mix<sup>®</sup>, 72 units/day) for 10 years. Her family history was unremarkable. A physical examination noted obesity; she was 161 cm tall and weighted 80 kg. No evidence of abdominal tumors or hepatosplenomegaly was seen. Laboratory studies showed a high serum blood glucose level (225 mg/dl) and HbA1c level (8.1%). Level of tumor markers,

including CEA (2.6 ng/ml) and CA19-9 (7 U/ml) were within the normal ranges. A gastric cancer (IIc) in the anterior of the gastric antrum was diagnosed on the basis of the results of a gastric endoscopy examination (**Fig. 1**). A biopsy of the stomach led to a diagnosis of Group V cancer (tubular adenocarcinoma well differentiated type). Endoscopic treatment with APC was then performed (**Fig. 2**). The APC settings were as follows: a high-frequency arc output of 60 W and an argon gas flow rate of 2 l/min using a flexible APC probe (ICC200, ERBE Inc.). The APC therapy was performed without difficulty, but a deep ulceration was observed on the day following APC therapy (**Fig. 3**). No evidence of the tumor or recurrence has been observed for 28 months.

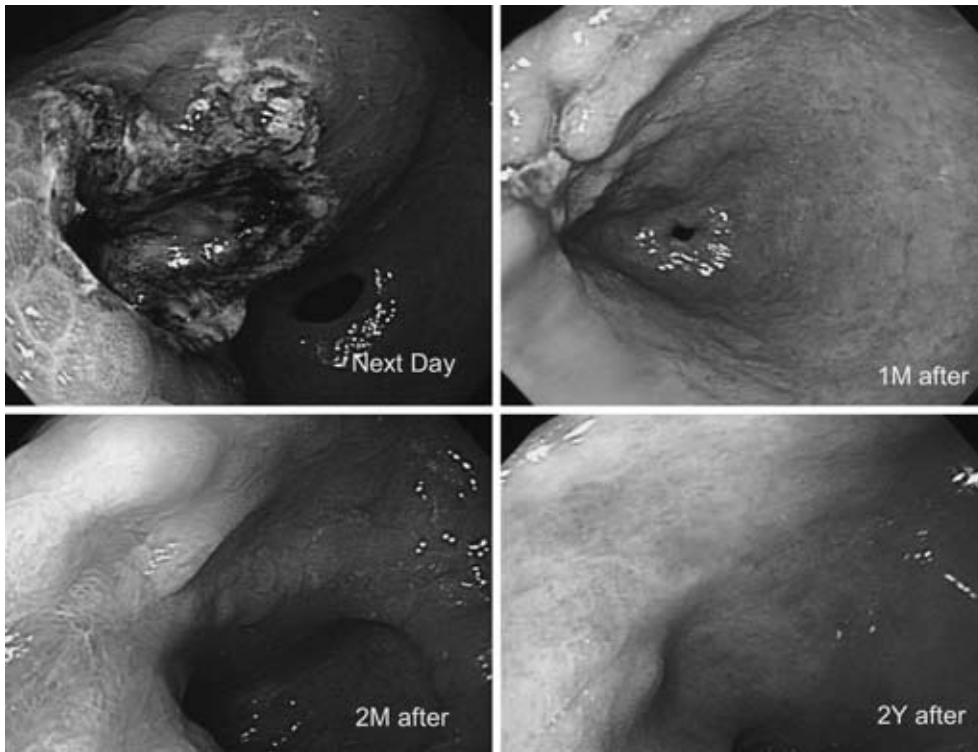


Fig. 3 The courses of APC therapy (Next day, 1M, 2M, 2Y after) were very good, but there was the deep ulceration in the next day of APC therapy.

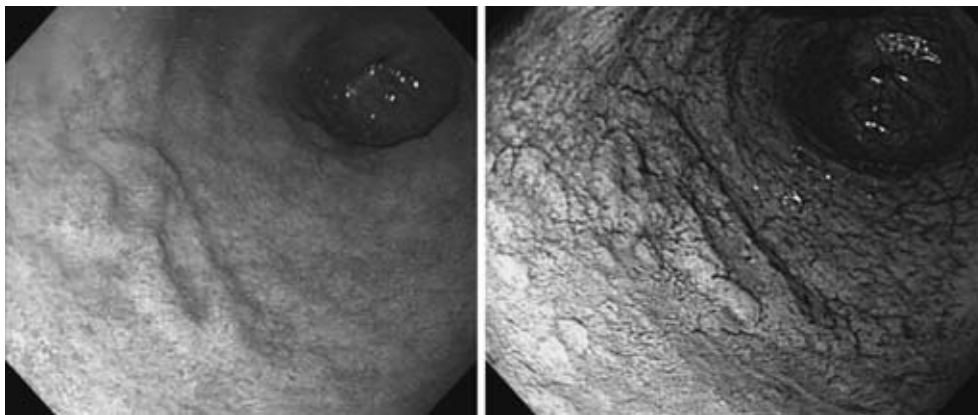


Fig. 4 A gastroscopy reveals a IIc like lesion in the anterior wall of the gastric antrum.

Case 2: A 61-year-old man was referred to our hospital because of a gastric tumor in April 2004. He drank alcohol occasionally but did not smoke cigarettes. He had a 13-year history of hypertension and a 12-year history of diabetes mellitus, which had been treated with oral medication for 2 years. The family history was unremarkable. A physical examination noted obesity: he was 164 cm tall and weighted 86 kg. No evidence of abdominal tumors or hepatosplenomegaly was seen. Laboratory studies showed a high serum blood glucose level (136 mg/dl

and HbA1c level (6.5%). Level of tumor markers, including CEA (2.3 ng/ml) and CA19-9 (6 U/ml), were within the normal ranges. A gastric adenoma in the anterior of the gastric antrum was diagnosed on the basis of the results of a gastric endoscopy examination (Fig. 4). A biopsy of the stomach led to a diagnosis of a group III, adenoma. Endoscopic treatment with APC was then performed (Fig. 5). The APC settings were the same as in case 1. The APC therapy was performed without difficulty, but a deep ulceration was observed on the day following

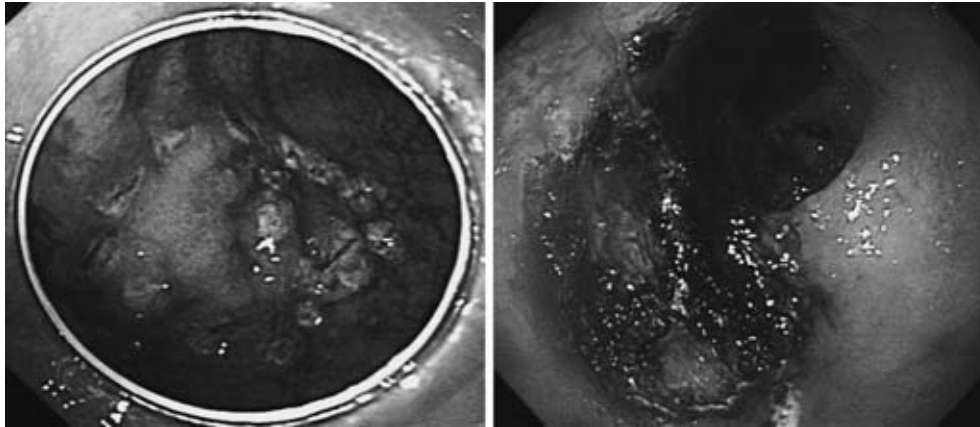


Fig. 5 APC therapy is used to a IIC like lesion in the anterior wall of the gastric antrum after marking.

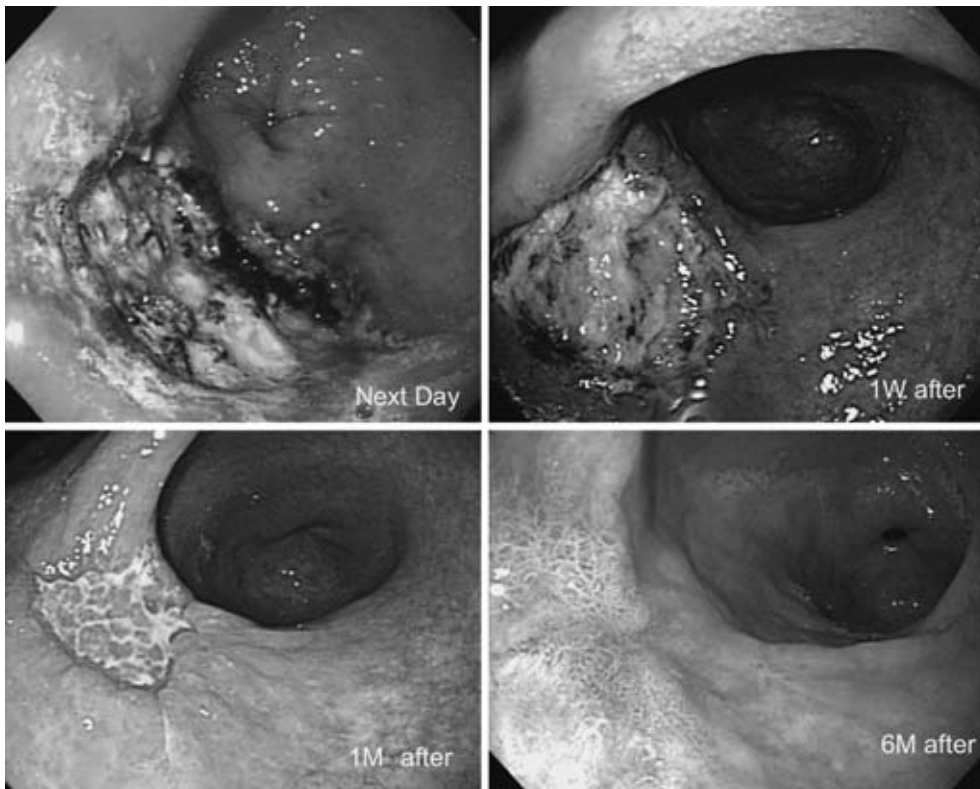


Fig. 6 The courses of APC therapy (Next day, 1W, 1M, 6M after) were very good.

APC therapy (**Fig. 6**). No evidence of the tumor or recurrence has been observed for 30 months.

### Discussion

APC has been used for 10 years to treat many gastrointestinal diseases, including bleeding peptic ulcer, watermelon stomach, hemorrhagic proctitis, and esophageal and colonic varices, as well as early gastric cancer<sup>4-9</sup>. A standard procedure for APC,

however, is lacking. APC has been used for the treatment of patients with early gastric cancer patients who also have liver cirrhosis, diabetes mellitus or renal failure<sup>10,11</sup>. Because, APC therapy cannot obtain specimens, unlike endoscopic submucosal dissection, periodical follow-up study is required. A previously reported patient with gastric cancer and diabetes mellitus died of sepsis after undergoing an endoscopic mucosal resection<sup>12</sup>. Therefore, patients with diabetes mellitus require

careful treatment because of the increased risk of complications such as perforation, bleeding, infection, and late recovery. Here, we have described two patients with gastric tumors (early cancer and adenoma) and diabetes mellitus who were treated with APC therapy. The first patient had an 18-year history of diabetes mellitus and had been using large amounts of insulin (NovoRapid 30 Mix<sup>®</sup>, 72 units/day). Therefore, special care in the treatment of the early gastric cancer was required. We selected APC therapy because of the minimal risk of complications. The second patient, who had a gastric adenoma, also underwent APC therapy for same reason. In both cases, a deep ulceration was observed on the day following the APC therapy. However, the clinical course after APC therapy was good, and late complications did not occur. Both patients recovered uneventfully. No evidence of the tumors or recurrence has been seen for 28 and 30 months, respectively.

APC has been used to safely treat many gastrointestinal diseases, including watermelon stomach, hemorrhagic proctitis, and esophageal varices<sup>4-6</sup>. Wound healing in patients with diabetes mellitus has been shown to be impaired, and APC has been used instead of endoscopic submucosal dissection, which is thought to be dangerous for patients with hemorrhagic tendency or renal failure. APC therapy appears to be a safe and useful treatment for patients with diabetes mellitus and early gastric cancer or gastric adenoma.

### References

1. Farin G, Grund KE: Technology of argon plasma

- coagulation with particular regard to endoscopic applications. *Endosc Surg* 1994; 2: 71-77.
2. Grund KE, Storek D, Farin G: Endoscopic argon plasma coagulation (APC) first clinical experiences in flexible endoscopy. *Endosc Surg Allied Technol* 1994; 2: 42-46.
3. Taisei R, Chibai M, Fujisaki J, et al.: New Hemostasis: experience & usefulness of argon plasma coagulation. *Prog Dig Endosc* 1997; 50: 133-136.
4. Cipolletta L, Bianco MA, Rotondando G, et al.: Prospective comparison of argon plasma coagulator and heater probe in the endoscopic treatment of major peptic ulcer bleeding. *Gastrointest Endosc* 1998; 48: 191-195.
5. Gretz JF, Achem SR: The watermelon stomach: clinical presentation, diagnosis, and treatment. *Am J Gastroenterol* 1999; 94: 2909-2911.
6. Yusoff I, Brennan F, Ormonde D, et al.: Argon plasma coagulation for treatment of watermelon stomach. *Endoscopy* 2002; 34: 407-410.
7. Tsunajima K, Sato S, Hayashi T: Analysis of the long-term outcome early gastric cancer patients treated by argon plasma coagulation therapy. *Endosc Forum for digestive disease* 2005; 21: 143-149.
8. Kitamura T, Tanabe S, Saigenji K, et al.: Argon plasma coagulation for early gastric cancer: technique and outcome. *Gastrointest Endosc* 2006; 63: 48-54.
9. Murakami M, Nishino K, Tanabe S, et al.: Argon plasma coagulation for the treatment of early gastric cancer. *Hepatogastroenterology* 2004; 51: 1658-1661.
10. Sagawa T, Takayama T, Oku T, et al.: Argon plasma coagulation for successful treatment of early gastric cancer with intramucosal invasion. *Gut* 2003; 52: 334-339.
11. Kitamura T, Tanabe S, Saigenji K: Usefulness of argon plasma coagulation (APC). *Gastroenterol Endosc* 2003; 45: 1560.
12. Tohyama Y, Yoshinaga K, Kobayashi S, et al.: A case of early dead patient with gastric cancer after EMR. *Tokyo Jikeikai Medical School Kashiwa Hospital medical annual* 2006; 13: 37-39.

(Received, February 19, 2007)

(Accepted, April 18, 2007)