

## A Case of Unresectable Gallbladder Cancer Responding to Gemcitabine after Metallic Biliary Stent Implantation

Takeshi Matsutani<sup>1,2</sup>, Eiji Uchida<sup>1</sup>, Tadashi Yokoyama<sup>1,2</sup>,  
Akira Matsushita<sup>1,2</sup>, Akihisa Matsuda<sup>1,2</sup> and Koji Sasajima<sup>1,2</sup>

<sup>1</sup>Surgery for Organ Function and Biological Regulation, Graduate School of Medicine, Nippon Medical School

<sup>2</sup>Department of Surgery, Nippon Medical School Tama Nagayama Hospital

### Abstract

A 69-year-old woman with a chief complaint of jaundice was referred to our hospital. She underwent exploratory laparotomy under a diagnosis of advanced biliary tract cancer. Histological examination of a biopsy specimen of the gallbladder revealed adenocarcinoma. The tumor was unresectable because of invasion into a wide area of the hepatoduodenal ligament and liver bed. Retrograde transhepatic bile drainage tubes were inserted through the common bile duct into the right and left branches of the intrahepatic bile ducts. After metallic biliary stent implantation, gemcitabine (1,000 mg) was administered intravenously once a week for 2 weeks, followed by 1 week of rest. After 2 courses of chemotherapy, computed tomography showed significant reductions in the size of target tumors and serum CA19-9 levels had normalized. Tumor size was stable for more than 6 months. The patient has been able to maintain a good quality of life without any severe adverse effects of chemotherapy. Gemcitabine therapy after metallic biliary stent implantation might be safe and effective in patients with unresectable gallbladder cancer.

(J Nippon Med Sch 2009; 76: 253–257)

**Key words:** gallbladder cancer, gemcitabine, metallic biliary stent

### Introduction

Gallbladder cancer is often at an advanced stage when diagnosis, because it frequently invades the liver, hepatoduodenal ligament, colon, and pancreas<sup>1,2</sup>. The prognosis for patients with advanced or metastatic gallbladder cancer is extremely poor, and the median survival time is only a few months<sup>3,4</sup>. Metallic biliary stent insertion has become a standard palliative treatment for patients with

obstructive jaundice caused by biliary malignancies<sup>5,6</sup>. However, no standard chemotherapy or chemotherapeutic regimen has been defined for biliary malignancies. Therefore, it is essential to develop new therapeutic strategies to improve clinical outcomes. To date, several trials have suggested that combination chemotherapy may lengthen survival and improve quality of life in patients with advanced biliary tract cancer when compared with best supportive care<sup>7,8</sup>. Gemcitabine (2'-deoxy-2'-difluorodeoxycytidine) has recently been

---

Correspondence to Takeshi Matsutani, MD, Department of Surgery, Nippon Medical School Tama Nagayama Hospital, 1-7-1 Nagayama, Tama, Tokyo 206-8512, Japan

E-mail: matsutani@nms.ac.jp

Journal Website (<http://www.nms.ac.jp/jnms/>)

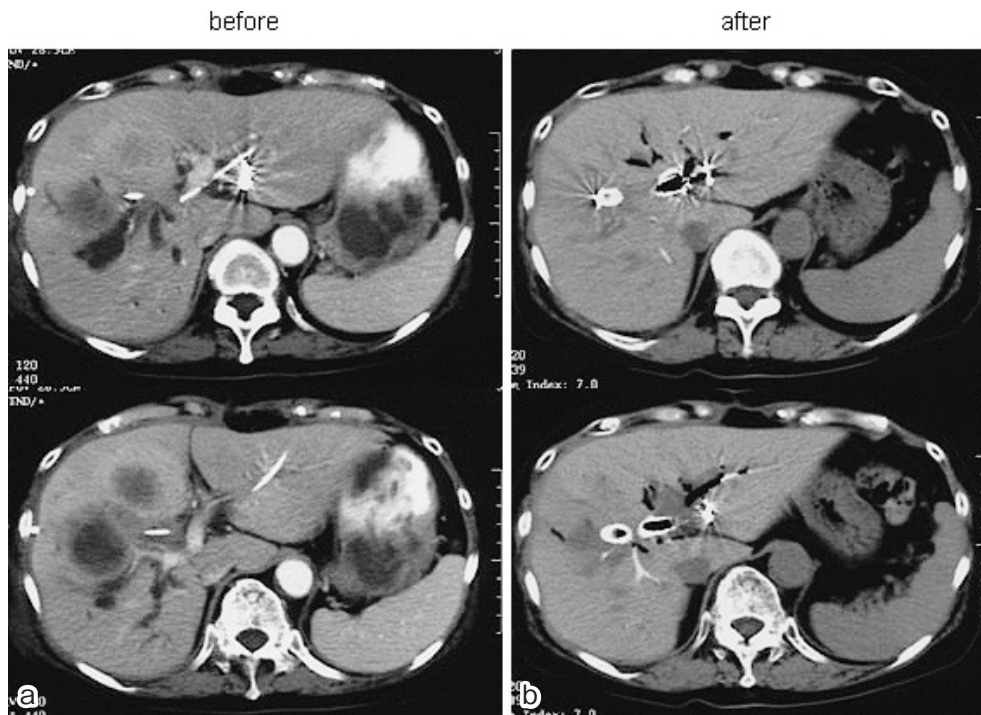

Fig. 1 Abdominal computed tomography showing tumors before (a) and after (b) chemotherapy. a) Tumors have invaded the right and middle lobes of the liver. b) Lesions have decreased in size.

reported as a new, effective anticancer drug for the treatment of advanced biliary tract and gallbladder cancers<sup>9-15</sup>. We report herein the efficiency of chemotherapy using gemcitabine after metallic biliary stent implantation in a patient with unresectable advanced gallbladder cancer.

### Case Report

A 69-year-old Japanese woman was admitted to our hospital with chief complaints of upper abdominal discomfort and jaundice. Past history included an asymptomatic gallbladder polyp found 4 years earlier. She had not received any clinical treatment before this admission. Physical examination revealed jaundice without palpable lymphadenopathy. Vague right upper quadrant fullness was present, but the gallbladder was not palpable. No ascites or peripheral edema was evident. Laboratory tests showed: alkaline phosphatase, 3,118 IU/L;  $\gamma$ -glutamyl transpeptidase, 790 IU/L; aspartate aminotransferase, 206 IU/L; alanine aminotransferase, 181 IU/L; and total bilirubin, 5.5 mg/dL. The serum level of carbohydrate antigen

(CA) 19-9 was significantly elevated at 3,008.5 U/mL (normal, 0–50 U/mL). Level of carcinoembryonic antigen and  $\alpha$ -fetoprotein were within their normal ranges.

Contrast-enhanced computed tomography of the abdomen on admission revealed multiple irregular ring-enhancing masses in the liver and enlargement of the gallbladder (**Fig. 1a**). Magnetic resonance cholangiopancreatography (MRCP) showed dilatation of the intrahepatic bile ducts and partial wall thickness of the enlarged gallbladder (**Fig. 2**). The patient then underwent subcutaneous transhepatic cholangiography with the therapeutic intent of implanting a percutaneous transhepatic biliary drainage catheter from the left intrahepatic bile duct. Endoscopic retrograde cholangiography revealed severe stenosis of the middle common bile duct, as seen with MRCP. The Results of cytologic examination of bile drainage fluid were class II. On the Basis of these findings, gallbladder cancer with invasion to the common bile duct and liver was diagnosed, and exploratory laparotomy was performed.

During the operation, the gallbladder cancer was

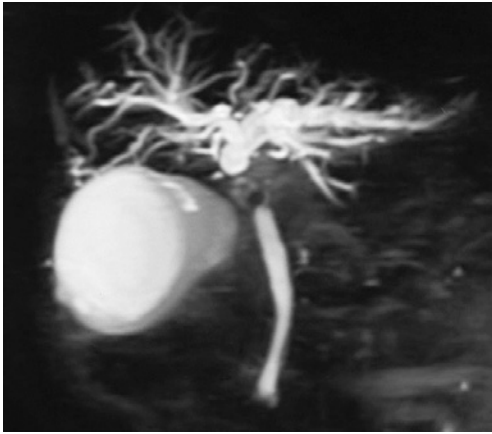


Fig. 2 MRCP revealing dilatation of the intrahepatic bile ducts, partial wall thickness of the enlarged gallbladder and stenosis of the common bile duct.

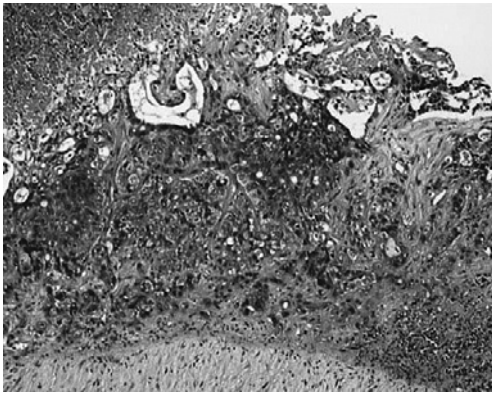

Fig. 3 Biopsy specimen of the gallbladder revealing moderately differentiated adenocarcinoma. Hematoxylin and eosin staining,  $\times 100$ .

determined to be unresectable with massive direct invasion into the hepatoduodenal ligament and liver. Histopathological examination of biopsy specimens from the gallbladder showed moderately differentiated adenocarcinoma (**Fig. 3**). Two retrograde transhepatic biliary drainage (RTBD) tubes were inserted from the common bile duct into the right and left branches of the bile duct. On postoperative day 13, three expanding metallic stents (EMSs) (Luminexx<sup>TM</sup> Biliary Stent System; C.R. Bard, Murray Hill, NJ, USA) were implanted in the stenotic lesion following both RTBD tubes (**Fig. 4**).

On postoperative day 20, systemic chemotherapy, consisting of gemcitabine (1,000 mg) for 1 hour each

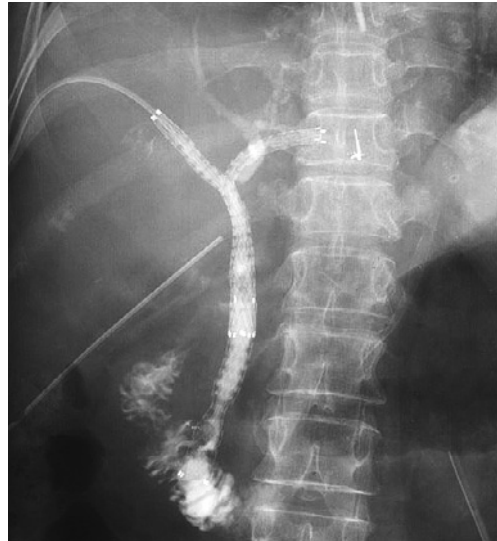

Fig. 4 Metallic biliary stents placed through an RTBD route from the intrahepatic hepatic duct to the lower common bile duct.

week for 2 weeks followed by 1 week of rest, was started. The patient tolerated chemotherapy well, and no severe side effects were observed during treatment. Chemotherapy caused grade 1 leucopenia but no gastrointestinal toxicity. At monthly follow-up examinations, abdominal computed tomography revealed significant reductions in tumor size after gemcitabine treatment. The response to chemotherapy was evaluated to be partial response according to the Response Evaluation Criteria in Solid Tumors (RECIST) guidelines (**Fig. 1b**). During therapy, serum bilirubin levels decreased to within the normal range, and serum levels of CA19-9 decreased markedly from 2,880 IU/mL to 147.5 IU/mL (**Fig. 5**). The patient was treated on an outpatient basis with good quality of life until gemcitabine treatment was finished after 6 cycles, as progressive jaundice occurred owing to tumor growth in the biliary stent. The patient died 8 months after the start of gemcitabine treatment.

## Discussion

Despite recent advances in various therapeutic managements, surgical resection remains the only cure for gallbladder cancer. Palliative treatment of unresectable gallbladder cancer is required for the various conditions caused by invasion of the bile

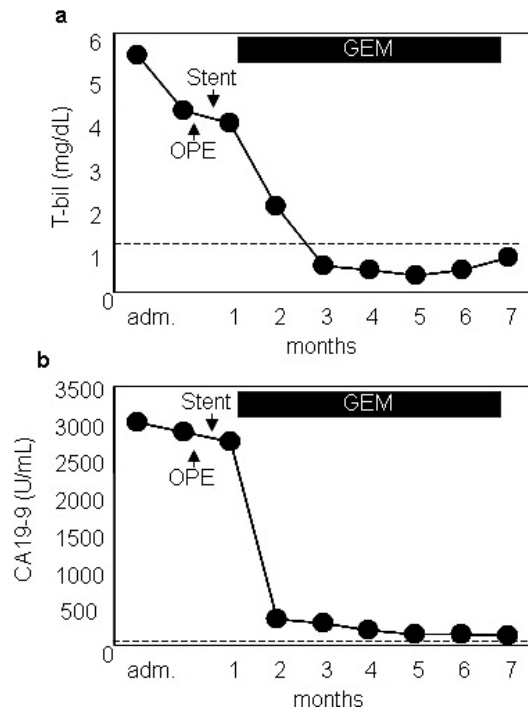


Fig. 5 Changes in serum concentrations of total bilirubin (a) and CA19-9 (b) before and after gemcitabine therapy.

duct, portal vein, or duodenum either directly or through lymph-node metastases. Recently, metallic biliary stent implantation has become a standard palliative treatment for the patients with obstructive jaundice caused by hepatobiliary malignancies or metastatic tumors<sup>5,6</sup>. Biliary drainage can effectively prevent secondary complications of cholestasis, such as pruritus, maldigestion, cholangitis and sepsis. In our patient, RTBD tubes were inserted through the stenosis of the common bile duct during exploratory laparotomy. The metallic biliary stent was then easily positioned at the appropriate location through the percutaneous transhepatic route guided by RTBD tubes. Decompression of the bile duct by metallic biliary stent implantation clearly decreases plasma bilirubin levels and improves quality of life.

No definitive chemotherapeutic regimen has been established for advanced or metastatic biliary tract and gallbladder cancers. For pancreatic cancer, gemcitabine is more effective than fluorouracil, which has traditionally been considered the standard agent and remains the most widely used first-line agent for adenocarcinomas of the gastrointestinal tract<sup>16</sup>. Among several new anticancer drugs being

investigated, gemcitabine is an attractive option for advanced biliary tract and gallbladder carcinomas<sup>9-15</sup>. Because the biliary apparatus (gallbladder and bile duct) shares a common embryologic origin in the exocrine pancreas, gemcitabine has been considered a reasonable choice against advanced biliary tract and gallbladder cancers. The first trial was reported by Metzger et al.<sup>17</sup>, who used intravenous gemcitabine at a dose of 1,000 mg/m<sup>2</sup> to treat 13 patients with locally advanced or metastatic gallbladder/biliary tract cancer. Although a partial response was achieved in only 1 patient (8%), stable disease was achieved in 11 patients. The median time to progression was 7 months and the median overall survival time was 16 months. In recent phase II studies of patients with advanced biliary tract cancer, gemcitabine monotherapy at a dose of 1,000 mg/m<sup>2</sup> achieved overall response rates of 17.5% to 36% and median survival times of 7.2 to 7.6 months<sup>13-15</sup>. Until now, new combination chemotherapy regimens comprising gemcitabine and S-1 have been the focus of attention and have been thoroughly investigated in patients with advanced pancreatic cancer<sup>18</sup>. However, the ability to perform efficacy assessments of systemic treatment in phase II studies may be limited, because patients with biliary tract cancers and those with gallbladder cancers are usually analyzed together in most reported trials<sup>17,19</sup>. Responses to chemotherapy might differ between advanced biliary tract carcinomas and gallbladder carcinomas. To clarify the therapeutic effects of gemcitabine, further trials should include large numbers of patients and distinguish gallbladder cancer from bile duct cancer.

In conclusion, chemotherapy with gemcitabine after metallic biliary stent implantation was effective for improving quality of life without causing severe side effects or toxicities in a patient with advanced unresectable gallbladder cancer.

## References

1. Bartlett DL, Fong Y, Fortner JG, Brennan MF, Blumgart LH: Long-term results after resection for gallbladder cancer. Implications for staging and management. *Ann Surg* 1996; 224: 639-646.
2. Benoist S, Panis Y, Fagniez PL: Long-term results

- after curative resection for carcinoma of the gallbladder. French University Association for Surgical Research. *Am J Surg* 1998; 175: 118-122.
3. Kayahara M, Nagakawa T: Recent trends of gallbladder cancer in Japan: an analysis of 4,770 patients. *Cancer* 2008; 110: 572-580.
  4. Gourgiotis S, Kocher HM, Solaini L, Yarollahi A, Tsiambas E, Salemis NS: Gallbladder cancer. *Am J Surg* 2008; 196: 252-264.
  5. Davids PH, Groen AK, Rauws EA, Tytgat GN, Huibregtse K: Randomised trial of self-expanding metal stents versus polyethylene stents for distal malignant biliary obstruction. *Lancet* 1992; 340: 1488-1492.
  6. Knyrim K, Wagner HJ, Pausch J, Vakil N: A prospective, randomized, controlled trial of metal stents for malignant obstruction of the common bile duct. *Endoscopy* 1993; 25: 207-212.
  7. Glimelius B, Hoffman K, Sjoden PO, et al: Chemotherapy improves survival and quality of life in advanced pancreatic and biliary cancer. *Ann Oncol* 1996; 7: 593-600.
  8. Takada T, Nimura Y, Katoh H, et al: Prospective randomized trial of 5-fluorouracil, doxorubicin, and mitomycin C for non-resectable pancreatic and biliary carcinoma: multicenter randomized trial. *Hepatogastroenterology* 1998; 45: 2020-2026.
  9. Castro MP: Efficacy of gemcitabine in the treatment of patients with gallbladder carcinoma: a case report. *Cancer* 1998; 82: 639-641.
  10. Gallardo J, Fodor M, Gamargo C, Orlandi L: Efficacy of gemcitabine in the treatment of patients with gallbladder carcinoma: a case report. *Cancer* 1998; 83: 2419-2421.
  11. Teufel A, Lehnert T, Stremmel W, Rudi J: Chemotherapy with gemcitabine in patients with advanced gallbladder carcinoma. *Z Gastroenterol* 2000; 38: 909-912.
  12. Verderame F, Mandina P, Abruzzo F, Scarpulla M, Di Leo R: Biliary tract cancer: our experience with gemcitabine treatment. *Anticancer Drugs* 2000; 11: 707-708.
  13. Okusaka T, Ishii H, Funakoshi A, et al: Phase II study of single-agent gemcitabine in patients with advanced biliary tract cancer. *Cancer Chemother Pharmacol* 2006; 57: 647-653.
  14. Gallardo JO, Rubio B, Fodor M, et al: A phase II study of gemcitabine in gallbladder carcinoma. *Ann Oncol* 2001; 12: 1403-1406.
  15. Lin MH, Chen JS, Chen HH, Su WC: A phase II trial of gemcitabine in the treatment of advanced bile duct and periampullary carcinomas. *Chemotherapy* 2003; 49: 154-158.
  16. Moore M: Activity of gemcitabine in patients with advanced pancreatic carcinoma. A review. *Cancer* 1996; 78: 633-638.
  17. Metzger JY, Sauerbruch T, Ko Y, Wolter H, Funk C, Glasmacher A: A phase II trial of gemcitabine in gallbladder and biliary tract carcinomas. *Onkologie* 1998; 21: 232-234.
  18. Nakamura K, Yamaguchi T, Ishihara T, Sudo K, Kato H, Saisho H: Phase II trial of oral S-1 combined with gemcitabine in metastatic pancreatic cancer. *Br J Cancer* 2006; 94: 1575-1579.
  19. Raderer M, Hejna MH, Valencak JB, et al: Two consecutive phase II studies of 5-fluorouracil/leucovorin/mitomycin C and of gemcitabine in patients with advanced biliary cancer. *Oncology* 1999; 56: 177-180.

(Received, June 29, 2009)

(Accepted, August 17, 2009)