

Working Memory Processing for Human Voice Perception in a Patient with Mild Cognitive Impairment: an fMRI Study

Michihiko Koeda, Amane Tateno, Kosuke Ishizaka,
Tomoyuki Saijo and Yoshiro Okubo

Department of Neuropsychiatry, Graduate School of Medicine, Nippon Medical School

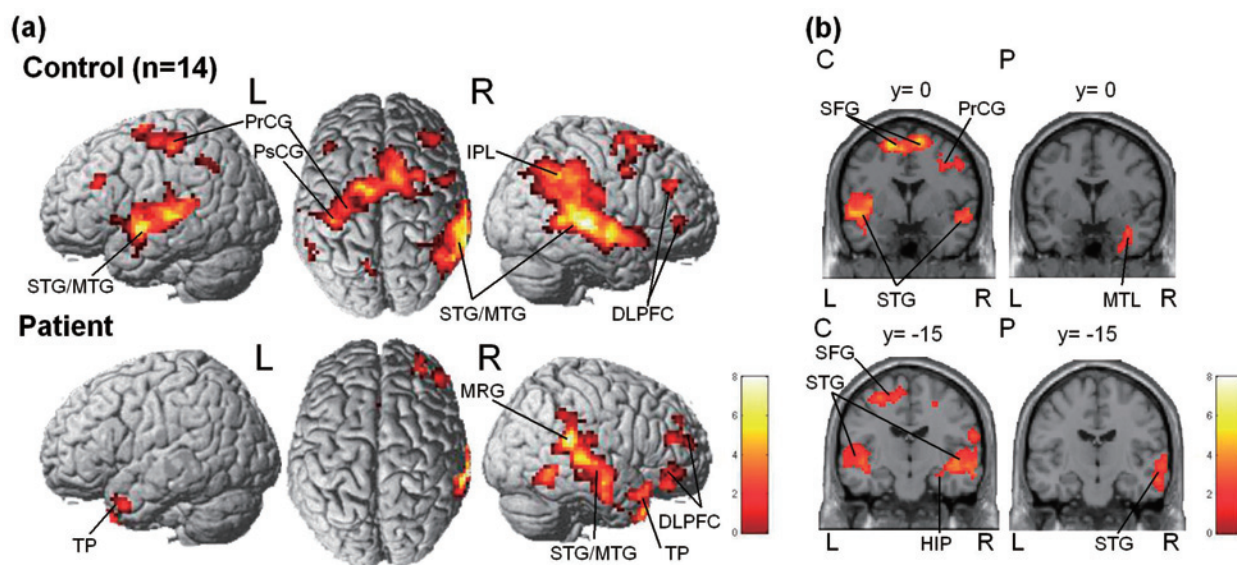


Fig. 1

Functional neuroimaging techniques enable noninvasive measurements of cognitive functions in humans. We used functional neuroimaging to assess cognitive disturbance in a patient with mild cognitive impairment. The patient was a 58-year-old male with a mild memory disturbance, a mini-mental state examination (MMSE) score of 22/30, and a Clinical Dementia Rating Scale of 0.5. On the Wechsler Adult Intelligence Scale (WAIS-iii), intelligence quotient tests indicated total IQ=64, verbal IQ=71, and performance IQ=61. The patient showed mild cortical atrophy on structural magnetic resonance imaging (MRI) (T1-weighted image).

To investigate cerebral function with regard to memory processing, we examined cerebral activation during an auditory working memory task (WMT) with voice materials from the Montreal Affective Voices. Functional magnetic resonance imaging (fMRI) was done while the patient carried out a WMT designed to test memory of emotional sounds. We analyzed cerebral response using a WMT>Rest contrast, which reflects the cerebral network of working memory in auditory emotional processing. The results were compared with the fMRI results of 14 control subjects performing the same tasks. In fMRI under WMT>Rest contrast, the cerebral network associated with emotional working memory activated in the control subjects consisted of the right dorsolateral prefrontal cortex, left precentral gyrus, left postcentral gyrus, bilateral superior temporal gyrus, bilateral middle temporal gyrus, right inferior parietal lobe, and right hippocampus [27, -15, -18] (**Fig. 1 (a), 1 (b)**), whereas the right dorsolateral prefrontal cortex, right superior temporal gyrus, right middle temporal

Correspondence to Michihiko Koeda, Department of Neuropsychiatry, Graduate School of Medicine, Nippon Medical School, 1-1-5 Sendagi, Bunkyo-ku, Tokyo 113-8603, Japan

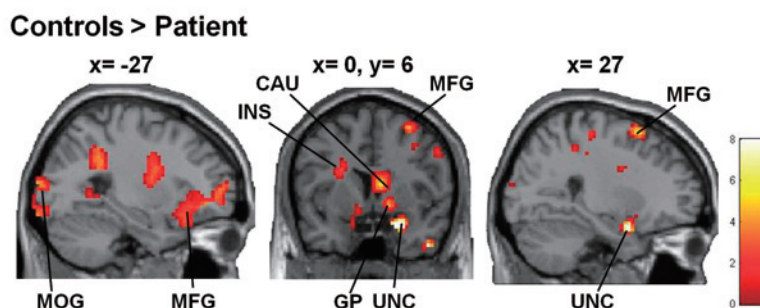


Fig. 2

gyrus, bilateral temporal pole, and right marginal gyrus were activated in the patient (**Fig. 1 (a), 1 (b)**). Compared with the control subjects, the patient's cerebral activation was significantly reduced in the medial frontal gyrus, left insular, right caudate, right globus pallidus, and right uncus [21, 3, -21] under WMT>Rest (**Fig. 2**).

These fMRI findings indicate impairment of the cortical-subcortical network, including the left frontotemporal cortex and right subcortical region, of working memory processing in this patient.

Fig. 1 (a) shows cerebral activation under WMT greater than rest contrast. The upper row shows cerebral activation in the controls (14 subjects: 1-sample t-test, $p < 0.001$, cluster level corrected); the lower row shows cerebral activation in the patient (single subject analysis, $p < 0.001$, cluster level corrected). PrCG: precentral gyrus; PsCG: postcentral gyrus; DLPFC: dorsolateral prefrontal cortex; STG: superior temporal gyrus; MTG: middle temporal gyrus; TP: temporal pole; MRG: marginal gyrus; IPL: inferior parietal lobe.

The color bar shows t-value. L: left, R: right

(b) shows coronal slices of cerebral activation under WMT greater than rest contrast. C: cerebral activation in the control subjects (14 subjects: 1-sample t-test); P: cerebral activation in the patient; SFG: superior frontal gyrus; PrCG: precentral gyrus; STG: superior temporal gyrus; MTL: middle temporal lobe; HIP: hippocampus; Y: y-axis of Talairach coordinates. The color bar shows t-value. L: left, R: right

Fig. 2 shows the areas where the patient's cerebral activation was significantly reduced compared with the control subjects' under WMT>Rest contrast. (2-sample t-test, $p < 0.001$, cluster level corrected). The left slice is the inner side of the left hemisphere (Talairach coordinates $x = -27$). The central slice is the coronal slice around the basal ganglia (Talairach coordinates $y = 6$). The right slice is the inner side of the right hemisphere (Talairach coordinates $x = 27$).

MFG: middle frontal gyrus; CAU: caudate; INS: insular; GP: globus pallidus; UNC: uncus; MOG: middle occipital gyrus

The color bar shows t-value. L: left, R: right