

## An 8-year-old Girl with a Recurrence of Obstructive Sleep Apnea Syndrome Caused by Hypertrophy of Tubal Tonsils 4 Years after Adenotonsillectomy

Makoto Migita<sup>1</sup>, Yoshihiro Gocho<sup>1</sup>, Takahiro Ueda<sup>1</sup>,  
Hideto Saigusa<sup>2</sup> and Yoshitaka Fukunaga<sup>1</sup>

<sup>1</sup>Department of Pediatrics, Graduate School of Medicine, Nippon Medical School

<sup>2</sup>Department of Head & Neck and Sensory Organ Science, Graduate School of Medicine, Nippon Medical School

### Abstract

Obstructive sleep apnea syndrome affects 1% to 2% of children. It is caused mainly by upper airway obstruction and manifests as snoring and sleep disturbance. Adenotonsillectomy can improve quality of life because airway obstruction occurs when both tonsils and adenoids are enlarged. We describe an 8-year-old girl with a recurrence of obstructive sleep apnea syndrome caused by hypertrophy of the tubal tonsils 4 years after adenotonsillectomy. The findings from this case highlight the importance of 1) identifying hypertrophy of the residual adenoid and compensatory hypertrophy of the tubal tonsils in patients with obstructive sleep apnea syndrome after adenotonsillectomy and 2) determining the optimal timing of adenotonsillectomy with respect to both the severity of obstructive sleep apnea and compensatory hypertrophy of other lymphoid tissue of Waldeyer's ring, as growth of such tissues is most active during the first several years of life.

(J Nippon Med Sch 2010; 77: 265–268)

**Key words:** adenotonsillectomy, obstructive sleep apnea syndrome (OSAS)

### Introduction

Obstructive sleep apnea syndrome (OSAS) is defined as intermittent cessation of airflow at both the mouth and nose during sleep. Children with sleep-disordered breathing may have symptoms ranging from simple snoring and upper airway resistance to OSAS with secondary growth impairment, neurocognitive deficits, and, less frequently, cardiovascular sequelae. Temporary

cessation of airflow results in frequent transient decreases in oxygen and increases in carbon dioxide levels, which are associated with nocturnal awakenings<sup>1,2</sup>. Adenotonsillectomy is the established treatment for OSAS caused by upper respiratory airway obstruction, although children with severe OSAS or complicating anatomic or neuromotor disorders often experience incomplete relief of OSAS. We describe a rare case of OSAS recurring 4 years after adenotonsillectomy in an 8-year-old girl.

---

Correspondence to Makoto Migita, MD, PhD, Department of Pediatrics, Nippon Medical School, 1–1–5 Sendagi, Bunkyo-ku, Tokyo 113–8603, Japan

E-mail: mmigita@nms.ac.jp

Journal Website (<http://www.nms.ac.jp/jnms/>)

### Case Report

An 8-year-old girl with mouth breathing, snoring, and apnea while sleeping was referred to our hospital. At the age of 3 years, she had received a diagnosis of OSAS based on the presence of typical clinical symptoms and findings from nasopharyngoscopy and polysomnography.

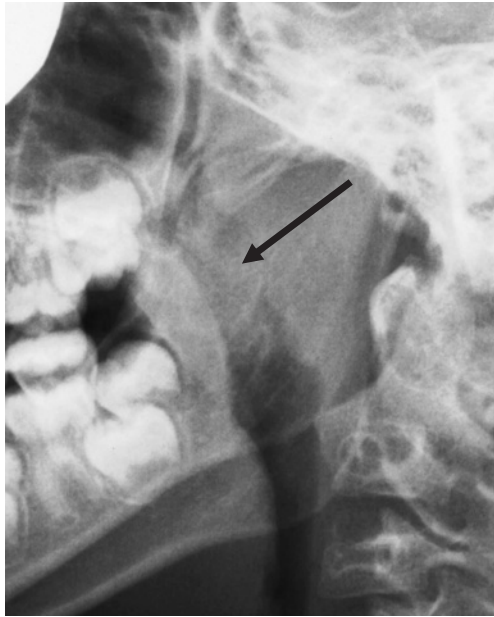

Fig. 1 A lateral neck radiograph shows a markedly enlarged mass obstructing the retropharyngeal airway.

Adenotonsillectomy was performed when she was 4 years of age. Although the clinical symptoms resolved completely after the procedure, mouth breathing, snoring, and sleep apnea recurred at the age of 7 years. There was no evidence of hypertrophy of the palatine tonsils on oral examination; however, a radiograph of the neck from the lateral aspect revealed a markedly enlarged mass obstructing the retropharyngeal airway (**Fig. 1**). Axial magnetic resonance imaging showed enlargement of lymphoid tissues on both sides and attachment at the center (**Fig. 2a**), and a coronal view showed a heart-shaped tissue mass (**Fig. 2b**). Fiberoptic nasopharyngoscopy revealed that tubal tonsils near the Eustachian tube were enlarged bilaterally; there was no evidence of pharyngeal tonsils or palatine tonsils. Although the obstructive apnea/hypopnea index was 18—which is regarded as moderate—polysomnography showed that the average SpO<sub>2</sub> was 97%, the minimum SpO<sub>2</sub> was 71%, and the percentage of sleep time with SpO<sub>2</sub> <90% was 0.6%. These findings suggested that hypertrophy of the tubal tonsils had compensated for the loss of function of the lymphoid tissues removed at adenotonsillectomy and further suggested that the recurrence of OSAS in this patient was caused by hypertrophy of the tubal tonsils. We chose to proceed with close observation of the patient, rather than invasive treatment,

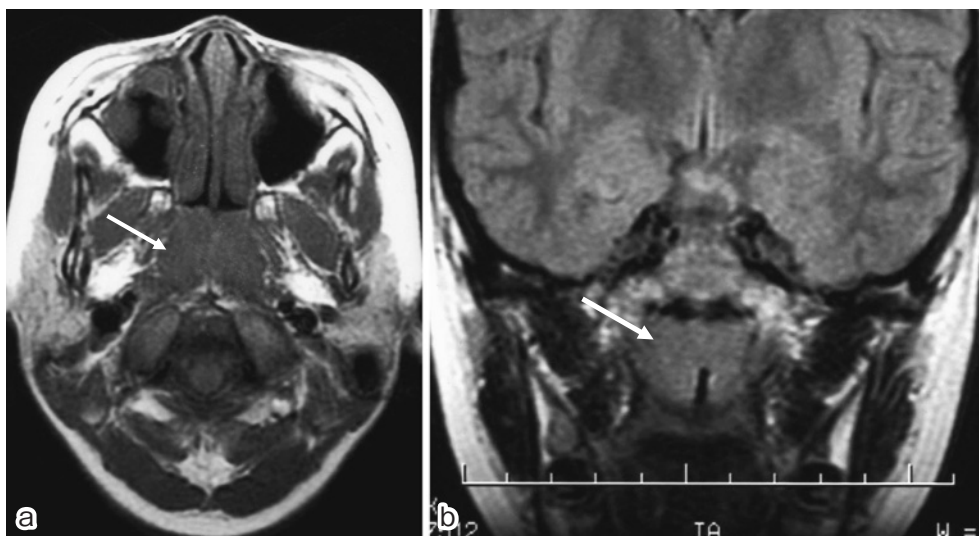


Fig. 2 **a:** An axial magnetic resonance image shows enlarged lymphoid tissue on both sides. **b:** A coronal view shows a heart-shaped arrangement of enlarged lymphoid tissues on both sides attached at the center.

because oxygen saturations during sleep were satisfactory and because surgery for enlarged tubal tonsils is not straightforward. Moreover, lymphoid tissue in Waldeyer's ring naturally decreases in size after the first several years of life. Ultimately, the clinical symptoms of OSAS resolved when the patient was 10 years old.

### Discussion

In pediatric otolaryngology, adenotonsillectomy is an established surgical treatment for chronic or recurrent streptococcal pharyngotonsillitis and OSAS<sup>1,2</sup>. Recently, the indications for pediatric adenotonsillectomy have been changed to include sleep-disordered breathing and to exclude chronic pharyngotonsillitis, because pharyngotonsillitis due to bacterial infection can now be controlled with antibiotics<sup>3</sup>. Adenotonsillectomy results in long-term improvements in quality of life, behavior, and polysomnography findings in children<sup>4,5</sup>. However, airway problems, hemorrhage, and dehydration are known early postoperative complications after adenotonsillectomy. Multiple logistic regression analysis has revealed that the most significant risk factors for these complications are age younger than 3 years and severe OSAS, as demonstrated by clinical symptoms and polysomnography<sup>6,7</sup>. Moreover, children with craniofacial anomalies or neuromotor impairment are also at risk for postoperative respiratory compromise, and adenotonsillectomy is often less effective for treating OSAS in such children<sup>8,9</sup>. Our patient had symptoms of typical and severe OSAS at the age of 3 years, and adenotonsillectomy was performed when she was aged 4 years. However, OSAS recurred 4 years later. It has been reported that children with a history of adenoidectomy have a higher incidence of otitis media with effusion, possibly because of postoperative scarring, hypertrophy of adenoid remnants, or compensatory enlargement of nasopharyngeal lymphoid tissue<sup>10</sup>. The lymphoid tissue that surrounds the oropharyngeal isthmus and the opening of nasopharynx into the oropharynx is called Waldeyer's ring. This structure comprises 1) the pharyngeal tonsil and adenoid superior to the

midline, 2) the tubal tonsils near the Eustachian tube, 3) the palatine tonsils lower down on both sides, and 4) the lingual tonsil, which is inferior to the posterior third of the tongue. Because the tonsils are the first structures to encounter inhaled and ingested microorganisms, they are the first line of defense against exogenous aggressors. During the first several years of life, the lymphoid tissues are very active and grow quickly. Later, they gradually decrease in size. In the present case, hypertrophy of the tubal tonsils after adenotonsillectomy was observed on nasopharyngoscopy and magnetic resonance imaging. Such hypertrophy has been reported as a cause of recurrent symptoms after adenotonsillectomy<sup>11</sup>. When nasal obstruction, obstructive sleep disorder, rhinosinusitis, recurrent otitis media, and otitis media with effusion are seen after adenotonsillectomy, compensatory tubal tonsil hypertrophy should be added to the differential diagnosis. Although intranasal corticosteroids have been reported as a nonsurgical therapeutic alternative for OSAS<sup>12</sup>, we chose to proceed with close observation of the patient because oxygen saturations during sleep were satisfactory; the clinical symptoms of OSAS resolved in our patient at the age of 10 years.

In conclusion, the findings in the present case suggest that, in patients with recurrent OSAS after adenotonsillectomy, it is essential to distinguish tubal tonsil hypertrophy from recurrent or residual adenoid. In addition, adenotonsillectomy should be timed so as to decrease the incidence of recurrent OSAS because the lymphoid tissues of Waldeyer's ring are highly active during the first several years of life, which increases the likelihood of compensatory hypertrophy of these tissues after operative resection.

### References

1. Sterni LM, Tunkel DE: Obstructive sleep apnea in children. In *Otolaryngology—Head & Neck Surgery* (Cummings CW, Flint PW, Harker LA, Haughey BH, et al., eds), 2004; pp 4166–4182, Elsevier Mosby, Philadelphia.
2. Brodsky L, Poje C: Tonsillitis, tonsillectomy and adenoidectomy. In *Head & Neck Surgery—Otolaryngology* (Bailey BJ, Johnson JT, Newlands

- SD, eds), 2006; pp 1183–1198, Lippincott Williams & Wilkins, Philadelphia.
3. Lawrence LWC, Jacobs IN: Diseases of the oral cavity, oropharynx, and nasopharynx. In Ballenger's Otorhinolaryngology Head and Neck Surgery (Snow JB, Ballenger JJ, eds), 2003; pp 1020–1047, BC Decker, Hamilton.
  4. Stradling JR, Thomas G, Warley AR, Williams P, Freeland A: Effect of adenotonsillectomy on nocturnal hypoxaemia, sleep disturbance, and symptoms in snoring children. *Lancet* 1990; 335: 249–253.
  5. Mitchell RB, Kelly J: Long-term changes in behavior after adenotonsillectomy for obstructive sleep apnea syndrome in children. *Otolaryngol Head Neck Surg* 2006; 134: 374–378.
  6. Wiatrak BJ, Myer CM 3rd, Andrews TM: Complications of adenotonsillectomy in children under 3 years of age. *Am J Otolaryngol* 1991; 12: 170–172.
  7. Statham MM, Elluru RG, Buncher R, Kalra M: Adenotonsillectomy for obstructive sleep apnea syndrome in young children: prevalence of pulmonary complications. *Arch Otolaryngol Head Neck Surg* 2006; 132: 476–480.
  8. Seid AB, Martin PJ, Pransky SM, Kearns DB: Surgical therapy of obstructive sleep apnea in children with severe mental insufficiency. *Laryngoscope* 1990; 100: 507–510.
  9. Contencin P, Guilleminault C, Manach Y: Long-term follow-up and mechanisms of obstructive sleep apnea (OSA) and related syndromes through infancy and childhood. *Int J Pediatr Otorhinolaryngol* 2003; 67: 119–123.
  10. Dawes JDK: The aetiology and sequelae of exudative otitis media. *J Laryngol Otol* 1970; 84: 563–610.
  11. Emerick KS: Tubal tonsil hypertrophy: a cause of recurrent symptoms after adenoidectomy. *Arch Otolaryngol Head Neck Surg* 2006; 132: 153–156.
  12. Gozal KL, Gozal G: Intranasal budesonide treatment for children with mild obstructive sleep apnea syndrome. *Pediatrics* 2008; 122: 149–155.

(Received, April 21, 2010)

(Accepted, July 26, 2010)