

Clinical Applications of Basic Research that Shows Reducing Skin Tension Could Prevent and Treat Abnormal Scarring: The Importance of Fascial/Subcutaneous Tensile Reduction Sutures and Flap Surgery for Keloid and Hypertrophic Scar Reconstruction

Rei Ogawa, Satoshi Akaishi, Chenyu Huang, Teruyuki Dohi,
Masayo Aoki, Yasutaka Omori, Sachiko Koike, Kyoko Kobe,
Masataka Akimoto and Hiko Hyakusoku

Department of Plastic, Reconstructive and Regenerative Surgery, Graduate School of Medicine, Nippon Medical School

Abstract

We use evidence-based algorithms to treat abnormal scarring, including keloids and hypertrophic scars (HSs). This involves a multimodal approach that employs traditional methods such as surgical removal, postoperative radiotherapy, corticosteroid injection, laser, and silicone gel sheets. As a result, the rate of abnormal scarring recurrence has decreased dramatically over the past 10 years. However, several problems remain to be solved. First, despite the optimization of a radiotherapy protocol, over 10% of cases who are treated with surgery and postoperative radiotherapy still recur in our facility. Second, the treatment options for cases with huge keloids are very limited. To address these problems, we performed basic research on the mechanisms that drive the formation of keloids and HSs. Extrapolation of these research observations to the clinic has led to the development of two treatment strategies that have reduced the rate of abnormal scar recurrence further and provided a means to remove large scars.

Our finite element analysis of the mechanical force distribution around keloids revealed high skin tension at the keloid edges and lower tension in the keloid center. Moreover, when a sophisticated servo-controlled device was used to stretch wounded murine dorsal skin, it was observed that the stretched samples exhibited upregulated epidermal proliferation and angiogenesis, which are also observed in keloids and HSs. Real-time RT-PCR also revealed that growth factors and neuropeptides are more strongly expressed in cyclically stretched skin than in statically stretched skin. These findings support the well-established notion that mechanical forces on the skin strongly influence the cellular behavior that leads to scarring.

These observations led us to focus on the importance of reducing skin tension when keloids/HSs are surgically removed to prevent their recurrence. Clinical trials revealed that subcutaneous/fascial tensile reduction sutures, which apply minimal tension on the dermis, are more effective in reducing recurrence than the three-layered sutures used by plastic surgeons. Moreover, we have found that by using skin flaps (e.g., perforator flaps and propeller flaps), which release tension on the wound, in combination with postoperative radiotherapy, huge keloids can be successfully treated.

(J Nippon Med Sch 2011; 78: 68–76)

Key words: keloid, hypertrophic scar, tension, mechanical force, mechanotransduction

Correspondence to Rei Ogawa, MD, PhD, Department of Plastic, Reconstructive and Aesthetic Surgery, Nippon Medical School, 1-1-5 Sendagi, Bunkyo-ku, Tokyo 113-8603, Japan

E-mail: r.ogawa@nms.ac.jp

Journal Website (<http://www.nms.ac.jp/jnms/>)

Introduction

Based on evidence-based algorithms, we have treated abnormal scars, including keloids and hypertrophic scars (HSs), with a multimodal approach that employs traditional methods, such as surgical removal, postoperative radiotherapy, corticosteroid injection, laser, and silicone gel sheets¹. As a result, the rate of abnormal scar recurrence has decreased dramatically over the past 10 years^{2,3}. However, several problems remain to be solved. First, over 10% of cases who are treated with surgery and postoperative radiotherapy still recur, despite the optimization of a radiotherapy protocol³. Second, the treatment options for huge keloids are very limited. To tackle these issues, we have developed new treatment strategies on the basis of our basic research observations⁴⁻⁸.

Current Treatment Algorithms

An extensive review of the literature regarding keloid and HS treatments¹ led us to recommend that the HS treatment method of choice depends on whether scar contractures (especially joint contractures) are present. If scar contractures are present, surgical approaches that release contractures should be performed. These include z-plasties, skin grafts, and skin flaps. With regard to keloids, the treatment method of choice depends on whether the keloids are small/single or large/multiple¹. Small/single keloids can be treated radically by surgery plus adjuvant therapy (which includes radiation or corticosteroid injections) or by nonsurgical monotherapy (which includes corticosteroid injections, cryotherapy, laser, and anti-tumor/immunosuppressive agents such as 5-fluorouracil). Large/multiple keloids are difficult to treat radically and are currently only treatable by multimodal therapies that aim to relieve symptoms. Regardless of the treatment method employed, a long-term follow-up is recommended. Moreover, conservative therapies (which include gel sheeting, taping fixation, compression therapy, external/internal agents, and make-up (camouflage) therapy)

should be administered on a case-by-case basis.

Basic Research Observations

HSs do not grow beyond the boundaries of the original wound, and thus only grow vertically. In contrast, keloids grow and spread both vertically and horizontally. Indeed, they are similar in many respects to slowly growing malignant tumors. The direction of their horizontal growth results in characteristic shapes that depend on their location. For example, keloids on the anterior chest grow in a “crab’s claw”-like pattern (**Fig. 1A**), whereas shoulder keloids grow in a “butterfly” shape (**Fig. 1B**) or “dumbbell” shape (**Fig. 1C**). Our basic research has led us to suggest that these patterns reflect the predominant directions of skin tension at these sites. In particular, our finite element analysis of the mechanical force distribution around the keloids revealed high skin tension at the keloid edges and lower tension at the keloid centers⁴ (**Fig. 2**). Moreover, the skin stiffness at the keloid circumference correlated directly with the degree of skin tension. These observations explain why keloids generally stop growing in their central regions and why keloid expansion occurs in the predominant direction(s) of skin pulling. They also strongly support the notion that the skin tension is closely associated with the pattern and degree of keloid growth. The growth patterns of HSs and normal scars may differ from the growth patterns of keloids because of differences in their responsiveness to skin tension⁴.

A statistical study of 1,034 anatomic regions in Japanese patients revealed that keloids tend to occur at specific sites, including the anterior chest, shoulder, scapular, and suprapubic regions⁵ (**Fig. 3**). All of these sites are constantly or frequently subjected to mechanical forces, including skin stretching due to daily body movements. In contrast, HSs can occur anywhere in the body, especially when a wound is long, wide, and located on a frequently moved joint. However, big scars rarely occur on the scalp or the anterior lower leg, even in patients with keloids or HSs that cover their entire body⁵. In both of these sites, the bones lie directly

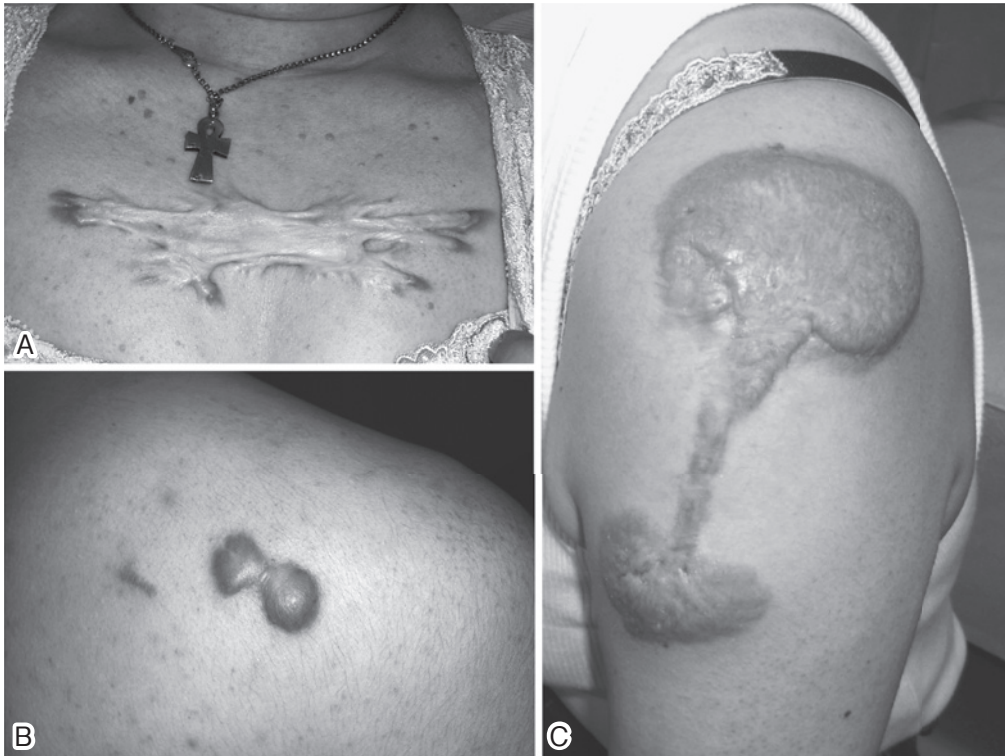

Fig. 1 A: A “crab’s claw” shaped keloid

Anterior chest keloids sometimes adopt a “crab’s claw” shape because small acne keloids that eventually combine with each other then gradually expand horizontally.

B: A “butterfly” shaped keloid

Keloids on the shoulder always take a “butterfly” shape. We believe that this reflects the predominant mechanical forces on the skin of the shoulder.

C: A “dumbbell” shaped keloid

Keloids on the upper arm always take a “dumbbell” shape. Interestingly, these keloids do not extend towards the neck.

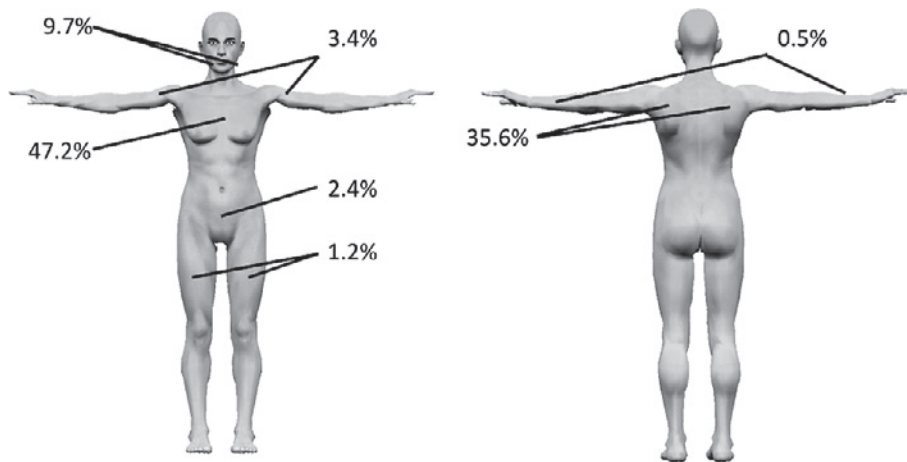


Fig. 3 Statistical analysis of the frequencies with which 1,034 anatomic regions in Japanese patients develop keloids

Heavy scars occur rarely on the scalp or the anterior lower leg. This site-specificity of abnormal scar development suggests that mechanical forces not only promote keloid/HS growth, they may also be a primary trigger for their generation.

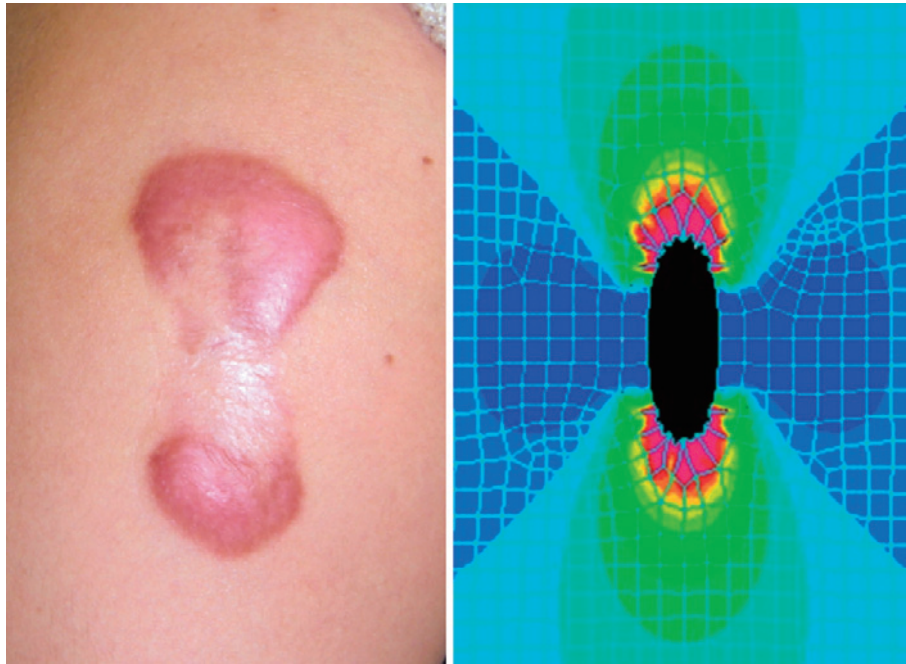


Fig. 2 The highly inflammatory regions of a keloid (left) are surrounded by marked stretching tension, as indicated by computer modeling (right)
 Computer simulation (finite element analysis) of a stretched keloid revealed that the edges of the keloid are associated with a high degree of tension. The areas of high tension (red color) are highly consistent with the clinical appearance of the keloid.

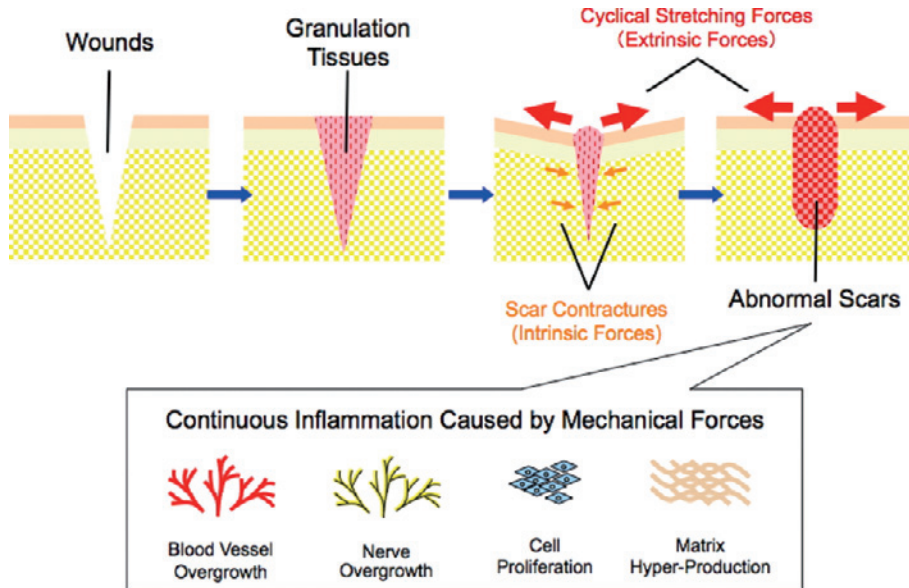


Fig. 4 Schematic depiction of the mechanisms that generate abnormal scars
 We suspect that the mechanisms that promote abnormal scarring involve prolonged inflammation that is induced by mechanical forces on the skin.

under the skin, which means the skin at these sites is rarely subjected to mechanical forces. This site-specificity of keloid/HS development suggests that mechanical forces may not only promote keloid/HS

growth, they may also be a primary trigger of their generation. While strong and prolonged inflammation is another trigger for the generation of keloids/HSs⁶, we believe that mechanical forces play

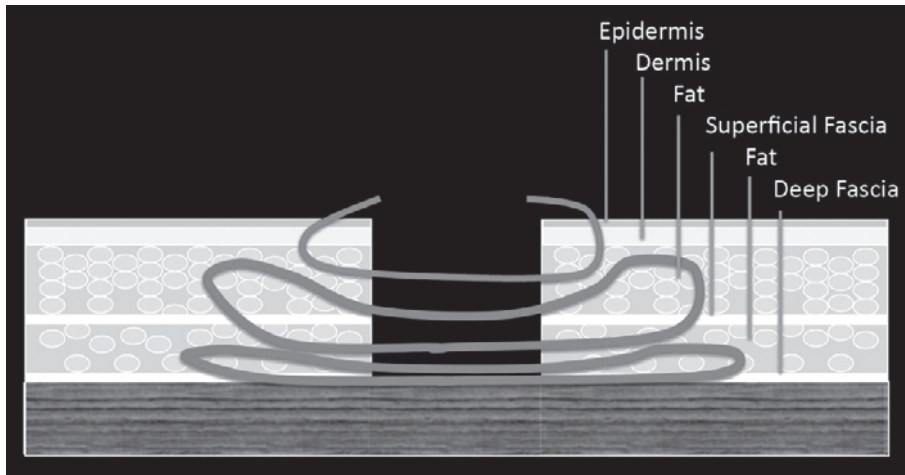


Fig. 5 The standard suture used in general surgery

Generally, the epidermis and dermis are sutured together after a subcutaneous suture has been placed. Such sutures increase the risk of ischemia in the wound, which elevates the risk of surgical site infection and HSs.

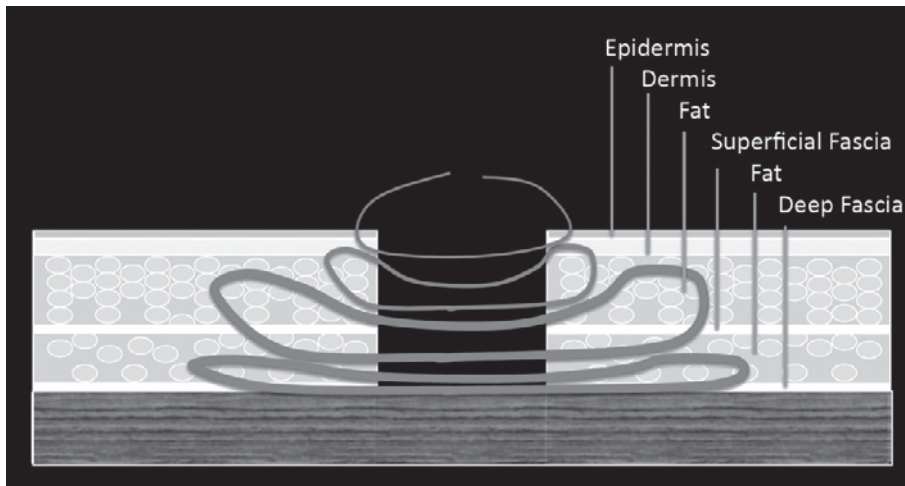


Fig. 6 The three-layered suture used in plastic surgery

After subcutaneous sutures are placed, dermal sutures and superficial sutures are placed separately. While this method decreases the risk of SSI and HSs, the degree of skin tension alleviation that it achieves is not sufficient to prevent the development of intractable HSs and severe keloids.

a more significant role in this process^{7,8} (**Fig. 4**). Supporting this are studies that used a sophisticated servo-controlled device to stretch wounded murine dorsal skin^{9,10}. These studies showed that the stretched samples exhibited upregulated epidermal proliferation and angiogenesis, which are also features of keloids and HSs. Moreover, real-time RT-PCR analyses revealed that cyclically stretched skin expresses growth factors and neuropeptides more strongly than statically stretched skin^{9,10}. In addition, a study with a HS mouse model where healing scars

were exposed to mechanical force loading showed that scars subjected to tension exhibit less apoptosis, and that inflammatory cells and mechanical forces promote fibrosis¹¹. These findings support the well-established notion that mechanical forces strongly modulate the cellular behavior that leads to abnormal scarring^{7,8,12}.

Recent Clinical Trials Leading to Better Results

The research observations described above

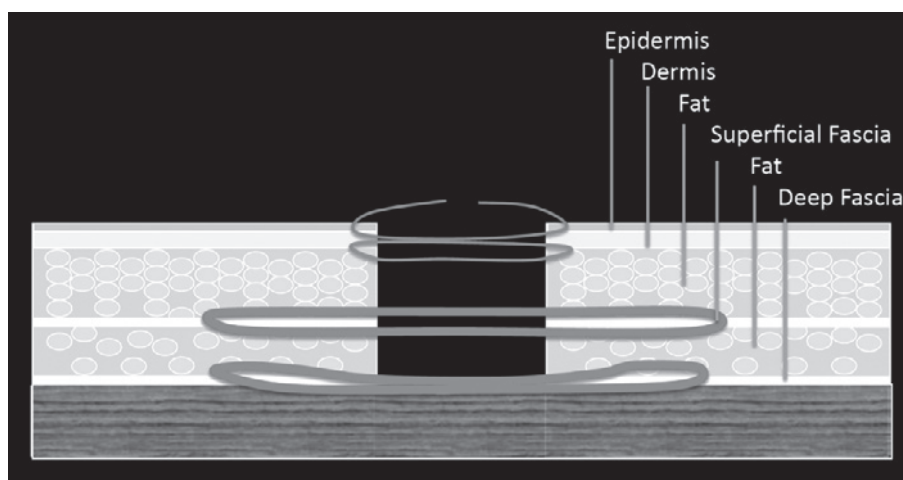


Fig. 7 Subcutaneous/fascial tensile reduction sutures

Since the sutures are placed on the layer of deep fascia and superficial fascia, fewer or even no dermal sutures have to be used. Superficial sutures are then placed. This method can reduce the risk of abnormal heavy scarring.

suggested to us that reducing mechanical forces on healing skin would help to prevent the development and recurrence of keloids/HSs¹³⁻¹⁵. On the basis of this, we have started to use a suture that places little tension on the wound dermis and flaps to treat large keloids, as follows.

Fascial/Subcutaneous Tensile Reduction Sutures

Since keloids and HSs arise from the dermis, we speculated that eliminating mechanical forces on the dermis might reduce the risk of keloid/HS formation after surgery. In general surgery (e.g., cardiac surgery, abdominal surgery and gynecological surgery), the epidermis and dermis tend to be sutured together after subcutaneous sutures have been placed (**Fig. 5**). In contrast, three-layered sutures (**Fig. 6**) consisting of separate subcutaneous/dermal/superficial sutures are used in plastic surgery: these sutures are associated with a clear decrease in the risk of both surgical site infections (SSIs) and HSs, as follows.

SSIs occur at the site of surgery within 30 days of an operation or within 1 year of an operation if a foreign body is implanted as part of the surgery. While most SSIs (about 70%) are superficial infections that only involve the skin, the other infections are more serious and can involve tissues under the skin, organs, or implanted material. It has been suggested that wound ischemia caused by

suture technique may be one of the mechanisms that generate SSI¹⁶. This ischemia is improved by using three-layered sutures.

HSs occur frequently on particular sites, including the anterior chest wall after cardiac surgery, the abdomen after abdominal surgery, the suprapubic region after gynecologic surgery, and the shoulder/thigh after orthopedic surgery. These sites all have in common the fact that they are frequently subjected to cyclical skin stretching caused by the natural daily movements of the body. Since three-layered sutures reduce tension to some degree, it may be possible to prevent mild HSs from developing by using this technique.

However, further modifications of suture techniques are needed to prevent the development of severe HSs and keloids because even three-layered sutures place tension on the dermis. Consequently, we have started to use subcutaneous/fascial tensile reduction sutures¹³ (**Fig. 7**), where the tension is placed on the layer of deep fascia and superficial fascia. This means that the use of dermal sutures is minimized; indeed, dermal sutures can be avoided altogether if the wound edges can be joined naturally under very small tension. We prefer 2-0 polydioxanone sutures (PDSII[®]; Ethicon Japan, Tokyo) or 3-0 PDSII[®] for subcutaneous/fascial sutures, 4-0 or 5-0 PDSII[®] for dermal sutures (if they are necessary), and 6-0 or 7-0 polypropylene or nylon

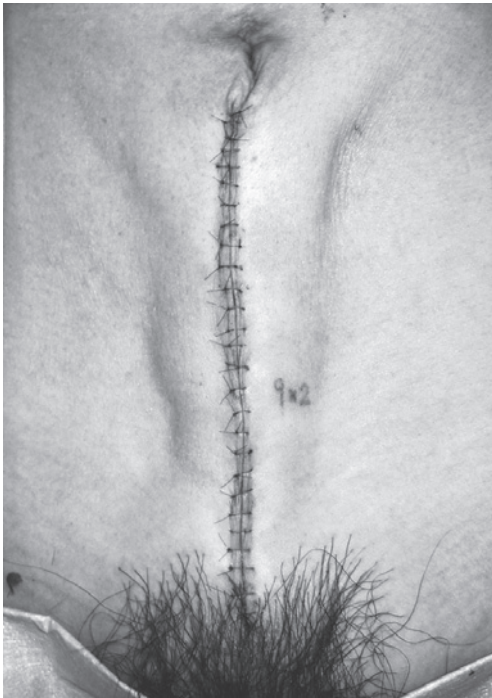


Fig. 8 Appearance after the use of subcutaneous/fascial sutures
The wound edges are elevated smoothly and the tension on the dermis is minimal.

sutures (Proline® or Ethilon®: Ethicon Japan, Tokyo) for superficial sutures. The consequence of such suturing is that the wound edges are elevated smoothly (Fig. 8) with minimal tension on the dermis that appears to prevent the development of large scars.

Sometimes, after suturing, there are small nodules under the skin that can be sensed when the wound surface is touched. These are likely to reflect surgical damage to the dermis. Since we have noticed that keloids/HSs tend to recur from these nodules (indeed, it seems that keloid recurrence usually starts from the suture marks rather than the sutured surfaces), we make sure that we do not nick the dermal layer during surgery.

Flap Surgery for Keloid Reconstruction

Keloids can be treated surgically in two ways: they can either be radically resected or undergo mass reduction¹. For both types of approaches, skin grafting or flap transfer¹⁴ with postoperative radiotherapy may be required if the keloid is difficult to excise completely and suture directly.

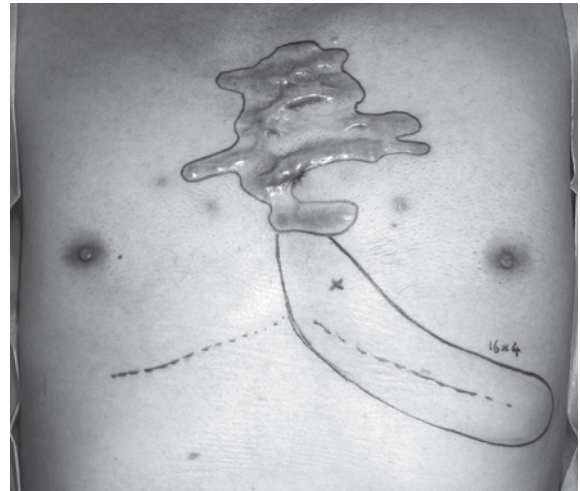


Fig. 9 Preoperative view of keloid reconstruction using a perforator pedicled propeller flap
An internal mammary artery perforator was detected under the keloids by Doppler ultrasound.

However, two problems are associated with skin grafting, namely keloid recurrence at the margins of the skin graft, and depigmentation of the center of the skin graft. Our computer simulation studies have suggested that the tension on the edge of the keloid will be reduced if there is soft tissue under the keloid (data not shown). Therefore, to reduce the tension on the flap, we are currently using skin flaps with fat under the skin to reconstruct keloids. Our preliminary study on 20 patients with huge keloids who were treated by such flaps and postoperative radiotherapy in our facility has shown that all cases had uneventful postoperative courses and keloid recurrence was not observed (Fig. 9–11). A longer follow-up period is needed to confirm these outcomes, but at present they are encouraging.

In the past, keloid reconstruction by using flaps was discouraged because it was thought that the donor site could develop keloids. However, the development of keloids on the donor site can be prevented by using subcutaneous/fascial tensile reduction sutures and post-operative radiotherapy. Thus, we believe flap surgery is suitable as a treatment of choice when dealing with severe keloids. In particular, since perforator flaps (especially the perforator pedicled propeller flap¹⁷) are associated with little donor site morbidity, we often use these sophisticated flaps to reconstruct

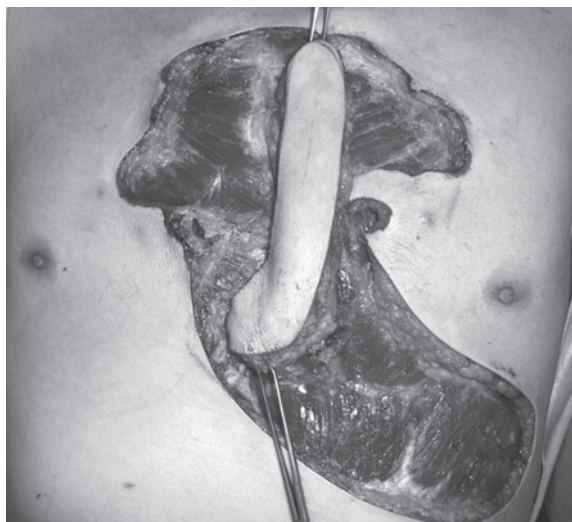


Fig. 10 Intraoperative view of keloid reconstruction using a perforator pedicled propeller flap. The skin island of the flap was elevated with a perforator pedicle and rotated so that it covered the recipient site. After surgery, radiation therapy was performed with a 20 Gy/4 fractions/4 days protocol.

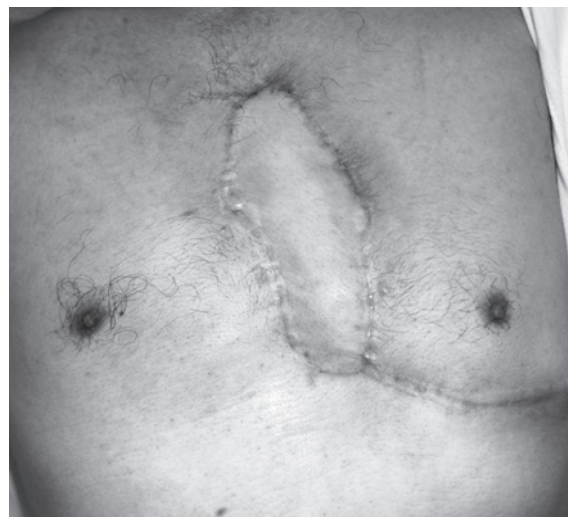

Fig. 11 The postoperative view 18 months after keloid reconstruction using a perforator pedicled propeller flap. Keloids did not recur on either the donor or recipient sites.

keloids.

Future Directions of Basic Research on Abnormal Scar Prevention and Treatment

Basic research on mechanobiology has revealed that reducing skin tension may prevent the development and recurrence of abnormal scars¹⁸. While wound healing and scarring involve some of the most complicated biological reactions in our body¹⁹, it is important to view these phenomena more simply. Our research suggests that mechanical force and hypersensitivity to mechanical force are major causes of abnormal scarring, and that cyclically applied mechanical forces may induce continuous skin inflammation and mechanosignaling pathway activation^{7,8}. Consequently, further research into mechanosignaling pathways may aid the development of effective therapies for abnormal scars. Moreover, a recent study on single nucleotide polymorphisms²⁰ has suggested that the hypersensitivity to mechanical force that may drive abnormal scarring reflects a genetic predisposition. Since both HSs and keloids can be hereditary, the relationship between these single nucleotide

polymorphisms and abnormal scarring should be studied.

This paper was presented at the 78th annual conference of the Nippon Medical School Society as a scholarship award lecture.

References

1. Ogawa R: The most current algorithms for the treatment and prevention of hypertrophic scars and keloids. *Plast Reconstr Surg* 2010; 125: 557-568.
2. Ogawa R, Mitsuhashi K, Hyakusoku H, Miyashita T: Postoperative electron-beam irradiation therapy for keloids and hypertrophic scars: retrospective study of 147 cases followed for more than 18 months. *Plast Reconstr Surg* 2003; 111: 547-553; discussion 554-555.
3. Ogawa R, Miyashita T, Hyakusoku H, Akaishi S, Kuribayashi S, Tateno A: Postoperative radiation protocol for keloids and hypertrophic scars: statistical analysis of 370 sites followed for over 18 months. *Ann Plast Surg* 2007; 59: 688-691.
4. Akaishi S, Akimoto M, Ogawa R, Hyakusoku H: The relationship between keloid growth pattern and stretching tension: visual analysis using the finite element method. *Ann Plast Surg* 2008; 60: 445-451.
5. Ohmori Y, Akaishi S, Ogawa R, Hyakusoku H: Analysis of regions where keloids tend to occur. *Scar Management* 2010; 4: 112-115.
6. Akaishi S, Ogawa R, Hyakusoku H: Visual and pathologic analyses of keloid growth patterns. *Ann Plast Surg* 2010; 64: 80-82.
7. Akaishi S, Ogawa R, Hyakusoku H: Keloid and hypertrophic scar: neurogenic inflammation

- hypotheses. *Med Hypotheses* 2008; 71: 32–38. Epub 2008 Apr 11.
8. Ogawa R: Keloid and hypertrophic scarring may result from a mechanoreceptor or mechanosensitive nociceptor disorder. *Med Hypotheses* 2008; 71: 493–500.
 9. Chin MS, Ogawa R, Lancerotto L, et al: In vivo acceleration of skin growth using a servo-controlled stretching device. *Tissue Eng Part C Methods* 2010; 16: 397–405.
 10. Chin MS, Lancerotto L, Helm DL, et al: Analysis of neuropeptides in stretched skin. *Plast Reconstr Surg* 2009; 124: 102–113.
 11. Aarabi S, Bhatt KA, Shi Y, et al: Mechanical load initiates hypertrophic scar formation through decreased cellular apoptosis. *FASEB J* 2007; 21: 3250–3261.
 12. Yagmur C, Akaishi S, Ogawa R, Guneren E: Mechanical receptor-related mechanisms in scar management: a review and hypothesis. *Plast Reconstr Surg* 2010; 126: 426–434.
 13. Akaishi S, Ogawa R, Ohmori Y, Hyakusoku H: Novel Suture Technique after Keloid Excision—Fascial Suture Technique—. *Scar Management* 2010; 4: 95–99.
 14. Aoki M, Akaishi S, Ono S, et al: Usefulness and problems of flap surgery for keloids. *Scar Management* 2010; 4: 108–111.
 15. Dohi T, Akaishi S, Ohmori Y, Ogawa R, Hyakusoku H: Core excision methods for keloids. *Scar Management* 2010; 4: 75–78.
 16. Hranjec T, Swenson BR, Sawyer RG: Surgical site infection prevention: how we do it. *Surg Infect (Larchmt)* 2010; 11: 289–294.
 17. Hyakusoku H, Ogawa R, Oki K, Ishii N: The perforator pedicled propeller (PPP) flap method: report of two cases. *J Nippon Med Sch* 2007; 74: 367–371.
 18. Ogawa R, Orgill DP: Mechanobiology of Cutaneous Wound Healing and Scarring. In “Bioengineering Research of Chronic Wounds” (Amit G, ed), 2010; pp 31–42, Springer, Berlin Heidelberg.
 19. Gurtner GC, Werner S, Barrandon Y, Longaker MT: Wound repair and regeneration. *Nature* 2008; 453: 314–321.
 20. Nakashima M, Chung S, Takahashi A, et al: A genome-wide association study identifies four susceptibility loci for keloid in the Japanese population. *Nat Genet* 2010; 42: 768–771.

(Received, January 4, 2011)

(Accepted, February 10, 2011)