

## Ritodrine-induced Pustular Eruptions Distinctly Resembling Impetigo Herpetiformis

Yoshimitsu Kuwabara<sup>1,2</sup>, Atsuki Sato<sup>1,2</sup>, Hiroko Abe<sup>1,2</sup>,  
Sumino Abe<sup>3</sup>, Naoki Kawai<sup>1</sup> and Toshiyuki Takeshita<sup>2</sup>

<sup>1</sup>Department of Obstetrics and Gynecology, Tokyo Rinkai Hospital, Tokyo

<sup>2</sup>Division of Reproductive Medicine, Perinatology and Gynecologic Oncology,  
Graduate School of Medicine, Nippon Medical School

<sup>3</sup>Department of Dermatology, Tokyo Rinkai Hospital, Tokyo

### Abstract

A 27-year-old nulligravida woman without a history of dermatosis was hospitalized for threatened preterm labor at 29 weeks' gestation; therefore, continuous infusion of ritodrine hydrochloride was started. At 31 weeks' gestation, erythematous plaques appeared and spread over the body surface; therefore, a topical steroid preparation was applied. At 32 weeks' gestation, the eruptions developed into irregular annular areas of erythema with multiple pustules accompanied by severe itching, and oral prednisolone treatment was started. Bacterial cultures of the pustules were negative, and a crural cutaneous biopsy revealed Kogoj's spongiform pustules. Based on the clinicopathological findings, the most likely diagnosis was impetigo herpetiformis, which causes cutaneous symptoms closely resembling pustular psoriasis in pregnant females without a history of psoriasis. To rule out ritodrine-induced pustular eruptions, the ritodrine infusion was stopped and treatment with an MgSO<sub>4</sub> preparation was started at 33 weeks' 3 days' gestation; however, the uterine contractions could not be suppressed. Because of the patient's highly edematous, severely painful feet, a cesarean section was performed the same day. Within several days of delivery, the eruptions began to resolve, and no recurrence was observed after treatment with oral prednisolone was stopped 31 days after delivery. On the basis of a positive patch test for ritodrine, we diagnosed pustular drug eruptions caused by ritodrine hydrochloride. Although ritodrine-induced pathognomonic cutaneous eruptions are rare, we would like to emphasize that ritodrine can cause drug-induced pustular eruptions distinctly resembling life-threatening impetigo herpetiformis.

(J Nippon Med Sch 2011; 78: 329–333)

**Key words:** pustular eruptions, ritodrine hydrochloride, impetigo herpetiformis

## Introduction

Ritodrine hydrochloride has been used to treat preterm uterine contractions for more than 15 years. The major side effects of ritodrine are palpitations, tachycardia, tremors, nausea, hypopotassemia, transient hypoglycemia, vasculitis vascular pain, and flushing<sup>1,2</sup>. In some cases, more serious side effects occur, including cardiac arrhythmia, myocardial ischemia, pulmonary liver dysfunction, and neutropenia. Ritodrine administration also induces benign rashes in 1% to 3% of treated patients<sup>3</sup>; however, few cases of pathognomonic cutaneous eruptions, including maculopapular rash<sup>2</sup>, cutaneous vasculitis<sup>4</sup>, and erythema multiform-like lesions<sup>5</sup>, have been reported. We report a case of ritodrine-induced pustular eruptions in a pregnant woman without a history of skin eruptions, which distinctly resembled life-threatening impetigo herpetiformis (IH).

## Case

A 27-year-old nulligravida woman was hospitalized for threatened preterm labor at 29 weeks' gestation. The personal and family histories were negative for skin diseases, including psoriasis. Transvaginal ultrasonography revealed a shortened uterine cervix, 2.4 cm in length, and contractions were occurring every 5 minutes. Bacterial culture of the vaginal discharge collected at this time demonstrated normal *Lactobacillus* flora. She was given intravenous ritodrine hydrochloride (Utemerin; Kissei Pharmaceutical Co., Ltd., Matsumoto, Japan) at 50 µg/min in a 5% glucose solution. The dosage was gradually increased to 125 µg/minute over 15 days, and the contractions abated. At 31 weeks' gestation (17 days after admission), the patient complained of pruritus and a rash around the forearm site of intravenous infusion. The infusion site was changed, and the rash resolved. The next day, erythematous plaques appeared on the face, arms, and abdomen, and a topical steroid preparation was applied. At 32 weeks' gestation (25 days after admission), numerous tiny nonfollicular

pustules appeared on the erythematous plaques (**Fig. 1**). The laboratory findings were normal, including those for the white blood cell count, hematocrit, platelet count, electrolyte determinations, liver function test, and C-reactive protein value. Bacterial pustule cultures collected at this time were negative. An oral steroid preparation was started at a dosage of 10 mg/day; however, the erythema worsened and spread to the back, chest, abdomen, and extremities within several days. The dosage of the oral steroid preparation was increased to 20 mg/day at 33 weeks' gestation (29 days after admission).

A crural cutaneous biopsy revealed subcorneal neutrophilic pustules forming spongiform structures, a finding consistent with Kogoj's spongiform pustules (**Fig. 2**). Based on the clinicopathological findings, the most likely diagnosis was IH, a type of eruption closely resembling pustular psoriasis that develops in pregnancy. There was also a concern that the administered ritodrine might have caused drug-induced pustular eruptions. To rule out ritodrine-induced pustular eruptions, we discontinued the administration of ritodrine and started treatment with MgSO<sub>4</sub> at 1 g/hour at 33 weeks' 3 days' gestation (32 days after admission). The frequency of uterine contractions gradually increased, and after several hours the dosage of MgSO<sub>4</sub> was increased to 2 g/hour. A fever developed (maximum temperature: 37.5°C), as did marked inflammatory bilateral edema of the lower thighs accompanied by severe pain.

Laboratory examinations showed leukocytosis ( $15,950 \times 10^6/L$ ) with significant neutrophilia (90%), an increased level of C-reactive protein (7.18 mg/dL), and hypoalbuminemia (3.0 g/dL). The other laboratory findings and systemic conditions were unremarkable. The body surface was covered by areas of erythema and multiple pustules, some of which had formed an irregular annular configuration accompanied by repeated partial regression and regeneration (**Fig. 3**). Some of the pustules on the thighs and back had coalesced into larger pus-filled bullae.

Because of the difficulty of controlling the preterm uterine contractions and the acute development of

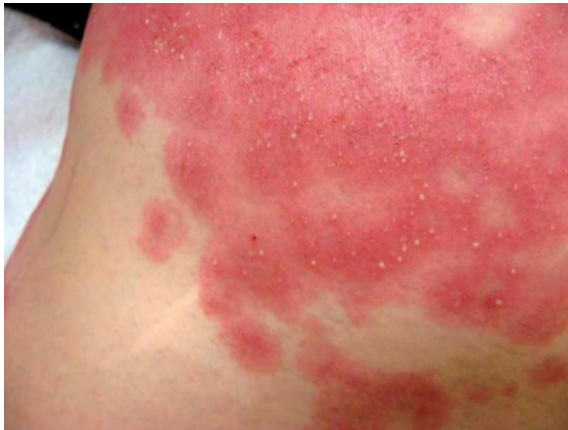

Fig. 1 Numerous tiny nonfollicular pustules appeared on the erythematous plaques.

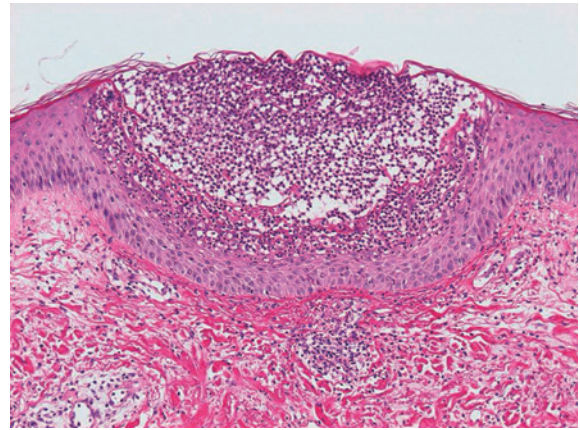


Fig. 2 Histologic examination revealed subcorneal neutrophilic pustules forming spongiform structures, consistent with Kogoj's spongiform pustules.

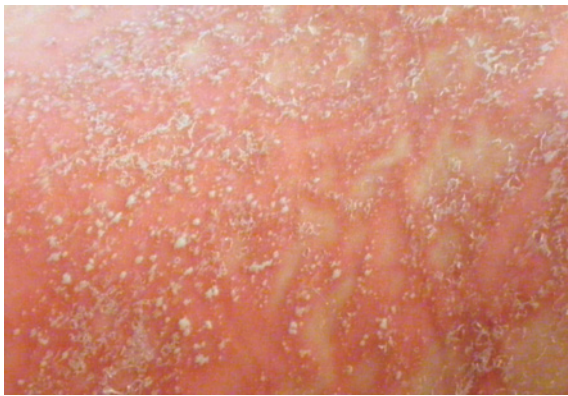

Fig. 3 The patient's body was covered with pustular eruptions, partly forming irregular annular configurations.

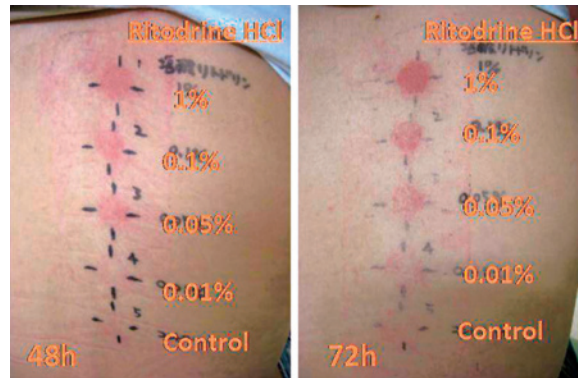

Fig. 4 Four concentrations of ritodrine solution (1%, 0.1%, 0.05%, and 0.01%) and distilled water as a control were applied to the skin of the back and checked after 48 and 72 hours. The results were clearly positive at every concentration of the solution at both 48 and 72 hours after application.

eruptions accompanied by systemic inflammation, we finally decided to resolve the pregnancy. Owing to the severe edema and pain of the thighs, emergency cesarean section was chosen as the delivery mode. A 1,945-g male infant was delivered and transported to the local neonatal intensive care unit because of low birth weight and transient tachypnea. Within several days of delivery, the eruptions began to resolve. The administration of the oral steroid preparation was tapered in a stepwise fashion and finally stopped 31 days after delivery. Forty-one days after delivery, no pustular eruption was observed, although areas of irregular annular erythema remained on parts of the back and extremities.

A patch test was performed to confirm whether

the pustular eruptions had been caused by ritodrine. Four concentrations of ritodrine solution (1%, 0.1%, 0.05%, and 0.01%) and distilled water as a control were applied to the skin of the back and checked after 48 and 72 hours. No other drugs other than ritodrine were tested, because ritodrine was the only drug that had been administered before the pustular eruptions appeared. The results were clearly positive at every concentration of the solution at both 48 and 72 hours after application (Fig. 4). We also patch-tested 10 women volunteers without a history of ritodrine use. No positive reactions to ritodrine were observed in this group, supporting

the conclusion that the patient's reaction to ritodrine was allergic rather than toxic. On the basis on these results, pustular eruption caused by ritodrine hydrochloride was diagnosed.

### Discussion

Ritodrine hydrochloride is a beta-adrenergic stimulant with predominant effects on the beta 2 receptor used to avoid abortion and preterm delivery. Several cases of ritodrine-induced pathognomonic cutaneous eruptions have been reported<sup>2,4,5</sup>; however, only a single case of pustular eruptions related to ritodrine has been reported, in a pregnant woman with psoriasis<sup>6</sup>. It should be noted that all reported cases, including the present case, exhibited skin eruptions more than several weeks after the start of drug treatment.

In the present case, the clinicopathological findings fulfilled the diagnostic criteria of pustular psoriasis<sup>7</sup>; therefore, we initially suspected IH, which has cutaneous symptoms closely resembling pustular psoriasis in pregnant women without a history of psoriasis. IH is a rare dermatosis of pregnancy that can present in the third trimester with widespread cutaneous pustulosis and severe systemic features<sup>8</sup>. Early recognition is important because this condition is life threatening, and misdiagnosis and inappropriate treatment may compromise maternal and fetal well-being. IH is associated with increased fetal morbidity and with complications, such as stillbirth, placental insufficiency, fetal growth restriction, preterm labor, and neonatal death<sup>8-12</sup>. Because few drugs can be used during pregnancy, systemic corticosteroids are the main treatment for this condition.

Besides pustular psoriasis, major dermatoses that should be differentiated from drug-induced pustular eruption are acute generalized exanthematous pustulosis (AGEP), pustulosis acuta generalisata (PAG), and subcorneal pustular dermatosis (SPD). AGEP is a rare severe cutaneous adverse reaction most often caused by drugs<sup>13</sup> which is characterized by fever, neutrophilia, and acute, extensive formation of nonfollicular sterile pustules on an erythematous background<sup>14</sup>. AGEP has also been

reported in pregnant patients<sup>15-17</sup>. The development of cutaneous symptoms in AGEP is almost always accompanied by fever greater than 38°C, and pustules usually resolve spontaneously within several days<sup>18</sup>. In the present case, a fever developed on the last day of the patient's pregnancy; however, the acute exacerbation of erythema was not accompanied an increase in body temperature. Furthermore, the morphology of the erythema, which developed irregular annular configurations with repeated partial regression and regeneration, was also distinct from that of AGEP.

PAG is a poststreptococcal disease that has been reported in association with streptococcal vaginitis<sup>19</sup>. In the present case, bacterial culture of the vaginal discharge demonstrated normal *Lactobacillus* flora, suggesting that the patient's condition was not associated with PAG.

SPD, also known as "Sneddon-Wilkinson disease," is a rare, chronic, recurrent pustular eruption characterized by subcorneal pustules containing abundant neutrophils<sup>20</sup>. Because SPD pustules usually do not form spongiform structures, the patients condition was likely not associated with SPD.

In the present case, because of the close similarities in their cutaneous and histological features, drug-induced pustular eruption and IH could not be distinguished antenatally. The pyrexia, marked edema of the patient's lower thighs, and the abnormalities of laboratory data could all have been manifestations of the systemic inflammation that occurs in IH. However, the marked improvement of both the cutaneous and biological findings within several days of drug withdrawal strongly indicated the origin of this eruption. At this point, it was still difficult to determine whether the symptom improvement was brought about by drug withdrawal or the resolution of the pregnancy. On the basis of the positive results of the patch test, we finally concluded that her clinical condition was an allergic reaction to ritodrine.

In conclusion, we have reported a case of ritodrine-induced pustular eruptions in a pregnant woman without a history of skin eruptions. In reporting the present case, we emphasize that

ritodrine can cause drug-induced pustular eruptions, which could be misdiagnosed as life-threatening IH.

### References

1. Young DC, Toofanian A, Leveno KJ: Potassium and glucose concentrations without treatment during ritodrine tocolysis. *Am J Obstet Gynecol* 1983; 145: 105-106.
2. Yamada T, Okamoto Y, Kasamatsu H: Ritodrine-induced skin rash. *Arch Gynecol Obstet* 2001; 264: 218-219.
3. Ritodrine approved for premature labor. *FDA Drug Bull* 1980; 10: 22.
4. Bosnyak S, Baron JM, Schreiber J: Acute cutaneous vasculitis associated with prolonged intravenous ritodrine hydrochloride therapy. *Am J Obstet Gynecol* 1991; 165: 427-428.
5. Beitner O, Hod M, Friedman S, Ovadia J, Mimouni M: Ritodrine-induced erythema multiforme. *Drug Intell Clin Pharm* 1988; 22: 724.
6. D'Incan M, Fabricio L, Souteyrand P: Ritodrine-induced pustular eruption in a pregnant woman with psoriasis. *J Eur Acad Dermatol Venereol* 1998; 11: 91-93.
7. Umezawa Y, et al: Therapeutic guidelines for the treatment of generalized pustular psoriasis (GPP) based on a proposed classification of disease severity. *Arch Dermatol Res* 2003; 295 (Suppl 1): S43-54.
8. Lim KS, Tang MB, Ng PP: Impetigo herpetiformis—a rare dermatosis of pregnancy associated with prenatal complications. *Ann Acad Med Singapore* 2005; 34: 565-568.
9. Henson TH, Tuli M, Bushore D, Talanin NY: Recurrent pustular rash in a pregnant woman. *Arch Dermatol* 2000; 136: 1055-1060.
10. Breier-Maly J, Ortel B, Breier F, Schmidt JB, Hönigsmann H: Generalized pustular psoriasis of pregnancy (impetigo herpetiformis). *Dermatology* 1999; 198: 61-64.
11. Oumeish OY, Parish JL: Impetigo herpetiformis. *Clin Dermatol* 2006; 24: 101-104.
12. Katsambas A, Stavropoulos PG, Katsiboulas V, et al: Impetigo herpetiformis during the puerperium. *Dermatology* 1999; 198: 400-402.
13. Davidovici BB, Pavel D, Cagnano E, Rozenman D, Halevy S: Acute generalized exanthematous pustulosis following a spider bite: report of 3 cases. *J Am Acad Dermatol* 2006; 55: 525-529.
14. Britschgi M, Pichler WJ: Acute generalized exanthematous pustulosis, a clue to neutrophil-mediated inflammatory processes orchestrated by T cells. *Curr Opin Allergy Clin Immunol* 2002; 2: 325-331.
15. Green MG, Bragg J, Rosenman KS, Pomeranz MK: Pustular psoriasis of pregnancy in a patient whose dermatosis showed features of acute generalized exanthematous pustulosis. *Int J Dermatol* 2009; 48: 299-303.
16. Belhadjali H, Ghannouchi N, Njim L, et al: Acute generalized exanthematous pustulosis induced by buprenorphine in an atopic girl. *Contact Dermatitis* 2008; 58: 247-248.
17. Matsumoto Y, Okubo Y, Yamamoto T, Ito T, Tsuboi R: Case of acute generalized exanthematous pustulosis caused by ampicillin/cloxacillin sodium in a pregnant woman. *J Dermatol* 2008; 35: 362-364.
18. Halevy S: Generalized exanthematous pustulosis (AGEP). *Curr Opin Allergy Clin Immunol* 2009; 9: 322-328.
19. Laimer M, Koller J, Selhofer S, Massone C: Pustulosis acuta generalisata and streptococcal vaginitis. *J Eur Acad Dermatol Venereol* 2009; 23: 583-584.
20. Freedberg IM, et al: *Fitzpatrick's Dermatology in General Medicine*, 6th ed. 2003.

(Received, March 18, 2011)

(Accepted, May 18, 2011)