

Long-term Outcomes after Frey's Procedure for Chronic Pancreatitis with an Inflammatory Mass of the Pancreatic Head, with Special Reference to Locoregional Complications

Takayuki Aimoto¹, Eiji Uchida¹, Akira Matsushita¹,
Yoichi Kawano¹, Satoshi Mizutani² and Tadashi Kobayashi³

¹Department of Surgery, Nippon Medical School

²Institute of Gastroenterology, Nippon Medical School Musashi Kosugi Hospital

³Kobayashi Hospital, Tokyo

Abstract

Background: Frey's procedure might be a good alternative to pylorus-preserving pancreaticoduodenectomy (PPPD) for patients with an inflammatory mass of the head of the pancreas, because it is technically easy and associated with low morbidity and good pain relief.

Purpose: To analyze the short-term and long-term outcomes of Frey's procedure in comparison with PPPD and to evaluate the efficacy of Frey's procedure against preoperative locoregional complications.

Patients and Methods: From August 1997 through December 2007, 6 patients underwent Frey's procedure (as described by Frey and Smith), and 10 patients underwent PPPD. The mean follow-up times were 70.8 months (Frey's procedure) and 119.8 months (PPPD). Preoperative biliary stricture and duodenal stenosis were observed in 4 and 3 patients, respectively, of patients undergoing Frey's procedure. Pain intensity was assessed with a pain scoring system. Quality of life (QOL) was assessed with the European Organization for Research and Treatment of Cancer Quality of-Life Questionnaire-Core 30. Exocrine and endocrine pancreatic function was measured during follow-up.

Results: Significant reductions in total pain scores and all QOL scale scores were observed immediately after surgery in all patients ($P < 0.05$). Frey's procedure was superior to PPPD with regard to physical status 7 years after surgery ($P < 0.05$). One patient in the Frey group had a grade B pancreatic fistula, and 2 patients in the PPPD group had intra-abdominal bleeding and delayed gastric emptying. There were no re-operations or surgery-related deaths in either group. Diabetes developed postoperatively in 2 patients in the PPPD group. No patients with preoperative duodenal or biliary stricture or both had a relapse. Three patients in the PPPD group died during follow-up of diseases unrelated to chronic pancreatitis.

Conclusion: Frey's procedure is safe and effective with regard to pain relief, preservation of pancreatic function, and improvement of QOL over the long term. Moreover, this procedure can also be used to treat preoperative biliary stricture and duodenal stenosis associated with an inflammatory mass of the pancreatic head.

(J Nippon Med Sch 2013; 80: 148–154)

Key words: chronic pancreatitis, long-term outcome, Frey's procedure pancreaticoduodenectomy, locoregional complications

Introduction

An inflammatory mass in the head of the pancreas develops in nearly one-third of patients with chronic pancreatitis (CP) and causes intractable pain because the "pacemaker" of CP pain is believed to be in this region^{1,2}. Moreover, enlargement of the pancreatic head leads to locoregional complications, such as biliary stenosis and duodenal compression^{3,4}. Therefore, an inflammatory mass in CP has, until recently, been considered an indication for radical resection, such as pylorus-preserving pancreaticoduodenectomy (PPPD)²⁻⁴.

In 1987, Frey and Smith described a novel organ-preserving procedure, now known as Frey's procedure, for resection of the pancreatic head which combined local resection of the pancreatic head and lateral pancreaticojejunostomy⁵. This procedure is technically easy, associated with low morbidity, and provides good pain relief^{5,6}. In a study comparing Frey's procedure with PPPD, Frey's procedure was superior to PPPD in terms of morbidity after 2 years⁷. Therefore, Frey's procedure might be a good alternative to PPPD.

Some recent studies have examined long-term outcomes after Frey's procedure. However, few studies have examined the long-term results in terms of the recurrence of preoperative locoregional complications related to pancreatitis. The purpose of the present study was to analyze the short-term and long-term outcomes of Frey's procedure and PPPD in patients with an inflammatory mass and to evaluate the efficacy of Frey's procedure for preventing preoperative locoregional complications.

Patients and Methods

From August 1997 through December 2007, 6 patients (6 men; median age, 51 years; age range, 46 to 62 years) underwent Frey's procedure (Frey group), and 10 patients (8 men and 2 women; median age, 56 years; age range, 36 to 76 years) underwent PPPD (PPPD group) in the Department of Surgery, Nippon Medical School. Patient characteristics are summarized in **Table 1**. An alcoholic etiology was

confirmed in 5 patients undergoing Frey's procedure and in 8 patients undergoing PPPD. All patients complained of persistent, intractable pain. Pancreatic head enlargement was defined as an anteroposterior diameter greater than 35 mm on cross-sectional computed tomography. The main pancreatic duct was considered to be dilated if its maximum diameter was greater than 7 mm on endoscopic retrograde cholangiopancreatography or magnetic resonance cholangiopancreatography. Diabetes mellitus was present in 1 patient undergoing Frey's procedure and in 2 patients undergoing PPPD. Exocrine insufficiency was preoperatively observed in only 1 patient undergoing PPPD. Of the patients who underwent Frey's procedure, 4 had extrahepatic biliary stricture and 3 had duodenal stenosis. The mean follow-up time was 70.8 months in the Frey group and 119.8 months in the PPPD group.

The principal indication for surgery was severe, persistent pancreatic pain requiring opiate medication. Surgery was performed as described by Frey and Smith⁵ in 1987: excavation of the pancreatic head including the ductal structures in continuity with a long dichotomy of the Wirsung duct followed by 2-layer pancreaticojejunostomy with a Roux-en-Y loop (**Fig. 1**). Frey's procedure was first performed in our hospital in 2000. Since then, PPPD has been preferred for patients suspected to have a malignancy. PPPD was performed in a standard fashion as previously described, and reconstruction was performed with a modified Child method. All patients in this study were confirmed with histopathological examination to have no malignancy.

Pain intensity was estimated with a pain scoring system including a visual analog scale, the frequency of pain attacks, the use of analgesic medication, and the duration of the inability to work. The total possible score ranged from 0 to 100, with higher values indicating more severe pain. This questionnaire was administered before surgery and during follow-up (1, 3, 5, 7 years after surgery). The quality of life (QOL) before and after surgery was assessed with the European Organization for Research and Treatment of Cancer Quality of Life

Table 1 Patient characteristics

	Frey's procedure (n=6)	PPPD (n=10)	P value
Age (years)	51.5	56.4	NS
Sex (male/female)	6/0	8/2	NS
Etiology			
alcoholic	5	8	NS
idiopathic	1	2	
Inflammatory mass (mm)	49.5	43.6	NS
Main pancreatic duct (mm)	9.8	8.3	NS
Preoperative			
Diabetes mellitus	1	2	NS
Steatorrhea	0	1	NS
Duodenal stenosis	3	2	NS
Biliary stenosis	4	7	NS
Perioperative			
Operative time (min)	362	486	<0.05
Blood loss (mL)	718	1,293	<0.05
Hospital stay (d)	28	33	<0.05
Postoperative			
Alcohol abuse	0	1	NS
Mean follow-up time (mo)	70.8	119.8	NS

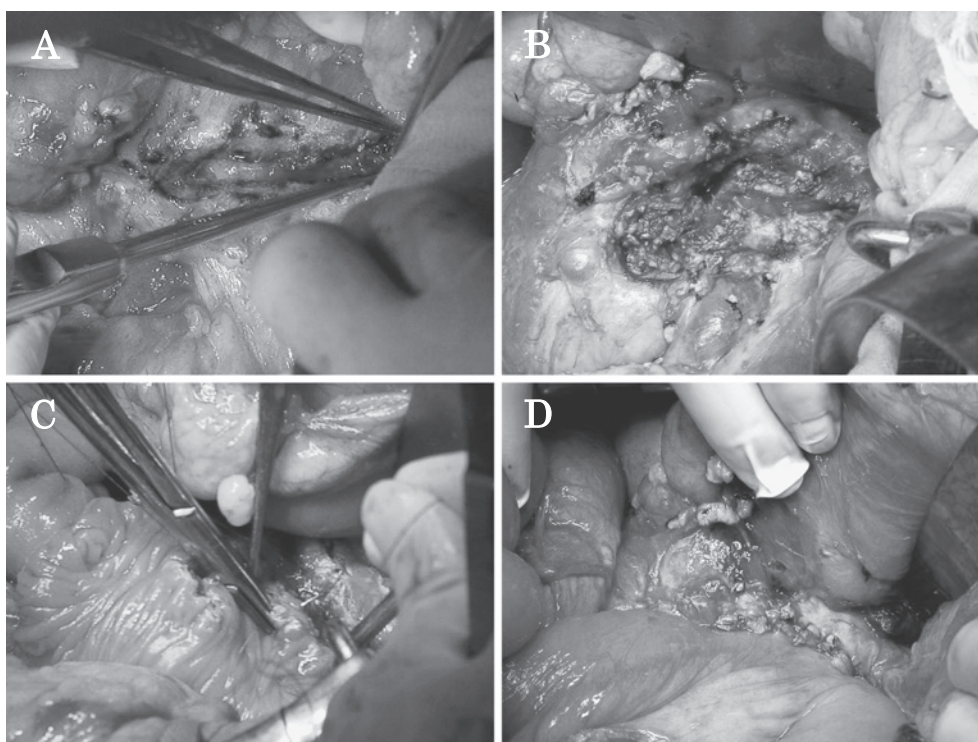


Fig. 1 Surgical technique of Frey's procedure

- A. Opening the main pancreatic duct from the body to the tail
- B. Coring out an inflammatory mass in the head
- C. Performing pancreaticojejunal anastomosis
- D. The finished view

Questionnaire-Core 30. This questionnaire comprises items relating to physical status; working ability; emotional, cognitive, and social functioning; and a

global QOL scale.

Exocrine pancreatic function was assessed on the basis of the presence of steatorrhea or a pancreatic

Long-term Outcomes after Frey's Procedure

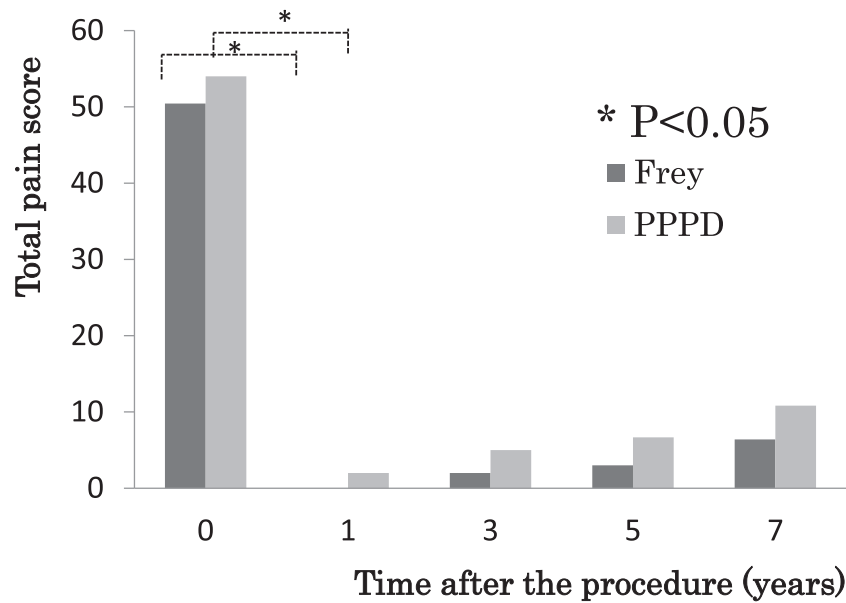


Fig. 2 Preoperative and postoperative evaluation of the total pain score

function diagnostic test. Steatorrhea was defined as more than 3 stools per day, nauseating smell, and greasy and pale stools. The glucose tolerance test was used to assess endocrine function. Diabetes mellitus was defined as a blood glucose level of more than 200 mg/dL 2 hours after a 75-g oral glucose load.

Statistical Analysis

Nonparametric data are expressed as medians. Statistical analysis was performed with SPSS version 15.0 (SPSS Inc., Chicago, IL, USA), according to the instructions given by medical statistical articles^{8,9}. A value of $P < 0.05$ was considered to indicate statistical significance.

Results

Pain Relief and QOL Status

The total pain score and all QOL scores decreased immediately after the procedure in all patients ($P < 0.05$, **Fig. 2 and 3**). Only 1 patient undergoing PPPD did not obtain pain relief during follow-up, because he resumed alcohol consumption. Frey's procedure was superior to PPPD with regard to physical status 7 years after surgery ($P < 0.05$, **Fig. 3**).

Postoperative Morbidity and Mortality

One patient in the Frey group had a grade B pancreatic fistula, according to the International Study Group on Pancreatic Fistula criteria, which was treated conservatively. In the PPPD group, 1 patient without pancreatic fistula had intra-abdominal bleeding on day 7 after surgery and required interventional radiotherapy, and another patient showed delayed gastric emptying. However, there were no re-operations or surgery-related deaths. Additional procedures, such as choledochojejunostomy, gastroenterostomy, and cystojejunostomy, were not needed during follow-up in the Frey group. Three patients in the PPPD group died of alcoholic liver failure (5 months later), stroke (2.5 years later), or unknown cause (10 years later).

Exocrine and Endocrine Pancreatic Function

In the PPPD group diabetes developed postoperatively in 2 patients, and diabetes worsened and required insulin therapy in 2 patients. Glycemic status remained stable in all patients of the Frey group. One patient requiring oral antidiabetic drugs could be treated with a reduced dose after surgery. Only 1 patient in the PPPD group had steatorrhea before surgery and required oral pancreatic enzyme supplementation during follow-up.

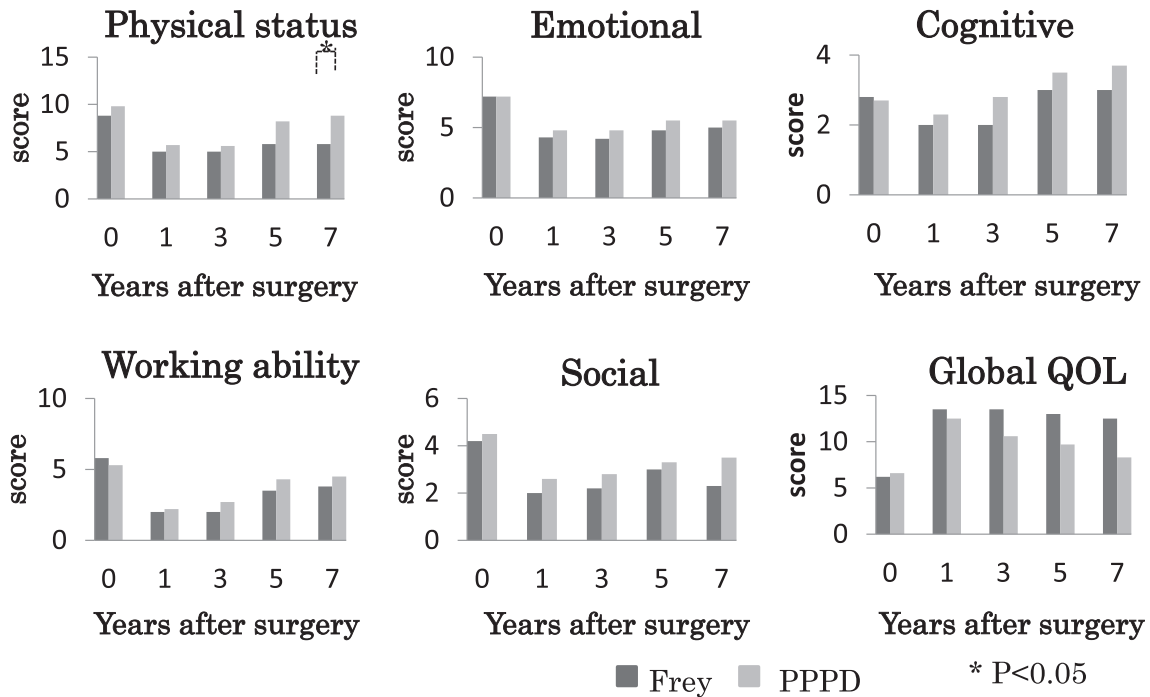


Fig. 3 Preoperative and postoperative evaluation of the QOL scale scores

Pancreatitis-related Locoregional Complications in the Frey Group

All patients in the Frey group were assessed with computed tomography, magnetic resonance, and gastrointestinal endoscopy every year after surgery to evaluate the efficacy of this operation against pancreatitis-related complications. No patients who had preoperative duodenal stricture or biliary stricture or both had a relapse during follow-up. One patient with previous biliary stricture had associated common bile duct stones requiring endoscopic sphincterotomy 6 years later, although biliary stricture was not detected.

Discussion

The main goal of the surgical treatment of CP is to alleviate severe pancreatic pain and to manage pancreatitis-related locoregional complications. The principle of Frey's procedure is to decompress the branch ducts in the head of the pancreas, which is considered to be the "controller of inflammation,"¹⁰ and to core out an inflammatory mass, which leads to locoregional complications. The enlarged pancreatic head is excised almost in its entirety, leaving behind a bridge of pancreatic tissue about

10 mm wide, while a rim of pancreas (5 to 10 mm) remains beside the duodenum and on the upper margin of the pancreatic head^{5,6,11}. The pancreatic neck above the portal vein and superior mesenteric vein are left intact¹². Although coring out an inflammatory mass in Frey's procedure is safer and easier than removing the pancreatic head in PPPD¹⁰, PPPD can prevent the recurrence of locoregional complications through removal of the inflammatory mass, the lower bile duct, and the duodenum. The key problem is whether the wide excision in Frey's procedure can control biliary stricture and duodenal stenosis over the long term.

The 2 procedures are equally safe and effective with regard to pain relief, but Frey's procedure is superior to PPPD with regard to pancreatic function and QOL over the long term. Chiang et al¹³ performed a prospective nonrandomized study of 42 patients to compare preoperative and postoperative status after Frey's procedure and pancreaticoduodenectomy and reported no significant difference in morbidity, mortality, pain relief, or improvement in pancreatic function 3 and 6 months after surgery. Izbicki et al⁷ performed a prospective randomized study of 61 patients comparing Frey's procedure and PPPD and

concluded that Frey's procedure achieved equal pain relief and had a lower morbidity rate (19%) compared with PPPD (53%) and achieved better QOL scores (71 vs. 43) over a 2-year follow-up period. Strate et al¹⁴ have reported that pain relief and survival rates are similar after either procedure after an average of 7 years of follow-up. However, the incidence of diabetes was 65% after PPPD. Farkas et al¹¹ have reported de-novo diabetes mellitus developed in 3 patients after PPPD and that Frey's procedure led to better QOL in the long term. Our results support these findings and demonstrate that Frey's procedure should be considered as an alternative to PPPD in patients with CP and an inflammatory mass of the pancreatic head.

In the present series, preoperative biliary stricture and duodenal stenosis due to an inflammatory mass of the pancreatic head could be successfully managed with Frey's procedure alone in most cases. The recurrence of complications is caused by recurrent alcoholic pancreatitis after the resumption of drinking or continuous inflammation in patients with idiopathic pancreatitis. The incidence of these complications, requiring further treatment, after surgery is not necessarily high, even if alcohol consumption is resumed. In addition, locoregional complications occurred not immediately after surgery but 1 year or more after the procedure, suggesting that the procedure itself could manage these complications. Indeed, the wide excision of the pancreatic head should lead to decompression of the stenosis of the common bile duct and duodenum^{11,12}. Negi et al¹⁵ found in a prospective study of 60 patients undergoing Frey's procedure that 26 patients had pancreatitis-related locoregional complications before surgery and that only 2 patients (8%) required reoperation—1 for biliary stricture and 1 for duodenal stenosis. In a study by Falconi et al¹⁶, only 1 patient (8%) required hepaticojejunostomy to treat jaundice 38 months later, although 6 patients had jaundice before surgery, and 6 cases without jaundice had biliary stricture detected with preoperative imaging. Egawa et al¹⁰ reported that 1 of 71 patients (1.4%) who had a markedly dilated bile duct preoperatively underwent choledochoduodenostomy with cholecystectomy 20

months after the primary operation. In the present study, long-term follow-up showed no relapse of locoregional complications, as indicated by symptoms and morphological changes, in any patient.

On the other hand, additional procedures, biliodigestive anastomosis or gastrojejunostomy or both, combined with Frey's procedure are routinely performed at some institutions for patients with persistent locoregional complications. However, the prophylactic procedures for locoregional complications are controversial in terms of surgical outcomes. Roch et al¹⁷ have performed biliodigestive bypass or gastroenterostomy or both as an additional procedure for all patients with locoregional complications regardless of the presence of symptoms. Farkas et al¹¹ opened the dilated common bile duct with an incision and sutured the opened duct wall to the surrounding pancreatic tissue. However, 5 patients in their series required biliodigestive bypass because of recurrent bile duct stenosis within 2 years after surgery. In addition, several articles have suggested that choledochoduodenostomy and cholecystoenterostomy must be avoided whenever possible because they are associated with a high incidence of cholangitis^{18,19}.

In conclusion, long-term follow-up in the present study has shown that Frey's procedure is safe and effective with regard to pain relief, preservation of pancreatic function, and improvement of QOL. Moreover, Frey's procedure can also be used to manage preoperative biliary stricture and duodenal stenosis associated with an inflammatory mass of the pancreatic head after surgery in most cases. Therefore, Frey's procedure, without additional procedures, could be an alternative to PPPD for patients with inflammatory enlargement of the pancreatic head and without evidence of malignancy.

References

1. Braganza JM, Lee SH, McCloy RF, McMahon MJ: Chronic pancreatitis. *Lancet* 2011; 377: 1184–1197.
2. Demir IE, Tiefertunk E, Maak M, Friess H, Ceyhan GO: Pain mechanisms in chronic pancreatitis: of a master and his fire. *Langenbecks Arch Surg* 2011; 396: 151–160.
3. Bachmann K, Mann O, Izbicki JR, Strate K: Chronic

- pancreatitis—a surgeon's view. *Med Sci Monit* 2008; 14: 198–205.
4. Anderson DK, Frey CF: The Evolution of the Surgical Treatment of Chronic Pancreatitis. *Ann Surg* 2010; 251: 18–32.
 5. Frey CF, Smith GJ: Description and rationale of a new operation for chronic pancreatitis. *Pancreas* 1987; 2: 701–707.
 6. Frey CF, Amikura K: Local resection of the head of the pancreas combined with longitudinal pancreaticojejunostomy in the management of patients with chronic pancreatitis. *Ann Surg* 1994; 220: 492–504.
 7. Izbicki JR, Bloechle C, Broering DC, Knoefel WT, Kuechler T, Broelsch CE: Extended drainage versus resection in surgery for chronic pancreatitis: a prospective randomized trial comparing the longitudinal pancreaticojejunostomy combined with local pancreatic head excision with the pylorus-preserving pancreatoduodenectomy. *Ann Surg* 1998; 228: 771–779.
 8. Watanabe H: Applications of Statistics to Medical Science (I) Fundamental Concepts. *J Nippon Med Sch* 2011; 78: 274–279.
 9. Watanabe H: Applications of Statistics to Medical Science, II Overview of Statistical Procedures for General Use. *J Nippon Med Sch* 2012; 79: 31–36.
 10. Egawa S, Motoi F, Sakata N, et al.: Assessment of Frey procedures: Japanese experience. *J Hepatobiliary Pancreat Sci* 2010; 17: 745–751.
 11. Farkas G, Leindler L, Daróczy M, Farkas J: Long-term Follow-up After Organ-Preserving Pancreatic Head Resection in Patients with Chronic Pancreatitis. *J Gastrointest Surg* 2008; 12: 308–312.
 12. Aimoto T, Uchida E, Nakamura Y, et al.: Current surgical treatment for chronic pancreatitis. *J Nippon Med Sch* 2011; 78: 352–359.
 13. Chiang KC, Yeh CN, Hsu JT, et al.: Pancreaticoduodenectomy versus Frey's procedure for chronic pancreatitis: preliminary data on outcome and pancreatic function. *Surg Today* 2007; 37: 961–966.
 14. Strate T, Bachmann K, Busch P, et al.: Resection vs. drainage in treatment of chronic pancreatitis: long-term results of a randomized trial. *Gastroenterology* 2008; 134: 1406–1411.
 15. Negi S, Singh A, Chaudhary A: Pain relief after Frey's procedure for chronic pancreatitis. *Br J Surg* 2010; 97: 1087–1095.
 16. Falconi M, Bassi C, Casetti L, et al.: Long-term Results of Frey's Procedure for Chronic Pancreatitis: A Longitudinal Prospective Study on 40 Patients. *J Gastrointest Surg* 2006; 10: 504–510.
 17. Alexandria RM, Brachet D, Lermite E, Pessaux P, Arnaud JP: Frey procedure in patients with chronic pancreatitis: short and long-term outcome from a prospective study. *J Gastrointest Surg* 2012; 16: 1362–1369.
 18. da Cunha JE, Bacchella T, Mott CB, Jukemura J, Abdo EE, Machado MC: Surgical treatment of biliary complications from calcifying chronic pancreatitis. *Int Surg* 1984; 69: 149–154.
 19. Vijungco JD, Prinz RA: Management of biliary and duodenal complications of chronic pancreatitis. *World J Surg* 2003; 27: 1258–1270.

(Received, August 30, 2012)

(Accepted, October 4, 2012)