

# Efficacy of Eculizumab in a Patient with Paroxysmal Nocturnal Hemoglobinuria Requiring Transfusions 14 Years after a Diagnosis in Childhood

Takahiro Ueda, Jun Hayakawa, Miho Yamanishi,  
Miho Maeda and Yoshitaka Fukunaga

Department of Pediatrics, Nippon Medical School

## Abstract

Paroxysmal nocturnal hemoglobinuria (PNH) is a rare, acquired clonal disorder characterized by chronic complement-mediated hemolysis. The humanized anti-C5 antibody eculizumab binds to the C5 protein and suppresses hemolysis by inhibiting C5b-9 generation. Here, we report on a 27-year-old woman who was found to have PNH in 1997 (at 13 years of age), without subsequent transfusions, thrombosis, or renal disorder. She had been experiencing frequent malaise and fatigue and was sometimes unable to participate in social activities. She had also experienced repeated hemolytic episodes due to infection, and the hemoglobin level had decreased from 7.0 to 5.0 g/dL several times since February 2010. Red blood cell transfusion was necessary, and 6 months later, treatment with eculizumab was started. The hemoglobin level stabilized, and the patient became transfusion-independent. Furthermore, the patient showed significant improvements in fatigue scale scores and quality of life. Six months after the start of eculizumab therapy, the percentage of PNH-type red blood cells was found to have increased from 82.0% ( $1.95 \times 10^{12}$  cells/L) to 89.1% ( $2.78 \times 10^{12}$  cells/L). Furthermore, during treatment with eculizumab, intravascular hemolysis occurred due to a viral infection accompanied by a high fever. We also observed a persistent elevation in reticulocytes and total bilirubin levels, as well as a persistent reduction in haptoglobin levels. Extravascular hemolytic findings were also observed. Because treatment with eculizumab was started at a young age (27 years) and will be continued for many years, careful observation of the patient is required.

(J Nippon Med Sch 2013; 80: 155–159)

**Key words:** paroxysmal nocturnal hemoglobinuria, eculizumab, fatigue, hemolysis

## Introduction

Paroxysmal nocturnal hemoglobinuria (PNH) is a

rare, hematopoietic stem-cell disorder in which abnormal stem cells have somatic mutations of the phosphatidylinositol glycan gene, resulting in partial or complete deficiency of glycosyl-

---

Correspondence to Takahiro Ueda, MD, PhD, Department of Pediatrics, Nippon Medical School, 1-1-5 Sendagi, Bunkyo-ku, Tokyo 113-8603, Japan

E-mail: yuri878t@nms.ac.jp

Journal Website (<http://www.nms.ac.jp/jnms/>)

phosphatidylinositol (GPI)-linked proteins. A lack of GPI-linked proteins leads to an increased susceptibility of red blood cells (RBCs) to activate the complement system and to be destroyed by the membrane attack complex, resulting in the clinical features of PNH. Clinically, PNH is characterized by acquired Coombs-negative intravascular hemolytic anemia, thrombophilia, and bone marrow failure<sup>12</sup>. PNH is a life-threatening disorder resulting from chronic, uncontrolled complement activation and chronic hemolysis. Intravascular hemolysis causes the release of free hemoglobin (Hb), which leads to depletion of nitric oxide (NO) in the plasma. Depletion of NO causes complications associated with smooth muscle dystonia, including abdominal pain, dysphagia, pulmonary hypertension, renal impairment, erectile dysfunction and fatigue<sup>12</sup>.

Eculizumab is an inhibitor of terminal complement activation and is a beneficial new agent for the treatment of PNH. Here, we describe a patient with PNH who became transfusion-dependent 14 years after an initial diagnosis in childhood and for whom administration of eculizumab was effective.

### Case Report

A 27-year-old woman received a diagnosis of PNH at the age of 13 years (in 1997). From the time of diagnosis, she had not required blood transfusions, and levels of lactate dehydrogenase (LDH) and Hb remained stable at approximately 2,000 IU/L and 7.0 g/dL, respectively. Bone marrow examinations did not show malignant cells, myelodysplasia, or chromosomal aberration. Prednisolone (30 mg/day) had been administered since October 2002 because she required 2 transfusions; a maintenance dose of 10 mg/day had been administered since February 2003. No other treatment or transfusions were necessary.

In February 2010, the patient began experiencing repeated hemolytic episodes due to infections, and the Hb level decreased from 7.0 g/dL to 5.0 g/dL several times. As a result, the patient became transfusion-dependent. Fatigue also worsened, resulting in the patient spending a day in bed following a day of work and markedly decreasing

quality of life. In September 2010, treatment with eculizumab was started. At the start of treatment, laboratory studies indicated a Hb level of 6.1 g/dL, a LDH level of 1,792 IU/L, and GPI-deficient RBCs accounting for 82% ( $1.95 \times 10^{12}$  cells/L) of RBCs. The patient received 600 mg of eculizumab intravenously every week for 4 weeks, followed by 900 mg for 1 week and a maintenance dose of 900 mg every 2 weeks thereafter. The patient received a meningococcal vaccine 2 weeks before receiving the first dose of eculizumab. Prednisolone (10 mg/day) was concomitantly administered.

Thrombosis, abdominal pain, and dysphagia were not observed. The effect of eculizumab on chronic intravascular hemolysis was demonstrated by an immediate (1 week) and sustained decrease in LDH levels and an increase in Hb levels (**Fig. 1**). **Table 1** shows laboratory findings before and after the start of eculizumab treatment. The Hb level stabilized, and the LDH level significantly decreased from 2,000 IU/L to 180 IU/L after the start of eculizumab treatment. Intravascular hemolysis also decreased. The percentage of PNH type III RBCs increased from 82.0% ( $1.95 \times 10^{12}$  cells/L) to 89.1% ( $2.78 \times 10^{12}$  cells/L) after 6 months of treatment. However, the haptoglobin level remained low, and total bilirubin and reticulocyte levels remained high. Hemolytic findings remained, but the patient became transfusion-independent because of eculizumab treatment. The fatigue was also significantly alleviated with eculizumab treatment, increasing on the Functional Assessment of Chronic Illness Therapy-Fatigue (FACIT-Fatigue) Scale by 9 and 14 points after 8 and 24 weeks, respectively.

While the patient received eculizumab therapy, hemolysis developed due to a viral infection accompanied by a high fever (**Fig. 1**). During this episode, the Hb level fell from 11.0 to 8.5 g/dL, and the LDH and total bilirubin levels rose from 194 to 400 IU/L and from 1.6 to 5.9 mg/dL, respectively; she also felt a marked general fatigue. However, these symptoms were resolved without further medication or alterations to the eculizumab therapy. In August 2011, prednisolone administration was discontinued.

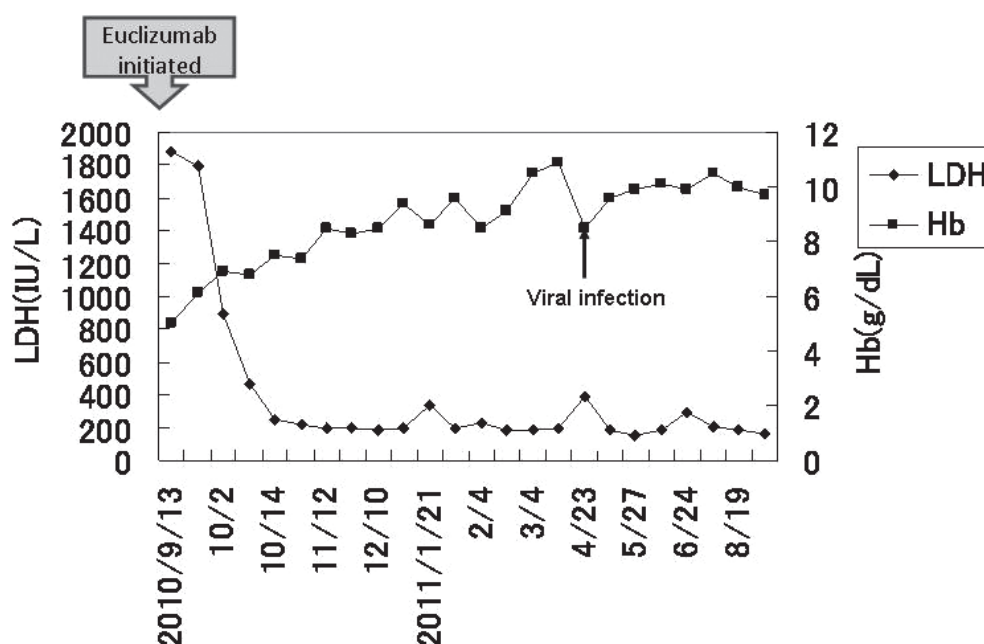


Fig. 1 Changes in the levels of lactate dehydrogenase (LDH) and hemoglobin (Hb) during treatment with eculizumab.

Table 1 Laboratory findings before and 6 months after the initiation of eculizumab

	[Hematology tests]		[Biochemistry/serological tests]		
	Before	After 6 months	Before	After 6 months	
RBC	$2.38 \times 10^{12} /\mu\text{L}$	$3.12 \times 10^{12} /\mu\text{L}$	AST (10-28)	82 IU/L	24 IU/L
Hb	6.1 g/dL	10.5 g/dL	ALT (5-33)	14 IU/L	21 IU/L
Ht	21.9 %	33.3 %	LDH (106-211)	1,792 IU/L	187 IU/L
Plt	$130 \times 10^9 /\text{L}$	$133 \times 10^9 /\text{L}$	T-Bil (0.2-1.2)	1.4 mg/dL	2.0 mg/dL
Ret.	63 %	70 %	D-Bil (0.1-0.7)	0.4 mg/dL	0.6 mg/dL
			BUN (7-20)	12 mg/dL	9.3 mg/dL
GPI-deficient RBCs (CD59-)			Cr (0.6-1.2)	0.55 mg/dL	0.57 mg/dL
	82.0 %	89.1 %	eGFR	107	103 mL/min/m <sup>2</sup>
	( $1.95 \times 10^{12} /\text{L}$ )	( $2.78 \times 10^{12} /\text{L}$ )	Fe (70-180)	32 $\mu\text{g}/\text{dL}$	169 $\mu\text{g}/\text{dL}$
WBC	$4.3 \times 10^9 /\text{L}$	$3.5 \times 10^9 /\text{L}$	Ferritin (6.2-138.0)	8.4 ng/mL	32.1 ng/mL
Neu.	54.5 %	55 %	Haptoglobin	n.d.	n.d.
Ly.	37.5 %	37.8 %	D dimer (0.5>)	0.3 $\mu\text{g}/\text{mL}$	0.4 $\mu\text{g}/\text{mL}$
			Direct Coomb's test	Negative	Slightly positive*
			[Urinalysis]		
			Occult blood test	2+	-
			RBC/HPF	1 >/HPF	1 >/HPF

n.d.: not detected

\* After 9 months

## Discussion

The chronic intravascular hemolysis characteristic of PNH causes weakness, pallor, fatigue, anemia, dyspnea on exertion, reduced quality of life, need for transfusions, renal impairment, and a risk of life-threatening thromboembolic complications<sup>2</sup>. Fatigue

is a common symptom in patients with PNH and occurs not only because of anemia but is also closely linked to NO depletion due to chronic hemolysis<sup>2</sup>. Meyers et al have reported that 96% of PNH patients report fatigue, with 76% experiencing disruptions in daily activities and 17% being unemployed. These events are independent of anemia and transfusion requirements<sup>4</sup>. Similarly, the

present patient frequently experienced malaise and fatigue and was sometimes unable to participate in social activities before the start of eculizumab treatment. After the start of eculizumab therapy, a reduction in intravascular hemolysis was associated with a significant reduction in fatigue, as shown by an increase in the FACIT-Fatigue scale score by 14 points after 24 weeks of therapy. Hillmen et al. have reported that patients with PNH treated with eculizumab showed a mean improvement in FACIT-Fatigue scale scores of  $6.4 \pm 1.2$  points from baseline to week 26<sup>5</sup>. A change of  $\geq 3$  points on the FACIT-Fatigue scale is considered clinically significant<sup>6</sup>. Unlike most patients treated with eculizumab, the present patient began treatment at an early stage of transfusion-dependency and was young and did not have coexisting thrombosis, renal dysfunction, or other major complication of PNH. These may be the reasons that the FACIT-Fatigue Scale increased more in the present patient than in report of Hillmen et al.

Despite the effective inhibition of intravascular hemolysis with eculizumab treatment, the LDH level increased, and the Hb level decreased when the patient experienced a high fever due to a viral infection. Moreover, the number of PNH RBCs increased after she began eculizumab therapy, which may also contribute to breakthrough hemolytic episodes<sup>7</sup>. Roth and Duhrsen reported that increased complement activation can be triggered by viral infection, surgery, trauma, or pregnancy, in spite of eculizumab treatment<sup>8</sup>.

Extravascular hemolysis has been reported in several studies of patients with PNH receiving eculizumab treatment<sup>9,10</sup>. Risitano et al have reported that after eculizumab treatment, RBCs have bound C3 on their surfaces and are destroyed extravascularly in the spleen or liver<sup>9</sup>. Although the Hb levels stabilized, the LDH level decreased significantly during eculizumab therapy, the haptoglobin level remained low, and the total bilirubin and reticulocyte levels remained high in the present patient. Furthermore, the hemoglobinuria, recognized before treatment as an indicator of intravascular hemolysis, was not observed after treatment and may have indicated persistent

extravascular hemolysis. In this patient, however, the extravascular hemolysis was of limited clinical importance.

Kelly et al. have reported that myelodysplastic syndrome or leukemia developed in only 3 of 79 patients treated with eculizumab and that clonal myeloid evolution occurred from GPI-negative clones<sup>11</sup>. During the 14 years between the diagnosis of PNH and the start of eculizumab therapy, the RBC clone size in our patient did not change significantly; however, after the start of eculizumab therapy, the percentage of PNH type III RBCs increased. The patient will require careful monitoring to ensure that long-term eculizumab therapy is not associated with myelodysplastic syndrome or leukemia. The patient will also require careful monitoring during any possible pregnancies and general monitoring of extravascular hemolysis, prolonged accumulation of PNH-type RBCs, the effects of an enlarged population of PNH clones, and complications associated with hematopoietic failure.

## References

1. Parker C, Omine M, Richards S, et al: Diagnosis and management of paroxysmal nocturnal hemoglobinuria. *Blood* 2005; 106: 3699–3709.
2. Hillmen P, Lewis SM, Bessler M, Luzzatto L, Dacie JV: Natural history of paroxysmal nocturnal hemoglobinuria. *N Engl J Med* 1995; 333: 1253–1258.
3. Hill A, Richards SJ, Hillmen P: Recent developments in the understanding and management of paroxysmal nocturnal haemoglobinuria. *Br J Haematol* 2007; 137: 181–192.
4. Meyers G, Weitz I, Lamy T, et al: Disease-related symptoms reported across a broad population of patients with paroxysmal nocturnal hemoglobinuria. *Blood* 2007; 110 abstract 3683.
5. Hillmen P, Young NS, Schubert J, et al: The complement inhibitor eculizumab in paroxysmal nocturnal hemoglobinuria. *N Engl J Med* 2006; 355: 1233–1243.
6. Cella D, Eton DT, Lai JS, Peterman AH, Merkel DE: Combining anchor and distribution-based methods to derive minimal clinically important differences on the Functional Assessment of Cancer Therapy (FACT) anemia and fatigue scales. *J Pain Symptom Manage* 2002; 24: 547–561.
7. Schubert J, Hillmen P, Roth A, et al: Eculizumab, a terminal complement inhibitor, improves anaemia in patients with paroxysmal nocturnal haemoglobinuria. *Br J Haematol* 2008; 142: 263–272.
8. Roth A, Duhrsen U: Treatment of paroxysmal nocturnal hemoglobinuria in the era of eculizumab. *Eur J Haematol* 2011; 87: 473–479.

9. Risitano AM, Notaro R, Marando L, et al: Complement fraction 3 binding on erythrocytes as additional mechanism of disease in paroxysmal nocturnal hemoglobinuria patients treated by eculizumab. *Blood* 2009; 113: 4094-4100.
10. Hill A, Rother RP, Arnold L, et al: Eculizumab prevents intravascular hemolysis in patients with paroxysmal nocturnal hemoglobinuria and unmasks low-level extravascular hemolysis occurring through C3 opsonization. *Haematologica* 2010; 95: 567-573.
11. Kelly RJ, Hill A, Arnold LM, et al: Long-term treatment with eculizumab in paroxysmal nocturnal hemoglobinuria: sustained efficacy and improved survival. *Blood* 2011; 117: 6786-6792.

(Received, April 9, 2012)

(Accepted, May 18, 2012)