

In vivo Reflectance Confocal Microscopy for Skin Imaging in Melasma

Yoko Funasaka, Nobuko Mayumi, Sachiko Asayama, Ryoko Takayama,
Motoko Kosaka, Tokue Kato and Seiji Kawana
Department of Dermatology, Nippon Medical School

In vivo reflectance confocal microscopy (RCM) provides high-resolution, real-time optical imaging of sections of the skin in a noninvasive manner and allows visualization of the skin in its native state. Highly reflective skin components, including melanin, collagen, and keratin, appear bright (white) in RCM images. In a confocal microscope, near-infrared light from a diode laser is focused on a microscopic skin target. As this light passes between cellular structures having different refraction indexes, it is naturally reflected and then captured and recomposed with computer software into a 2-dimensional gray-scale image¹. Focusing the microscope (adjusting the focal point on the z-axis) allows images of different levels within the skin to be obtained.

Melasma is a common acquired symmetrical hypermelanosis characterized by irregular brown macules of the face. Because of the size of the area involved, assessing the condition of the entire melasma by means of biopsy is difficult². The pigmentary lesion of melasma is rather heterogeneous (**Fig. 1**). In heavily pigmented areas, the dendrites of melanocytes are frequently observed around the basal layer (**Fig. 2**). As the dendrites of activated melanocytes elongate³, darkly pigmented areas might be formed because of melanocyte activation.

- Fig. 1** Image of a melasma lesion captured with video microscopy. Pigmentation is heterogeneous. The circled area was the most darkly pigmented and was analyzed with RCM. Dotted scale bar: 1 mm.
- Fig. 2** Confocal image of the circled area in Fig. 1. (a) Upper spinous layer. (b) Lower spinous layer; polygonal cells became smaller. (c) Basal cell layer; increased cobblestoning is seen because of the large amount of melanin. Dendritic cells with bright cytoplasm are seen (**arrows**). (d) Lower level of the dermoepidermal junction; dendritic cells with bright cytoplasm are seen (**arrows**). Scale bar: 50 μ m.

References

1. Calzavara-Pinton P, Longo C, Venturini M, et al.: Reflectance confocal microscopy for *in vivo* skin imaging. *Photochem Photobiol* 2008; 84: 1421–1430.
2. Kang HY, Bahadoran P, Suzuki I, et al.: *In vivo* reflectance confocal microscopy detects pigmentary changes in melasma at a cellular level resolution. *Exp Dermatol* 2010; 19: e228–e233.
3. Nakajima A, Funasaka Y, Kawana S: Investigation by *in vivo* reflectance confocal microscopy: melanocytes at the edges of solar lentigines. *Exp Dermatol* 2012; Suppl1: 18–21.

RCM Images of Melasma

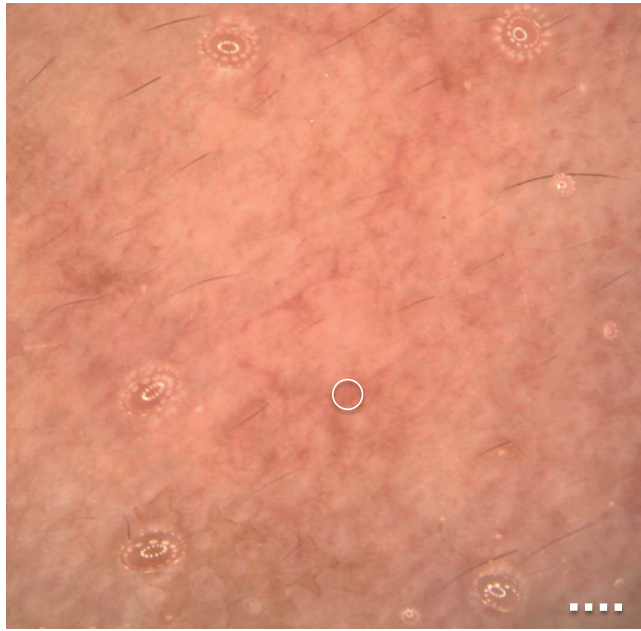


Fig. 1

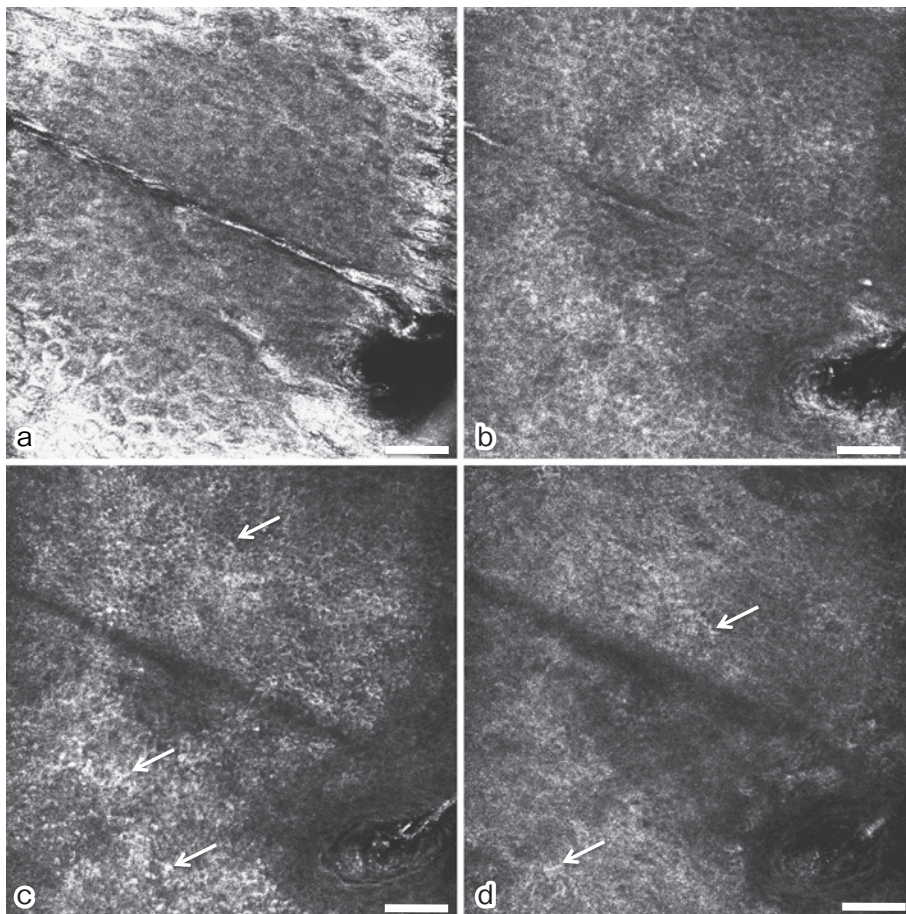


Fig. 2