

## Spermatic Cord Tumor Metastatic from Stomach Cancer 1 Year after Curative Gastrectomy

Yoshikazu Kanazawa<sup>1</sup>, Shunji Kato<sup>1</sup>, Itsuo Fujita<sup>1</sup>, Hiroyuki Onodera<sup>1</sup>,  
Hideyuki Takata<sup>1</sup>, Munehiko Onda<sup>2</sup>, Zenya Naito<sup>2</sup> and Eiji Uchida<sup>1</sup>

<sup>1</sup>Department of Surgery, Nippon Medical School

<sup>2</sup>Department of Pathology, Nippon Medical School

### Abstract

We report a case of advanced stomach cancer metastatic to the spermatic cord 1 year after curative distal gastrectomy. The patient underwent distal gastrectomy with D<sub>2</sub> lymph node dissection. There was no metastasis to the liver or peritoneum, and cytologic examination of the peritoneal lavage fluid was negative for cancer cells (CY0). Histological examination revealed a moderately differentiated tubular adenocarcinoma that had penetrated the serosa (T4a). Postoperative staging was T4aN1M0, stage IIIA, according to the Japanese gastric carcinoma classification scale. One year after the operation, the patient was readmitted with right groin pain. Percutaneous fine needle aspiration biopsy of the inguinal tumor revealed a tubular adenocarcinoma. Extirpation of the inguinal tumor with wedge resection of the right iliac-femoral vein was performed. Pathological examination revealed a moderately differentiated tubular adenocarcinoma that had diffusely infiltrated the connective tissue surrounding the spermatic cord. Immunohistochemical studies showed the tumor cells were reactive for CK7 but not for CK20. These findings were consistent with the diagnosis of a spermatic cord tumor metastatic from a known gastric primary cancer. Laparoscopic exploration showed invagination of the peritoneum with small nodules from the median umbilical fold to the lateral umbilical fold and a markedly decreased distance between the folds. Pathological examination in this area revealed a tubular structure consisting of mesothelial cells within the cancer tissue which was associated with dense fibrosis, suggesting that the invagination of the peritoneum had been caused by minimal peritoneal metastasis.

(J Nippon Med Sch 2013; 80: 318–323)

**Key words:** spermatic cord metastasis, gastric cancer, peritoneal dissemination

### Introduction

Metastatic spermatic cord tumors are rare and account for 8.1% of malignant neoplasms in the

inguinal region<sup>1,2</sup>. The most common primary tumors are stomach cancers, although colonic and pancreatic cancers, when advanced, can metastasize to the spermatic cord<sup>1,2</sup>. Herein, we report a case of advanced stomach cancer metastatic to the

---

Correspondence to Yoshikazu Kanazawa, MD, Department of Surgery, Nippon Medical School, 1-1-5 Sendagi, Bunkyo-ku, Tokyo 113-8603, Japan

E-mail: kanazawa-y@nms.ac.jp

Journal Website (<http://www.nms.ac.jp/jnms/>)

spermatic cord 1 year after a curative distal gastrectomy.

### Case Report

A 66-year-old man was referred to the Nippon Medical School hospital because of anemia in December 2010. This patient had undergone repair of a right inguinal hernia with Bassini's method 20 years earlier. Physical examination showed no remarkable findings. The results of laboratory examination on admission were within normal limits except for the finding of anemia. The serum level of carcinoembryonic antigen was normal. Upper gastrointestinal endoscopy showed an irregular

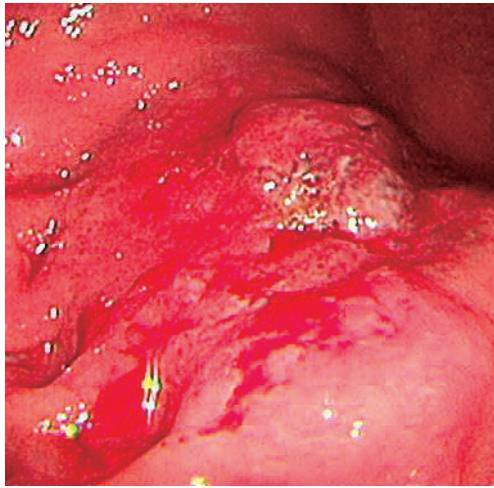


Fig. 1 Upper gastrointestinal endoscopy showed an irregular depressed lesion, type 3 gastric cancer, at the greater wall of the middle third of the stomach.

depressed lesion, type 3 stomach cancer, at the greater curvature of the middle third of the stomach (**Fig. 1**). Abdominal computed tomography (CT) detected no evidence of metastasis to the liver, lung, or perigastric lymph nodes and no evidence of peritoneal dissemination. The patient underwent distal gastrectomy with D<sub>2</sub> lymph node dissection. Intraoperative exploration revealed no metastasis to the liver or peritoneum, and cytologic examination of peritoneal lavage fluid was also negative (CY0). Histopathological examination revealed a moderately differentiated tubular adenocarcinoma, approximately 40 × 40 mm in size, and tumor penetration of the serosa (T4a) with marked lymphatic and severe venous invasion (**Fig. 2a**). Metastasis was observed in 2 of 47 lymph nodes (N1). Neither the proximal nor distal surgical margin was involved (PM0, DM0). Immunohistochemical examination showed that the cancer cells were reactive for CK7 (**Fig. 2b**) but no for CK20. Stage IIIA gastric carcinoma was diagnosed according to the Japanese classification of gastric carcinoma (3rd English edition)<sup>3</sup>. The patient was scheduled to undergo adjuvant chemotherapy with 80 mg/m<sup>2</sup> of S-1 for 4 weeks, followed by 2 weeks of rest after discharge.

One year after the first operation, the patient was readmitted with right groin pain. Physical examination showed a firm, slightly tender mass in the right inguinal region, but no tumors were found in the testis or scrotum. Contrast-enhanced CT and <sup>18</sup>F-fluorodeoxy glucose positron emission

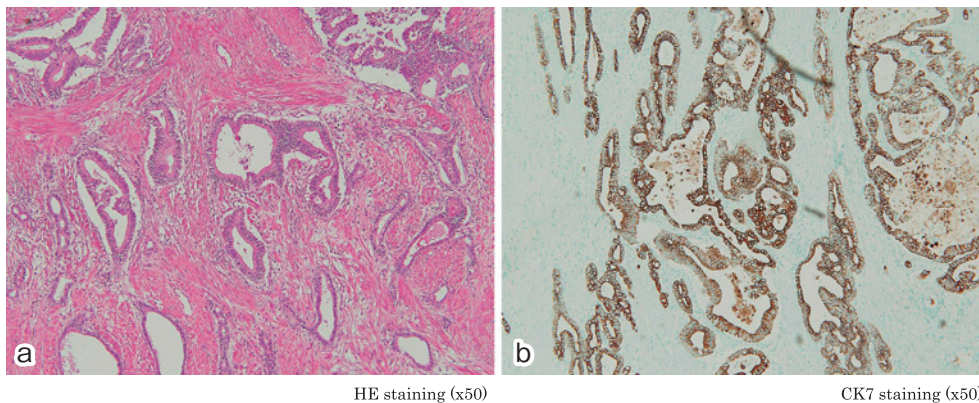
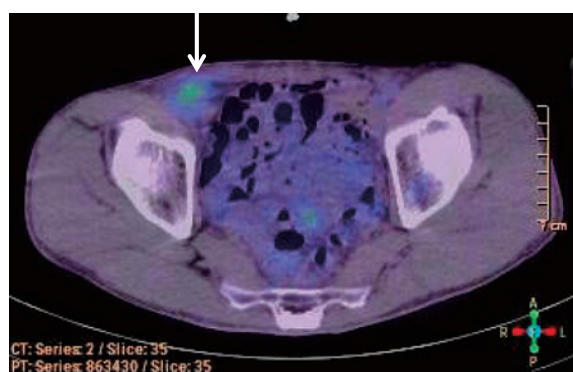


Fig. 2 **a.** Histological examination revealed a moderately differentiated, tubular adenocarcinoma (hematoxylin and eosin, × 50).  
**b.** Cancer cells were immunohistochemically positive for CK7 (× 50).

tomography of the abdomen revealed increased uptake in an isolated tumor in the right inguinal region (**Fig. 3**). There was no recurrence to lymph nodes, including the para-aortic and nonperigastric nodes. Findings of total colonoscopy were unremarkable. Percutaneous fine needle aspiration biopsy of the inguinal tumor revealed a tubular adenocarcinoma.

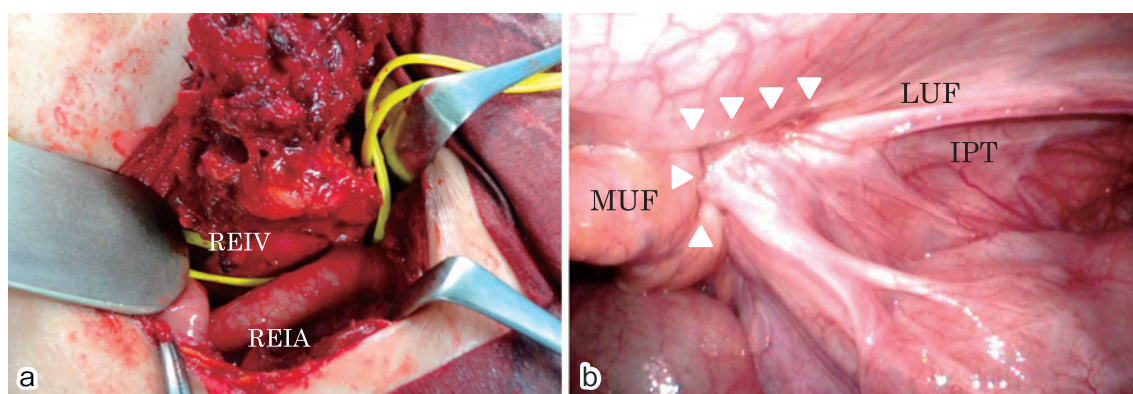
The preoperative diagnosis was a right inguinal recurrent tumor from a known gastric cancer, and extirpation of the tumor was performed. The tumor was primarily located under the right inguinal ligament, and because the tumor was tightly adherent to the anterior wall of the right external



**Fig. 3**  $^{18}\text{F}$ -fluorodeoxy glucose positron emission tomography revealed increased uptake in an isolated tumor in the right inguinal region (**white arrow**).

iliac vein (**Fig. 4a**), wedge resection of this vein was necessary. Simultaneous laparoscopic exploration revealed no evidence of metastasis to the liver, perigastric or nonperigastric lymph node involvement, or diffuse peritoneal dissemination. Intraoperative cytological examination of peritoneal lavage fluid showed no malignancy (CY0). Invagination of the peritoneum with small nodules was found from the median umbilical fold to the lateral umbilical fold (**Fig. 4b**). In addition, the distance between the folds was markedly shorter than on the opposite side, indicating that the inguinal tumor involved the peritoneum in this area.

On gross examination the inguinal tumor was an invasive, light-grayish tumor,  $42 \times 38$  mm in diameter (**Fig. 5**). Histopathological examination revealed a moderately differentiated tubular adenocarcinoma that had diffusely infiltrated throughout the connective tissue surrounding the spermatic cord (**Fig. 6a, 6b**). Neither marked venous nor lymphatic invasion was detected. Immunohistochemical examination showed that the tumor cells were reactive for CK7 but not for CK20. These findings were consistent with the diagnosis of metastasis to the spermatic cord from a known gastric primary cancer. A tubular structure associated with dense fibrosis was detected within the cancer tissue (**Fig. 7a**). This structure consisted



REIV: right external iliac vein  
REIA: right external iliac artery

LUF: lateral umbilical fold  
MUF: median umbilical fold  
IPT: iliopubic tract

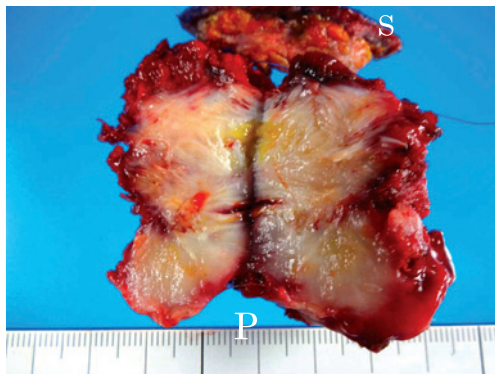
**Fig. 4** **a.** The tumor was located mostly under the right inguinal ligament, and was tightly adherent to the anterior wall of the right external iliac vein.  
**b.** Invagination of the peritoneum with small nodules was detected from the median umbilical fold (MUF) to the lateral umbilical fold (LUF). The distance between the folds was markedly shortened (**white arrowheads**).

of mesothelial cells positive for calretinin (**Fig. 7b**).

The postoperative course was uneventful, and the patient had no groin pain after extirpation. The patient received systemic adjuvant chemoradiotherapy after discharge.

### Discussion

The most common primary tumor metastasizing

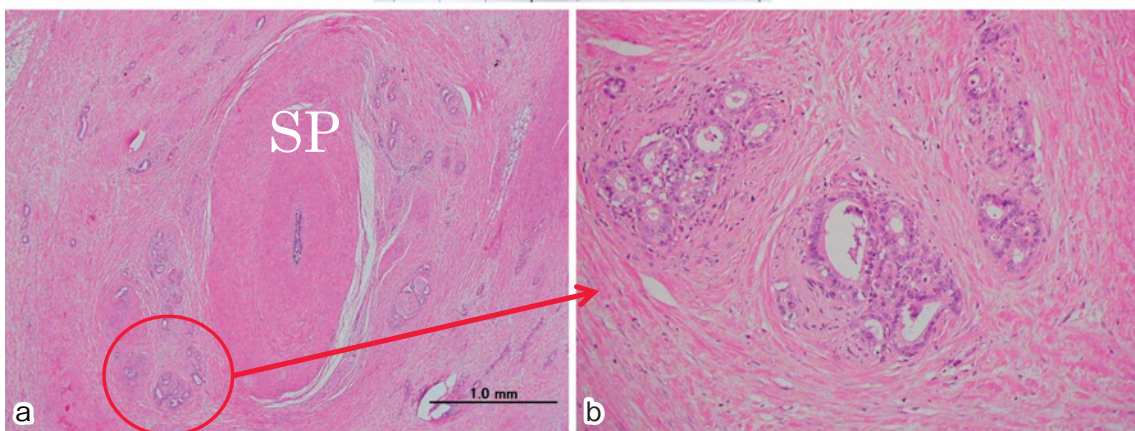
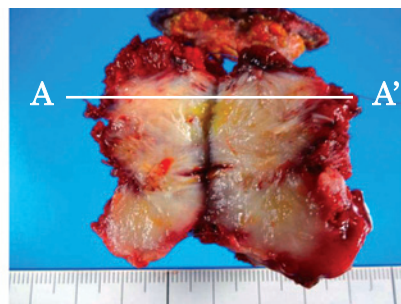


P: peritoneal site  
S: skin

Fig. 5 The inguinal tumor was an invasive, light grayish tumor, 42×38 mm in diameter.

to the spermatic cord is gastric adenocarcinoma<sup>1,2,4-12</sup>. A metastatic spermatic cord tumor typically presents as a painless, palpable groin mass associated with hydrocele; such a metastatic tumor might be the first manifestation of a primary gastric tumor with peritoneal dissemination. The pathological type of the primary gastric carcinoma varies from signet ring cell carcinoma to tubular adenocarcinoma. The mean survival after the diagnosis of a metastatic spermatic cord tumor is approximately 9 months<sup>1</sup>.

Although suggested metastatic pathways from gastrointestinal malignancies to the spermatic cord include the retrograde lymphatic pathway<sup>12,13</sup>, the systemic hematogenous route<sup>13</sup>, and transcoelomic dissemination<sup>14</sup>, the metastatic pathway has not been definitely identified<sup>13,14</sup>. One reason why identifying the metastatic route has been so difficult is that metastatic spermatic cord tumors are extremely rare and provide few chances for close observation<sup>13</sup>. Second, patients with metastatic spermatic cord tumors often receive palliative care, and disease extension is not comprehensively assessed<sup>13,14</sup>.



HE staining (x50)

HE staining (x400)

Fig. 6 The A-A' microscopic section

A moderately differentiated tubular adenocarcinoma had diffusely infiltrated throughout the connective tissue surrounding the spermatic cord (hematoxylin and eosin, **a**: ×50; **b**: ×400)

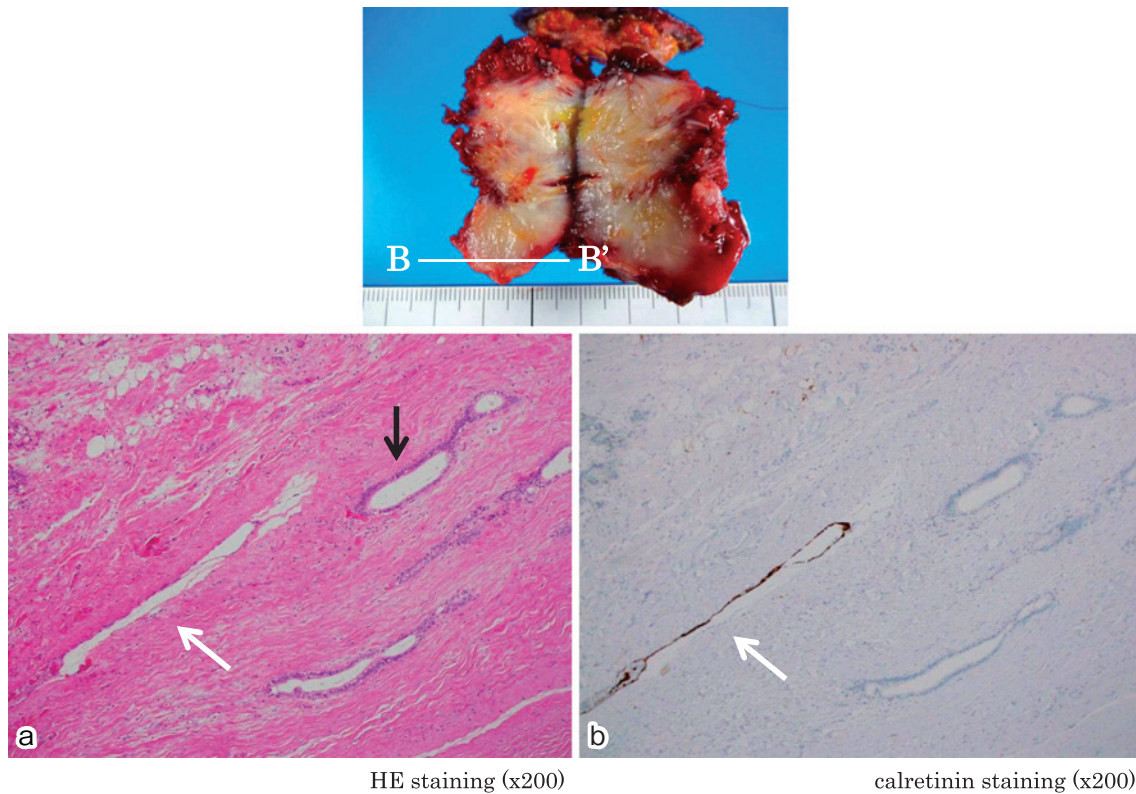


Fig. 7 The B-B' microscopic section

- a. Tubular structure associated with dense fibrosis (**white arrow**) was found within the cancer tissue (hematoxylin and eosin,  $\times 200$ ).
- b. This tubular structure consisted of mesothelial cells (**white arrow**) that were reactive for calretinin ( $\times 200$ ).

In the present case of metastasis to the spermatic cord, laparoscopic exploration and histopathological examination suggested that the most likely metastatic pathway was minimal peritoneal metastasis. First, laparoscopic observation revealed invagination of the peritoneum between the median and lateral umbilical folds and decreased distance between them. These findings could not be accounted for solely on the basis of an anatomical change caused by the use of Bassini's technique for repairing a right inguinal hernia. Kocijan et al<sup>15</sup> demonstrated that the suture technique used in Bassini's method leads to anatomical changes, including reduction of the surface area of Hesselbach's triangle, through a raised inguinal ligament. Furthermore, the use of mesh for a Lichtenstein inguinal hernia repair often induces fibrosis behind the spermatic cord. However, this anatomical change occurs above the fascia transversalis and cannot be observed through the transabdominal view provided by laparoscopy. The

laparoscopic approach for recurrent hernias is easier to perform than are conventional open procedures because scar tissue is not an obstacle<sup>16,17</sup>. Therefore, we concluded that the invagination of the peritoneum observed in the present case indicated the presence of minimal peritoneal metastasis, because Bassini's method alone could not produce the laparoscopic findings we observed. Second, scirrhous cancer cell growth near mesothelial cells suggests that the invagination of the peritoneum was caused by minimal peritoneal metastasis in this region. Indeed, previous studies have found that advanced gastric cancer is rarely associated with minimal peritoneal metastasis in the pelvis<sup>18,19</sup>.

We have reported a case of advanced stomach cancer metastatic to the spermatic cord 1 year after curative surgery. The most likely cause of metastasis to the spermatic cord was minimal peritoneal metastasis.

**Conflict of Interest:** The authors declare that there is no conflict of interest.

### References

1. Algaba F, Santaularia JM, Villavicencio H: Metastatic tumor of the epididymis and spermatic cord. *Eur Urol* 1983; 9: 56–59.
2. Kanno K, Ohwada S, Nakamura S, et al: Epididymis metastasis from colon carcinoma: a case report and a review of the Japanese literature. *Jpn J Clin Oncol* 1994; 24: 340–344.
3. Japanese Gastric Cancer Association: Japanese classification of gastric carcinoma. 3rd English edition. *Gastric Cancer* 2011; 14: 101–112.
4. Yoshida S, Hayashi T, Yoshinaga A, et al: Metastatic tumor of spermatic cord with elevation of serum human chorionic gonadotropin beta-subunit. *Nihon Hinyokika Gakkai Zasshi* 2005; 96: 714–716 [in Japanese].
5. Pozzobon D, Caldato C, Pavanello M, et al: Metastatic gastric neoplasm in the spermatic cord: report of a case. *Chir Ital* 2001; 53: 729–732.
6. Ota T, Shinohara M, Tanaka M, et al: Spermatic cord metastases from gastric cancer with elevation of serum hCG-beta: a case report. *Jpn J Clin Oncol* 2000; 30: 239–240.
7. Kato K, Suzuki K, Sai S, et al: A case of metastatic tumor of spermatic cord with hydrocele from gastric cancer. *Hinyokika Kyo* 1999; 45: 859–861 [in Japanese].
8. Kondo I, Masuda F, Nakada J, et al: A case of metastasis of gastric cancer to spermatic cord. *Hinyokika Kyo* 1988; 34: 718–720 [in Japanese].
9. Kageyama Y, Kawakami S, Li G, et al: Metastatic tumor of spermatic cord and tunica vaginalis testis from gastric cancer: a case report. *Hinyokika Kyo* 1997; 43: 429–431 [in Japanese].
10. Irisawa C, Yamaguchi O, Shiraiwa Y, et al: A case of metastatic tumor of the spermatic cord from gastric carcinoma. *Hinyokika Kyo* 1989; 35: 1807–1809 [in Japanese].
11. Kagawa S, Takigawa H, Aga Y, et al: Metastatic tumor of the spermatic cord from gastric cancer. *Hinyokika Kyo* 1988; 34: 892–894 [in Japanese].
12. Schaefer IM, Sauer U, Liwocha M, et al: Occult gastric signet ring cell carcinoma presenting as spermatic cord and testicular metastases: “Krukenberg tumor” in a male patient. *Pathol Res Pract* 2010; 206: 519–521.
13. Chang TC, Changchien CC, Tseng CW, et al: Retrograde lymphatic spread: a likely route for metastatic ovarian cancers of gastrointestinal origin. *Gynecol Oncol* 1997; 66: 372–377.
14. Dutt N, Bates AW, Baithun SI: Secondary neoplasms of the male genital tract with different patterns of involvement in adults and children. *Histopathology* 2000; 37: 323–331.
15. Kocijan R, Sandberg S, Chan YW, et al: Anatomical changes after inguinal hernia treatment: a reason for chronic pain and recurrent hernia? *Surg Endosc* 2010; 24: 395–399.
16. Kouhia ST, Huttunen R, Silvasti SO, et al: Lichtenstein hernioplasty versus totally extraperitoneal laparoscopic hernioplasty in treatment of recurrent inguinal hernia — a prospective randomized trial. *Ann Surg* 2009; 249: 384–387.
17. Yang J, Tong da N, Yao J, et al: Laparoscopic or Lichtenstein repair for recurrent inguinal hernia: a meta-analysis of randomized controlled trials. *ANZ J Surg* 2013; 83: 312–318.
18. Yoshikawa T, Aoyama T, Watanabe T, et al: Role of surgical resection for scirrhous gastric cancer with minimal peritoneal metastasis. *Gan To Kagaku Ryoho* 2010; 37: 2264–2266 [in Japanese].
19. Kodera Y: Gastric cancer with minimal peritoneal metastasis: is this a sign to give up or to treat more aggressively? *Nagoya J Med Sci* 2013; 75: 3–10.

(Received, May 24, 2013)

(Accepted, June 7, 2013)