

Significance of Aggressive Surgery for an Invasive Carcinoma Derived from an Intraductal Papillary Mucinous Neoplasm Diagnosed Preoperatively as Borderline Resectable

Takayuki Aimoto¹, Satoshi Mizutani², Youichi Kawano¹,
Hideyuki Suzuki² and Eiji Uchida¹

¹Department of Surgery, Nippon Medical School

²Institute of Gastroenterology, Nippon Medical School Musashi Kosugi Hospital

Abstract

Purpose: We investigated the clinicopathological features of borderline resectable invasive carcinomas (BRICs) derived from intraductal papillary mucinous neoplasms (IPMNs) and examined the significance of the aggressive “surgery first” approach compared with the treatment of conventional borderline resectable pancreatic ductal adenocarcinomas (BRPDAs).

Patients and Methods: We retrospectively studied 7 patients with BRICs derived from IPMNs and 14 patients with conventional BRPDAs. Several factors were reviewed: initial symptoms, preoperative imaging, serum level of CA19-9, perioperative factors, pathological findings, adjuvant chemotherapy, and outcome.

Results: All BRICs derived from IPMN were huge tumors (more than 3 cm in diameter) suspected to involve <math><180^\circ</math> of the circumference of the vessel. Five patients (71%) underwent a modified Whipple procedure, and 2 (29%) underwent distal pancreatectomy. Only 3 patients (43%) required vascular resection. Curative resection was achieved in all 7 patients, who are alive with no evidence of recurrence. There were no severe postoperative complications. With regards to the pathological IPMN subtype, 2 tumors (29%) were gastric and 5 (71%) were intestinal. Only 2 patients (29%) had lymph node metastasis. The final stage was II in 4 (57%) cases and IVa in 3 cases (43%). The 3-year survival rate was 100%. Tumors of BRICs derived from IPMNs were larger than those of conventional BRPDAs ($p<0.05$). The BRICs derived from IPMN less frequently metastasized to lymph nodes ($p<0.05$) and were of an earlier stage ($p<0.05$) than were conventional BRPDAs. The 3-year survival rate was significantly higher for BRICs derived from IPMNs (100%) than for conventional BRPDAs (19%, $p<0.001$).

Conclusion: The BRICs derived from an intestinal or gastric IPMN are less aggressive than conventional BRPDAs and have a more favorable prognosis. In addition, aggressive “surgery first” approach may contribute to this better prognosis.

(J Nippon Med Sch 2013; 80: 371–377)

Key words: invasive carcinoma from intraductal tumor, aggressive surgery, borderline resectable cancer

Correspondence to Takayuki Aimoto, MD, Department of Surgery, Nippon Medical School, 1-1-5 Sendagi, Bunkyo-ku, Tokyo 113-8603, Japan

E-mail: aimoto@nms.ac.jp

Journal Website (<http://www.nms.ac.jp/jnms/>)

Introduction

Intraductal papillary mucinous neoplasms (IPMNs) are a spectrum of diseases ranging from adenoma to in-situ carcinoma, minimally invasive carcinoma and invasive carcinoma (IC) derived from IPMN and are generally associated with a favorable prognosis¹. It has been reported that the prognosis of ICs derived from IPMNs is similar to that of conventional pancreatic ductal adenocarcinomas (PDAs)¹. However, a recent report has demonstrated that ICs derived from IPMNs have a better prognosis than do conventional PDAs². In particular, it has been reported that the prognosis of ICs derived from an intestinal IPMN, even if it is massively invasive intraductal papillary mucinous carcinoma (IPMC), is significantly better than that of ICs derived from a nonintestinal IPMN or of conventional PDAs³⁻⁵.

The definition of borderline resectable pancreatic ductal adenocarcinoma (BRPDA) was proposed by Varadhachary et al.⁶ and adopted into the National Comprehensive Cancer Network guidelines in 2008⁷. According to these guidelines⁷, a BRPDA is defined as having a tumor abutment of <180° of the circumference of the superior mesenteric artery, short-segment abutment or encasement of the common hepatic artery (typically at the origin of the gastroduodenal artery), or segmental venous occlusion with the possibility of safe resection and reconstruction. Borderline resectable pancreatic cancer (BRPC) is a specific tumor condition in which the lesion appears to be resectable with currently available surgical techniques but is still at risk for a margin-positive resection that necessitates adjuvant chemotherapy^{8,9}. However, some patients do not receive the planned postoperative adjuvant therapy because of delayed surgical recovery or early tumor progression^{8,9}. On the other hand, no randomized trial has demonstrated the superiority of preoperative adjuvant therapy over postoperative adjuvant therapy¹⁰. As a result, controversy remains in the treatment strategy for BRPCs, especially the significance of the aggressive “surgery first” strategy.

Several studies have compared the prognosis of IPMNs and that of conventional pancreatic cancers^{2,3}. Furthermore, several studies have analyzed the prognosis of ICs derived from IPMNs, taking pathological factors, such as the IPMN subtype, into consideration³⁻⁵. However, no studies have compared the biological behavior and management of borderline resectable ICs (BRICs) derived from IPMNs with those of conventional BRPDAs. In this study, we investigated the clinicopathological features of BRICs derived from IPMNs and examined the significance of the aggressive “surgery first” approach compared with the treatment of conventional BRPDAs.

Patients and Methods

Patients

We retrospectively studied 7 patients with BRICs derived from IPMNs who underwent surgical resection at Nippon Medical School Hospital (Tokyo, Japan) from 2007 through 2010. We also analyzed the clinicopathological findings of 14 patients with conventional BRPDAs who underwent resection at our institution from 2007 through 2011. At the macroscopic level, all the patients underwent curative surgical resection. Clinical and follow-up information was obtained from patient charts. The end date of the follow-up program was May 31, 2013. Several factors were reviewed: initial symptoms, preoperative imaging, serum level of CA19-9, perioperative factors, pathological findings, adjuvant chemotherapy, and outcome.

Histological diagnosis of IPMNs was performed according to the World Health Organization classification system. The IPMNs were classified into the following 4 groups: gastric, intestinal, pancreatobiliary, and oncocytic. The invasive components of the IPMCs were classified as either tubular or colloid, and a colloid carcinoma was defined as a tumor consisting of colloid differentiation in 80% or more of the infiltrating carcinoma. Other pathological variables (lymph node metastasis, residual tumor, and stage) were recorded according to the classification system of the Japan

Table 1 Preoperative features

Patient	Age (years)	Sex	Initial symptom	Serum CA19-9 (IU/L)	Tumor on computed tomography		
					Location	Size (cm)	Involvement
1	66	F	none	<37	head	5×5	SMV
2	75	F	none	<37	body	3×4	CHA
3	72	F	icterus	<37	head	7×6	SMV
4	67	F	back pain	<37	head	5×4	PV
5	65	M	icterus	<37	head	4×2	SMV
6	75	F	icterus	216	head	3×3	PV, SMA
7	57	M	none	120	body	3×4	CA

- SMV: superior mesenteric vein, SMA: superior mesenteric artery
- PV: portal vein, CHA: common hepatic artery, CA: celiac artery

Table 2 Perioperative factors and postoperative complications

Patient	Surgery	Operation time (minutes)	Blood loss (mL)	Complications
1	SSPPD+PVsm	591	4,435	none
2	DP	354	530	none
3	SSPPD	400	3,200	none
4	SSPPD	301	235	none
5	PPPD	468	1,150	none
6	SSPPD+PVp	436	1,028	lymphorrhhea
7	DP-CAR	406	440	none
mean	-	408	1,574	-

- SSPPD: subtotal stomach-preserving pancreaticoduodenectomy
- PPPD: pylorus-preserving pancreaticoduodenectomy
- DP-CAR: distal pancreatectomy with celiac artery resection
- PVsm: resection of superior mesenteric vein
- PVp: resection of portal vein

Pancreas Society¹¹.

The study was approved by the ethics committee of Nippon Medical School and performed according to the Ethical Guidelines for Human Genome/Gene Research enacted by the Japanese Government and the principles embodied in the Declaration of Helsinki.

Statistical Analysis

The statistical analysis was performed with IBM SPSS Statistics version 20.0 (IBM Corp., Armonk, NY, USA), following the instructions of medical statistical articles^{12,13}. The Mann-Whitney U-test and Fisher's exact test or the χ^2 test was used to evaluate the differences between clinicopathological variables. Survival curves were calculated with the Kaplan-Meier method, and survival rates were compared by means of the log-rank test. Statistical

significance was indicated by $p < 0.05$.

Results

Preoperative Features (Table 1)

Three patients (43%) showed obstructive jaundice. The serum level of CA19-9 was high in only 2 patients (29%) preoperatively and decreased rapidly after surgery in both patients. According to preoperative imaging, all cases involved a huge tumor (over 3 cm in size) suspected of involving <180° of the circumference of the vessel. All 7 patients received a diagnosis of BRIC derived from IPMN.

Perioperative Factors and Postoperative Complications (Table 2)

Five patients (71%) underwent a modified Whipple

Table 3 Pathological findings

Patient	Subtype	Invasive type	Lymph node metastasis	Stage	Residual tumor (R)
1	gastric	tubular	negative	IVA	R0
2	intestinal	tubular	negative	II	R0
3	intestinal	colloid	negative	II	R0
4	intestinal	colloid	negative	II	R0
5	gastric	tubular	negative	II	R0
6	intestinal	tubular	positive	IVA	R0
7	intestinal	tubular	positive	IVA	R0

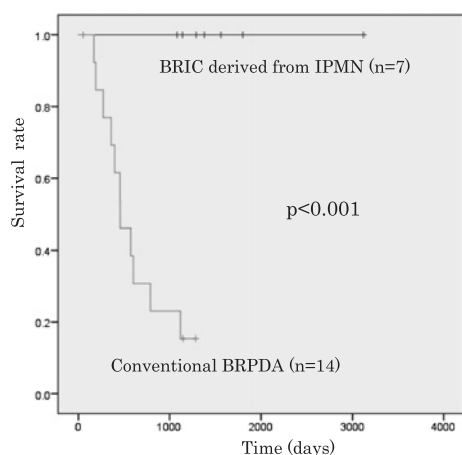


Fig. 1 Kaplan-Meier survival curves for patients with BRICs derived from IPMN and with conventional BRPDAs

procedure, and 2 (29%) underwent distal pancreatectomy. Only 3 patients (43%) required vascular resection or reconstruction or both. The mean time of the procedure was 408 minutes, with a mean blood loss of 1,574 mL. There were no severe postoperative complications.

Pathological Findings (Table 3)

With regard to the type of IPMN, 2 tumors (29%) were gastric, and the other 5 (71%) were intestinal. There were no oncocytic or pancreatobiliary tumors. The major component in the invasive area was a colloid carcinoma in 2 cases (29%) and a tubular carcinoma in 5 cases (71%). Only 2 patients (29%) had lymph node metastasis. The final stage was II in 4 cases (57%) and IVa in 3 cases (43%). Curative resection was achieved in all cases.

Clinical Outcomes

Three patients (43%) were not given adjuvant gemcitabine-based chemotherapy because they refused therapy and had delayed liver dysfunction. At the present time, all patients are alive with no evidence of recurrence. The 3-year survival rate was 100% (Fig. 1).

Comparison between BRIC Derived from IPMN and Conventional BRPDA

There was no significant difference between the 2 groups with regard to patient background, including age, sex, tumor location, and the procedure (Table 4). The conventional BRPDAs included 12 tubular adenocarcinomas, 1 mucinous carcinoma, and 1 poorly differentiated carcinoma.

Table 4 shows the clinicopathological findings of both groups. Tumors in patients with BRICs derived from IPMNs were larger than those in patients with conventional BRPDAs ($p < 0.05$), although serum CA19-9 levels were more frequently elevated in patients with conventional BRPDAs ($p < 0.05$). Only 3 patients with BRICs derived from IPMNs required vascular resection, despite a preoperative diagnosis of borderline resectable cancer. However, all patients with a conventional BRPDA underwent partial resection of major vessels ($p < 0.05$). The operation time was shorter in patients with BRICs derived from IPMNs ($p < 0.05$), but no significant difference was found in blood loss. Lymph node metastasis occurred less frequently in patients with BRICs derived from IPMNs ($p < 0.05$). Patients with BRICs derived from IPMNs had tumors at an earlier stage than did patients with a conventional BRPDA ($p < 0.05$). There was no significant difference between

Table 4 Clinicopathological findings of BRIC derived from IPMN and BRPDA

		BRIC derived from IPMN (n=7)	BRPDA (n=14)	<i>p</i>
Age (years)	mean	68.1	69.3	NS
	SD	6.4	9	
Sex	M	2	8	NS
	F	5	6	
Serum CA19-9 (IU/L)	<37	2	13	0.05
	>37	5	1	
Location	head	5	14	NS
	body	2	0	
Size (cm)	mean	3.7	2.8	0.05
	SD	0.4	1.1	
Surgery	PD+modified PD	5	14	NS
	DP+DP-CAR	2	0	
Vascular resection	+	3	14	0.05
	-	4	0	
Operation time (minutes)	mean	422.3	508.3	0.05
	SD	92.1	86.2	
Blood loss (mL)	mean	1,574	1,592.2	NS
	SD	1,606	936.2	
lymph node metastasis	+	2	12	0.05
	-	5	2	
Stage	II	4	0	0.05
	III	0	3	
	IVa	3	11	
Residual tumor (R)	R0	7	11	NS
	R1	0	4	
Adjuvant chemotherapy	+	4	11	NS
	-	3	3	

PD=pancreaticoduodenectomy; DP=distal pancreatectomy; CAR=celiac artery resection

the groups with regard to residual tumor or adjuvant chemotherapy.

The 3-year survival rate was significantly higher for patients with BRICs derived from IPMNs (100%) than for patients with conventional BRPDAs (19%, $p<0.001$) (**Fig. 1**).

Discussion

In the present study, we compared the clinicopathological features and outcomes of BRICs derived from IPMNs and of conventional BRPDAs. We found that BRICs derived from IPMNs were less aggressive than conventional BRPDAs and had a more favorable prognosis. In addition, we found that the aggressive “surgery first” approach may contribute to this better prognosis.

A BRIC derived from an intestinal or gastric IPMN is less aggressive than other types of IC and

consequently presents at an earlier stage than is indicated by preoperative radiologic imaging. First, a BRIC derived from an intestinal or gastric IPMN may simply be less invasive and expansive. Although preoperative imaging revealed a huge tumor (greater than 3 cm in diameter) adhering to the common hepatic artery, portal vein, or superior mesenteric vein in 4 of the 7 cases, the major vessel was able to be completely separated from the primary tumor so that vascular resection was unnecessary. Moreover, pathological examination found no evidence of vascular involvement. Second, a BRIC derived from an intestinal or gastric IPMN tends to have a lower incidence of lymph node metastasis. In the present study, 5 of the 7 cases showed no evidence of lymph node metastasis, regardless of the huge size of the primary tumor. Consequently, the final stage, as determined with intraoperative and pathological findings, appears to

be earlier than the clinical stage diagnosed with preoperative imaging. In 4 of 6 cases, the final stage was found to be II, despite the preoperative clinical stage being IVa. Adsay et al.¹⁴ have noted that an intestinal IPMN may have a distinct indolent pathway of carcinogenesis which induces a lesser degree of invasiveness. On the other hand, most gastric IPMNs show low-grade dysplasia and are rarely associated with invasive cancer¹⁵. An IPMN originating in branch ducts often shows gastric-type differentiation and has a less aggressive clinical course¹⁵. Takasu et al.⁴ have concluded that the intestinal or gastric IPMNs have lower malignant potential than do pancreatobiliary IPMNs because of their less invasive nature and slower growth pattern. Furthermore, the less aggressive behavior of a BRIC derived from an intestinal or gastric IPMN may be inherited from the type of IPMN itself. Nakata et al.³ have shown that an IC derived from an intestinal IPMN displays the minimally invasive form and less aggressive nature of the local disease in relation to lymphatic and peripancreatic infiltration. In addition, Partelli et al.¹⁶ have reported that the rate of lymph node metastasis from IPMNs ranges from 29% to 46% and is significantly lower than the 50% to 60% rate from ordinary pancreatic cancers.

The present study found that the prognosis of patients with a BRIC derived from an intestinal or gastric IPMN was significantly better than that of patients with a conventional BRPDA because a BRIC from an IPMN was less aggressive. Indeed, the 3-year survival rate was 100% in cases of BRIC derived from IPMN and only 19% in cases of conventional BRPDA. The less aggressive nature of the BRIC derived from IPMN was verified by our findings that the rate of vascular involvement and the rate of lymph node metastasis were significantly lower than for conventional BRPDA. In addition, it is surprising that all 3 patients who had vascular invasion or lymph node metastasis or both were still alive 3 years after surgery. Sadakari et al.⁵ have shown that patients with ICs derived from intestinal IPMNs had favorable outcomes, whereas conventional PDAs were significantly associated with poor outcomes. Yamaguchi et al.² have also

reported that ICs derived from IPMNs have more favorable biological behaviors and a better prognosis than do ordinary pancreatic cancers.

The aggressive “surgery first” approach for BRICs derived from an intestinal or gastric IPMN may contribute to the favorable prognosis. First, curative resection was able to be performed for BRICs derived from intestinal or gastric IPMNs more frequently than for conventional BRPDAs and led to favorable outcomes without recurrence or metastasis. Indeed, all patients underwent curative surgery and survived for 3 years after surgery. In cases of conventional BRPDA, local failure and distant metastasis, even if curatively addressed, tend to develop soon after surgery because of the highly invasive and expansive behavior of the condition^{6,10}. In contrast, long-term survival rate for a completely resected IPMN is markedly higher than that for a PDA¹⁷. Adsay et al.¹⁸ have also noted that even when malignant, most intraductal papillary mucinous tumors are often resectable and have a more favorable prognosis than do PDAs. Second, it is uncertain whether adjuvant chemotherapy helps improve the prognosis of BRICs derived from IPMNs. In the present study, 3 patients (42%) who did not undergo adjuvant treatment were still alive 3 years after surgery without any local recurrence or distant metastasis. Gemcitabine-based adjuvant chemotherapy for a PDA is generally associated with a prolonged postoperative survival time. Although adjuvant treatment should be administered to patients with a BRIC derived from IPMN as well as to patients with a conventional BRPDA, curative resection is considered more important for prolonging survival in a patient with a BRIC derived from an intestinal or gastric IPMN and may be a better predictor of a favorable outcome.

The present study was retrospective and involved a small cohort of patients. Moreover, the study included no patients with a BRIC derived from a pancreatobiliary or oncocystic IPMN. Therefore, further investigation with a larger group of patients, including those with nonintestinal IPMNs, is needed to fully investigate the clinicopathological characteristics and prognosis of BRIC derived from

all types of IPMN.

In conclusion, BRICs derived from an intestinal or gastric IPMN are less aggressive than conventional BRPDAs and have a more favorable prognosis. In addition, the aggressive “surgery first” approach may contribute to this better prognosis.

Conflict of Interest: All the authors in this paper declare no conflict of interest.

References

1. Sakorafas GH, Sarr MG, van de Velde CJ, Peros G: Intraductal papillary mucinous neoplasms of the pancreas: a surgical perspective. *Surg Oncol* 2005; 14: 155-178.
2. Yamaguchi K, Kanemitsu S, Hatori T, et al: Pancreatic ductal adenocarcinoma derived from IPMN and pancreatic ductal adenocarcinoma concomitant with IPMN. *Pancreas* 2011; 40: 571-580.
3. Nakata K, Ohuchida K, Aishima S, et al: Invasive carcinoma derived from intestinal-type intraductal papillary mucinous neoplasm is associated with minimal invasion, colloid carcinoma, and less invasive behavior, leading to a better prognosis. *Pancreas* 2011; 40: 581-587.
4. Takasu N, Kimura W, Moriya T, et al: Intraductal papillary-mucinous neoplasms of the gastric and intestinal types may have less malignant potential than the pancreatobiliary type. *Pancreas* 2010; 39: 604-610.
5. Sadakari Y, Ohuchida K, Nakata K, et al: Invasive carcinoma derived from the nonintestinal type intraductal papillary mucinous neoplasm of the pancreas has a poorer prognosis than that derived from the intestinal type. *Surgery* 2010; 147: 812-817.
6. Varadhachary GR, Tamm EP, Abbruzzese JL, et al: Borderline resectable pancreatic cancer: definitions, management, and role of preoperative therapy. *Ann Surg Oncol* 2006; 13: 1035-1046.
7. Vauthey JN, Dixon E: AHPBA/SSO/SSAT Consensus Conference on Resectable and Borderline Resectable Pancreatic Cancer: rationale and overview of the conference. *Ann Surg Oncol* 2009; 16: 1725-1726.
8. Lloyd S, Chang BW: A comparison of three treatment strategies for locally advanced and borderline resectable pancreatic cancer. *J Gastrointest Oncol* 2013; 4: 123-130.
9. Sharma J, Ng J, Goodman MD, Saif MW: New developments in the management of borderline resectable pancreatic cancer. *JOP* 2013; 14: 123-125.
10. Jia Y, Wang TJ, Allendorf J, Saif MW: Management of borderline resectable pancreatic adenocarcinoma. *JOP* 2012; 13: 147-150.
11. Japanese Pancreas Society: General rules for the study of pancreatic cancer (The 6th Edition), 2009; Kinpara-syuppan, Tokyo.
12. Watanabe H: Applications of Statistics to Medical Science, II Overview of Statistical Procedures for General Use. *J Nippon Med Sch* 2012; 79: 31-36.
13. Watanabe H: Applications of Statistics to Medical Science, III Correlation and Regression. *J Nippon Med Sch* 2012; 79: 115-120.
14. Adsay NV, Merati K, Basturk O, et al: Pathologically and biologically distinct types of epithelium in intraductal papillary mucinous neoplasms: delineation of an “intestinal” pathway of carcinogenesis in the pancreas. *Am J Surg Pathol* 2004; 28: 839-848.
15. Jang JY, Hwang DW, Kim MA, et al: Analysis of prognostic factors and a proposed new classification for invasive papillary mucinous neoplasms. *Ann Surg Oncol* 2011; 18: 644-650.
16. Partelli S, Fernandez Del Castillo C, Bassi C, et al: Invasive intraductal papillary mucinous carcinomas of the pancreas: predictors of survival and the role of lymph node ratio. *Ann Surg* 2010; 251: 477-482.
17. Woo SM, Ryu JK, Lee SH, et al: Survival and prognosis of invasive intraductal papillary mucinous neoplasms of the pancreas: comparison with pancreatic ductal adenocarcinoma. *Pancreas* 2005; 36: 50-55.
18. Adsay NV: Cystic neoplasia of the pancreas: pathology and biology. *J Gastrointest Surg* 2008; 12: 401-404.

(Received, July 3, 2013)

(Accepted, July 26, 2013)