

Abstracts of Outstanding Presentation of the 81st Annual Meeting of the Medical Association of Nippon Medical School

Date: September 7, 2013 Place: Nippon Medical School

Abstracts of Outstanding Presentation (1)

Experience with Local Injection of Minocycline Hydrochloride for Refractory Inguinal Lymphorrhea

Naotaka Serizawa, Koichiro Oki, Shunichi Nomoto, Shinpei Nara,
Hiroki Umezawa, Noriko Matsumoto, Hideyuki Mitsuwa and Hiko Hyakusoku

Department of Plastic, Reconstructive, and Aesthetic Surgery, Nippon Medical School Hospital

Introduction

Lymphorrhea is a frequent complication of such procedures as lymph node dissection; however, effective treatments for lymphorrhea remain unclear. We performed local injection of minocycline hydrochloride in 2 patients with lymphorrhea unresponsive to conservative treatments, such as local compression and administration of basic fibroblast growth factor, and achieved good results. Local injection of minocycline hydrochloride is often used for adhesion in other departments, and severe side effects have not been reported.

Materials and Methods

Patient 1 was a 58-year-old man. After biopsy of right inguinal lymph nodes to evaluate bilateral inguinal lymphadenopathy, lymphorrhea developed in the right groin. Conservative treatment for 13 days produced no improvement. Patient 2 was a 71-year-old woman. After catheterization to treat arterial occlusion of both lower extremities, lymphorrhea developed in the right groin. Conservative treatment for 17 days produced no improvement. In both cases, ribbon gauze was packed into the wound, and 100 mg of minocycline hydrochloride dissolved in 10 mL of saline was injected into the gauze. The gauze was replaced daily.

Results

In patient 1, the exudate began to decrease on the fourth day and had resolved by the seventh day. Local injection therapy was stopped on the 11th day, and treatment with both gentamicin sulfate and alprostadiil alfadex ointment was continued. Wound closure was achieved on the 21st day (**Fig. 1**). In patient 2, the wound showed granulation from the third day, and the exudate began to decrease on the fifth day. Local injection therapy was stopped on the 10th day. Treatment with trafermin, gentamicin sulfate ointment, and alprostadiil

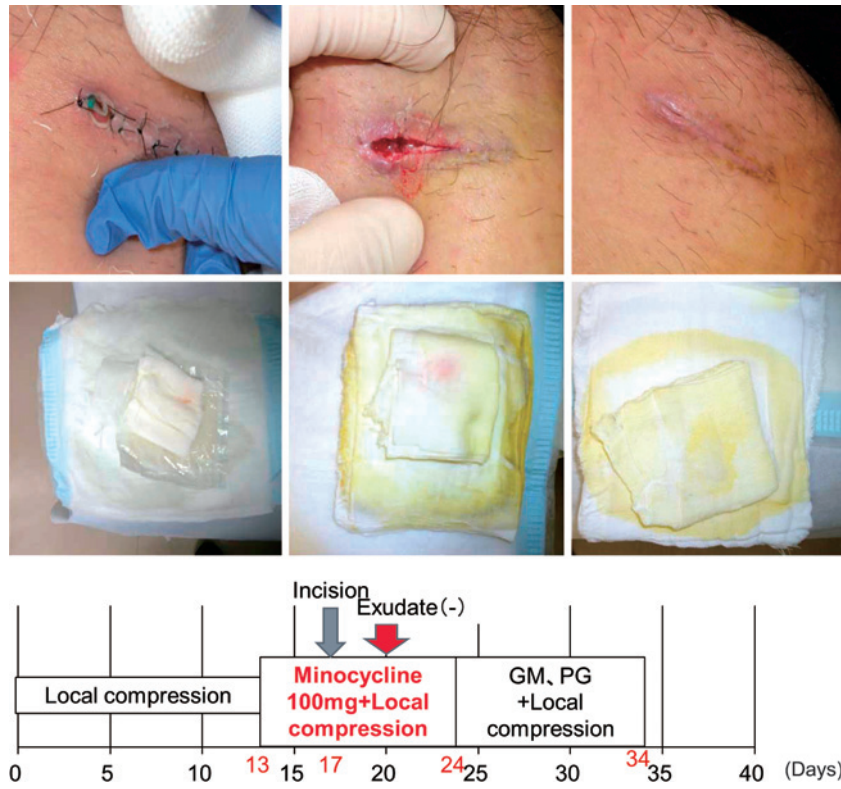


Fig. 1 Clinical course of patient 1
 GM: Gentamicin Sulfate Ointment PG: Alprostadii Alfadex Ointment

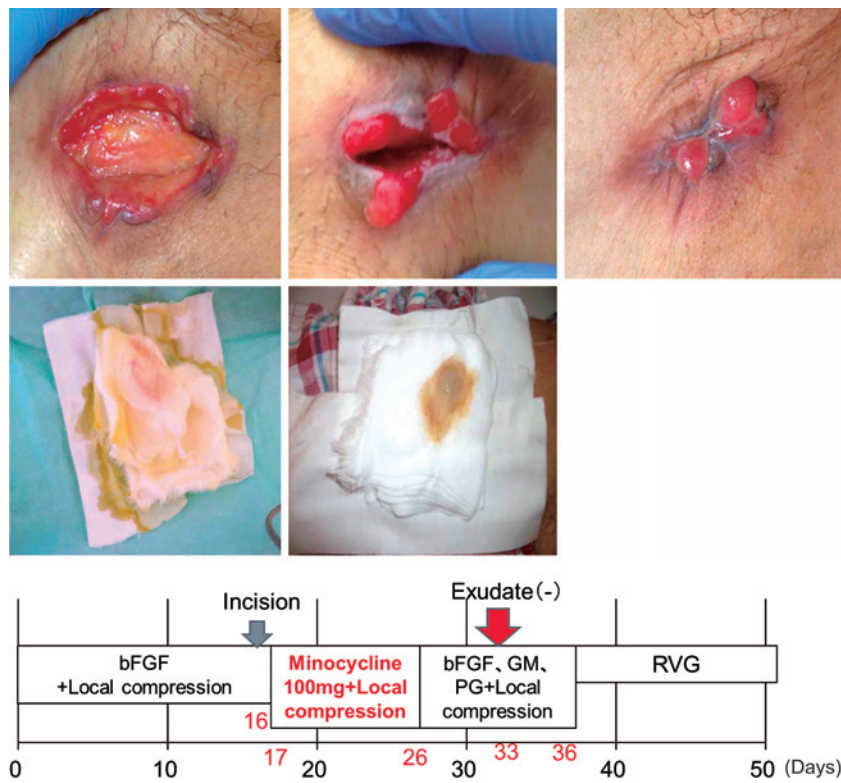

Fig. 2 Clinical course of patient 2
 GM: Gentamicin Sulfate Ointment PG: Alprostadii Alfadex Ointment bFGF: Trafermin spray RVG: Betamethasone Valerate·Gentamicin Sulfate Ointment

alfadex ointment was continued. Because exuberant granulation occurred on the 20th day, treatment was changed to betamethasone valerate. Wound closure was achieved on the 35th day (**Fig. 2**).

Conclusion

For refractory inguinal lymphorrhea, local injection therapy with minocycline hydrochloride proved successful. In addition, marked formation of granulation tissue was recognized, suggesting the effectiveness of soft tissue in wound healing. We have found no previous reports in the literature of local injection therapy using minocycline hydrochloride for intractable cutaneous ulcer. This approach should be considered for the treatment of intractable ulcers.
