

## Excision of Zenker's Diverticulum to Treat Dysphagia Associated with Acute-phase Cerebral Infarction

Arata Abe, Mina Harada-Abe, Yohei Takayama,  
Yusuke Toda, Masayuki Ueda and Yasuo Katayama

Department of Neurological Science, Graduate School of Medicine, Nippon Medical School

### Abstract

A 75-year-old man was admitted to our hospital with dysphagia shortly after the onset of a brainstem infarction. Videofluorography indicated the presence of a Zenker's diverticulum with a bolus at the esophageal orifice; endoscopy 5 years earlier had not shown a Zenker's diverticulum and suggests that the diverticulum had formed because of an increase in the hypopharyngeal pressure caused by the brainstem infarction. Surgical excision successfully facilitated transport of the bolus to the esophageal orifice. In the present report, we describe a case of dysphagia caused by a Zenker's diverticulum following and associated with a brain infarction.

(J Nippon Med Sch 2014; 81: 164–167)

**Key words:** cerebral infarction, diverticulum, dysphagia

### Introduction

The clinical appearance of Zenker's diverticulum may range from complete absence of any symptoms to life-threatening consequences, such as respiratory infections, aspiration pneumonia, and severe cachexia<sup>1</sup>. Zenker's diverticulum is a herniation of the pharyngeal mucosa, between the oblique and horizontal fibers of the inferior constrictor muscle, at an anatomical weak spot known as Killian's dehiscence. Within this region, the mucosa protrudes dorsally through the oblique fibers of the pharyngeal constrictor muscle and above the transverse fibers of the cricopharyngeal muscle<sup>2</sup>. A widely accepted explanation for the formation of Zenker's diverticulum is the increased bolus pressure that

forms as a result of a malfunction of the upper esophageal sphincter, involving spasms, lack of relaxation during swallowing, and premature contraction<sup>3,4</sup>. No information is available regarding the dysphagia caused by the brain infarction-associated development of Zenker's diverticulum.

### Case Report

A 75-year-old Japanese man was admitted to our hospital after the onset of abnormal gait and dysarthria. The patient had been found to have hypertension and diabetes 15 years and 1 year before admission, respectively, for which he was being treated with amlodipine and glimepiride. Five years before admission, an upper gastrointestinal endoscopic examination had not revealed any

---

Correspondence to Arata Abe, MD, PhD, Department of Neurological Science, Graduate School of Medicine, Nippon Medical School, 1-1-5 Sendagi, Bunkyo-ku, Tokyo 113-8603, Japan  
E-mail: abe@nms.ac.jp  
Journal Website (<http://www.nms.ac.jp/jnms/>)

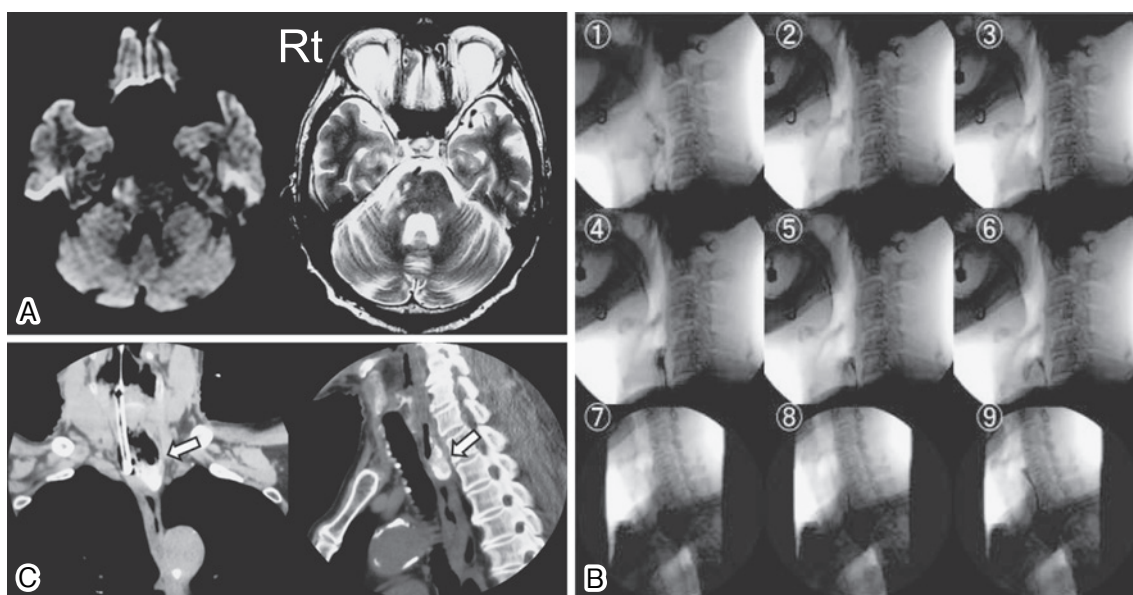


Fig. 1 **A:** A brain magnetic resonance imaging scan showing a distinct signal in the region of the pontomedullary junction, adjacent to the pons, in a diffusion-weighted image (left), and a distinct, but weaker, signal in the same region on the T2-weighted image (right). **B:** Videofluorography images, obtained 13 days after admission, showing that contrast medium-labeled, gel-based food enters the esophageal area and returns to the esophageal orifice instead of moving to the stomach (1–6), as demonstrated by the deposition of the contrast medium in the Zenker's diverticulum (7–9), while the bolus is partially passed down to the lower esophageal area. **C:** A chest computed tomography scan showing the presence of the Zenker's diverticulum in the right portion (**arrow**) of the upper esophagus.

abnormalities. At admission, the patient's baseline characteristics were: blood pressure, 162/92 mm Hg; pulse rate, 69 beats/minute; respiratory rate, 12 breaths/minute; body temperature, 36.5°C; height, 155 cm; weight, 40 kg; body mass index, 16.6 kg/m<sup>2</sup>; low-density lipoprotein and high-density lipoprotein cholesterol levels, 155 mg/dL and 40 mg/dL, respectively; fasting blood glucose level, 110 mg/dL; and hemoglobin A1c level, 10.9%. Findings of a neurological examination were a Glasgow Coma Scale score of E4V5M6, left central facial palsy, and anesthesia of the right side of the face and the left side of the body. In addition, right ataxia, dysarthric, hiccups, and increased all left deep tendon reflexes, without any other pathological reflexes, were observed.

Diffusion-weighted brain magnetic resonance imaging showed a distinct signal from the pontomedullary junction, adjacent to the pons (**Fig. 1A**). Cerebral infarction was diagnosed, and the patient received antithrombotic medication. Because the patient did not show signs of difficulty during

repeated swallowing tests with saliva, water, and gel-based food on admission, he resumed a normal diet the next day. However, on the following day, food intake was discontinued because of aspiration pneumonia. A magnetic resonance imaging scan of the brain showed no recurrence or enlargement of the brain infarction.

Videofluorography, performed 13 days after admission, showed no abnormalities during the oral phase of swallowing but did show a minor degree of dysphagia during the pharyngeal phase. The contrast medium-labeled, gel-based food reached the esophageal orifice and formed a mass that was not transported to the stomach but returned to the orifice instead (**Fig. 1B**). Magnification of the upper esophageal area, through videofluorography, indicated that the contrast medium-labeled food was deposited at the junction of the pharyngoesophageal posterior site and the esophageal area, where a Zenker's diverticulum had formed<sup>5</sup>. Immediately after videofluorography, computed tomography was performed to examine the neck-to-chest region.

Computed tomography indicated a Zenker's diverticulum projecting posteriorly and leftward (**Fig. 1C**); this finding was then confirmed with upper esophageal endoscopy. After the procedure and during follow-up, the patient received central venous nutrition.

Another videofluorography test, performed 2 weeks after Zenker's diverticulum was detected (27 days after admission), showed reversed flow between the esophagus and pharynx. Videofluorography performed after an additional 4 weeks (60 days after admission) showed a similar abnormality. Because the patient could not eat, the Zenker's diverticulum was excised after informed consent was obtained. The diverticulum was excised via a transcervical open technique with an oblique cervical incision, in the middle third of the left side of his neck, at the anterior border of the left sternocleidomastoid muscle. After the pouch was identified, the sac was resected at the neck of the pouch, and the hypopharyngeal mucosa was closed with inverted sutures. Although the patient had been unable to eat for 60 days after admission, once the Zenker's diverticulum was removed, he was able to resume eating and returned home within 10 days.

### Discussion

In the present case, we could not determine whether the Zenker's diverticulum had resulted from the onset of the cerebral infarction or whether it had caused the cerebral infarction-associated dysphagia. The patient likely did not have the Zenker's diverticulum 5 years earlier because an upper gastrointestinal endoscopic examination at that time had not revealed any abnormalities. Thus, we suspect that the infarction led to the incomplete opening of the upper esophageal sphincter and that the increased hypopharyngeal pressure resulted in the formation of the Zenker's diverticulum, leading to the dysphagia. The formation of Zenker's diverticulum involves an increase in the esophageal pressure, although increased abdominal pressure, due to overeating, was not observed<sup>6</sup>. In the present case, brain infarction occurred on the right side, but the Zenker's diverticulum occurred on the left side.

In general, brain infarction and Zenker's diverticulum occur on the same side. However, no information is available regarding an infarction of the brain causing an ipsilateral increase in hypopharyngeal pressure. The development of a contralateral Zenker's diverticulum may have been due to some fragility of the left side of the esophagus. Walters et al.<sup>7</sup> reviewed 12 cases of Zenker's diverticulum in patients 60 years or older and suggest that Zenker's diverticulum is a manifestation of central or peripheral neurologic disease, such as cerebral infarction, in the elderly. Moreover, Higo et al.<sup>8</sup> have demonstrated incomplete opening of the upper esophageal sphincter and elevation of oropharyngeal and hypopharyngeal pressures in patients after medullary cerebrovascular accidents. Their results suggest that a misprogrammed excitatory output from the central pattern generators of the brainstem, particularly the nucleus tractus solitarius and the nucleus ambiguus solitaries in the medulla, would cause an abnormal pressure-traveling pattern during pharyngeal swallowing. However, our patient had nonmedullary ischemia. Because the nucleus tractus solitarius is projected up to the pontomedullary junction, these disorders may have occurred in the present case; however, little is known about the esophageal phase of swallowing and its involvement in the formation of Zenker's diverticulum. A study in cats has found that the nucleus tractus solitarius, as well as the nucleus ambiguus, is involved in the contraction and relaxation of the lower esophageal sphincter<sup>9,10</sup>, but no information is available regarding this relevance to humans.

In the present case, the Zenker's diverticulum may have formed 13 days after the onset of the cerebral infarction. However, how it developed so quickly is not clear and requires further investigation.

In conclusion, a videofluorography test to determine the presence of dysphagia due to Zenker's diverticulum should be performed after cerebral infarction. In patients found to have a Zenker's diverticulum, surgery should be performed immediately to excise it.

**Conflict of Interest:** The authors have no competing interests. All authors have no financial relationships to disclose.

### References

1. Peters JH, Mason R: [The physiopathological basis for Zenker's diverticulum]. *Chirurg* 1999; 70: 741-746.
2. Kilian G: Über den Mund in die Speiseröhre. *Z Ohrenheilkunde* 1908; 55: 7-33.
3. Halama AR: Surgical treatment of swallowing disorders. *Acta Oto Rhino Laryngological Belg* 1994; 48: 217-227.
4. McConnel FM, Hood D, Jackson K, O'Connor A: Analysis of intrabolus forces in patients with zenker's diverticulum. *Laryngoscope* 1994; 104: 571-581.
5. Van Overbeek JJ: Pathogenesis and methods of treatment of Zenker's diverticulum. *Ann Otol Rhinol Laryngol* 2003; 112: 583-593.
6. Shinozuka E, Nomura T, Miyashita M, et al: Successful treatment of a spontaneous esophageal rupture in an elderly patient: a case report. *J Nippon Med Sch* 2010; 77: 338-341.
7. Walters DN, Battle JW, Portera CA, Blizzard JD, Browder IW: Zenker's diverticulum in the elderly: a neurologic etiology? *Am Surg* 1998; 64: 909-911.
8. Kim JS: Pure lateral medullary infarction: clinical-radiological correlation of 130 acute, consecutive patients. *Brain* 2003; 126: 1864-1872.
9. Rossiter CD, Norman WP, Jain M, et al: Control of lower esophageal sphincter pressure by two sites in dorsal motor nucleus of the vagus. *Am J Physiol* 1990; 259: 899-906.
10. Lang IM, Dean C, Medda BK, et al: Differential activation of medullary vagal nuclei during different phases of swallowing in the cat. *Brain Res* 2004; 1014: 145-163.

(Received, June 18, 2013)

(Accepted, August 19, 2013)