

## Successful Treatment of Gastroparesis with the Antidepressant Mirtazapine: A Case Report

Junmin Song<sup>1</sup>, Nan Lin<sup>2</sup>, Feng Tian<sup>1</sup>,  
Yang Li<sup>3</sup> and Yan Li<sup>1</sup>

<sup>1</sup>Department of Gastroenterology, Shengjing Hospital of China Medical University, China

<sup>2</sup>Department of Radiology, Shengjing Hospital of China Medical University, China

<sup>3</sup>Department of Intensive Care Unit, Shengjing Hospital of China Medical University, China

### Abstract

Treatments for gastroparesis have been unsatisfactory. We describe a patient with gastroparesis who did not respond to a series of conventional prokinetic treatments. Finally, an antidepressant, mirtazapine, was administered, and the patient's symptoms and gastric emptying showed surprisingly rapid improvement. Therefore, we recommend mirtazapine as a treatment for gastroparesis refractory to conventional treatments.

(J Nippon Med Sch 2014; 81: 392–394)

**Key words:** gastroparesis, mirtazapine, antidepressant

### Introduction

Gastroparesis is a common syndrome caused by delayed gastric emptying rather than mechanical obstruction of the gastric outlet. Its symptoms include nausea, vomiting, and postprandial epigastric fullness or early satiety. Gastroparesis can occur in patients with diabetes mellitus, severe pancreatitis, abdominal malignancy, or connective tissue disease or patients who have had abdominal surgery, but the idiopathic variant is the most common. Conventional treatment options include fasting, prokinetic agents, acupuncture, and gastric electrical stimulation.

### Case

A 65-year-old man was admitted first to a hospital because of cholecystolithiasis and cholecystitis. Shortly after undergoing laparoscopy-assisted cholecystectomy, the patient presented with abdominal pain and elevated serum levels of amylase (543.0 U/L; normal, 40 to 129 U/L) and lipase (531.2 U/L; normal, <60 U/L). Contrast-enhanced computed tomography revealed effusions and bubbles around an edematous pancreas (**Fig. 1a**). On the basis of these findings, acute pancreatitis was diagnosed. After 2 weeks of treatment, the signs of pancreatitis had improved. However, the patient began to have nausea, vomiting, epigastric fullness, and mild epigastric discomfort.

The patient was referred to our hospital for

---

Correspondence to Junmin Song, Department of Gastroenterology, Shengjing Hospital of China Medical University, No. 36 Sanhao Street, Heping District, Shenyang, Liaoning 110004, People's Republic of China  
E-mail: songdoctor@sina.com  
Journal Website (<http://www.nms.ac.jp/jnms/>)

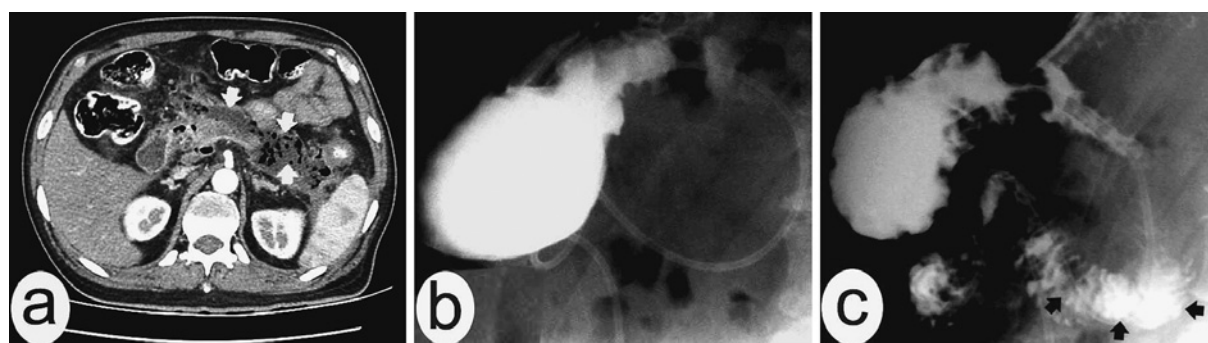


Fig. 1 Diagnostic findings of this patient. Contrast-enhanced computed tomography revealed effusions and bubbles (**white arrows**) around an edematous pancreas (a); gastrointestinal radiography before mirtazapine treatment revealed little passage of contrast agent into the lumen of duodenum 10 minutes after intake (b); gastrointestinal radiography after mirtazapine treatment revealed emptying of an appreciable amount of contrast agent into the lumen of duodenum (**black arrows**) 3 minutes after intake (c).

further evaluation and treatment. Gastrointestinal radiography with meglumine diatrizoate revealed minimal-to-absent gastric peristalsis and little passage of contrast agent into the lumen of the duodenum (**Fig. 1b**). Endoscopic examination excluded mechanical obstruction of gastric outlet. On the basis of these findings gastroparesis was diagnosed. Because the patient had undergone abdominal surgery and had pancreatitis, various factors were thought to have contributed to the development of gastroparesis.

During the next 3 months, a series of treatments, including oral domperidone (10 mg thrice daily), oral itopride (50 mg thrice daily), oral mosapride (5 mg thrice daily), intramuscular metoclopramide (10 mg twice daily), intravenous erythromycin (0.6 g twice daily), Chinese herbal medicines, and acupuncture, were tried successively. In addition, nutrition was supplemented through a nasojunal tube, and a nasogastric tube was used to prevent aspiration. However, none of these treatments proved effective.

Because psychiatric evaluation had revealed mild anxiety and depression, an antidepressant, mirtazapine, was administered orally (with an initial dosage of 15 mg/day and a maintenance dosage of 30 mg/day, starting 4 days later). Surprisingly, the patient's symptoms quickly improved, and the volume of aspirates from nasogastric tube decreased. He had no discomfort after intaking fluids 1 week later or intaking appreciable meals 2 weeks later. At the end of 3 weeks of treatment with mirtazapine, gastrointestinal radiography revealed moderate

gastric peristalsis, with a rate of 3 to 5 times/minute, and emptying of an appreciable amount of contrast agent into the lumen of duodenum (**Fig. 1c**), and psychiatric evaluation revealed approximately normal condition. The patient was discharged from our hospital, and the symptoms did not relapse during 6 months of follow-up.

## Discussion

Gastroparesis is characterized by decreased gastric motility. Therefore, prokinetic drugs remain the primary treatment, but their effectiveness is unsatisfactory. Over the years, tricyclic antidepressants, e.g., amitriptyline and imipramine, have been used to treat gastroparesis. However, because of their adverse effects, tricyclic antidepressants are usually not the initial treatment<sup>1</sup>. Therefore, the efficacy and safety of other antidepressants should also be evaluated.

Mirtazapine, a noradrenergic and specific serotonergic antidepressant, functions by stimulating 5-hydroxytryptamine (HT) 1 receptors and inhibiting 5-HT<sub>2</sub>/5-HT<sub>3</sub> receptors postsynaptically and has mild adverse effects. The remarkable improvements in symptoms and gastric emptying in the present case suggest that mirtazapine has beneficial effects in the treatment of gastroparesis and are consistent with several previous reports<sup>2-4</sup>. Although the exact mechanism of improvement remains unclear, mirtazapine is thought to have contributed to symptom relief and improvement of gastric

emptying or both in various ways. First, because higher depression and anxiety scores are associated with greater symptom severity in gastroparesis<sup>5</sup>, the antidepressant and anxiolytic effects of mirtazapine contribute to symptom relief. Second, the inhibition of central postsynaptic 5-HT<sub>3</sub> receptors has a potent antiemetic effect, and in this sense, mirtazapine exerts the same pharmacological activity as the well-known antiemetic ondansetron. Third, because gastroparesis is associated with visceral hypersensitivity<sup>6</sup>, ameliorating effects of mirtazapine on visceral hypersensitivity and response to stimuli<sup>7</sup> are also involved in symptom relief. Fourth, because high-dose mirtazapine improves gastric emptying in rats with visceral hypersensitivity<sup>7</sup>, mirtazapine might also improve gastric emptying in patients with gastroparesis.

In conclusion, mirtazapine appears to be an effective treatment for gastroparesis. Therefore, mirtazapine might be used for patients with gastroparesis refractory to conventional treatments. However, the efficacy and mechanism of action of mirtazapine (or other antidepressants) in the treatment of gastroparesis require further study.

**Conflict of Interest:** The authors have no conflicts of interest to declare.

## References

1. Stapleton J, Wo JM: Current treatment of nausea and vomiting associated with gastroparesis: antiemetics, prokinetics, tricyclics. *Gastrointest Endosc Clin N Am* 2009; 19: 57-72.
2. Kim SW, Shin IS, Kim JM, et al.: Mirtazapine for severe gastroparesis unresponsive to conventional prokinetic treatment. *Psychosomatics* 2006; 47: 440-442.
3. Johnstone M, Buddhdev P, Peter M, et al.: Mirtazapine: a solution for postoperative gastroparesis? *BMJ Case Rep* 2009; 2009.
4. Gooden JY, Takahashi PY: Mirtazapine treatment of diabetic gastroparesis as a novel method to reduce tube-feed residual: a case report. *J Med Case Rep* 2013; 7: 38.
5. Hasler WL, Parkman HP, Wilson LA, et al.: Psychological dysfunction is associated with symptom severity but not disease etiology or degree of gastric retention in patients with gastroparesis. *Am J Gastroenterol* 2010; 105: 2357-2367.
6. Kumar A, Attaluri A, Hashmi S, et al.: Visceral hypersensitivity and impaired accommodation in refractory diabetic gastroparesis. *Neurogastroenterol Motil* 2008; 20: 635-642.
7. Yin J, Wang W, Winston JH, et al.: Ameliorating effects of mirtazapine on visceral hypersensitivity in rats with neonatal colon sensitivity. *Neurogastroenterol Motil* 2010; 22: 1022-1028, e267.

(Received, April 1, 2014)

(Accepted, May 8, 2014)