

## Single-incision Laparoscopic Cholecystectomy with an Additional Needle Grasper: A Novel Technique

Osamu Komine<sup>1</sup>, Hideyuki Suzuki<sup>1</sup>, Masanori Watanabe<sup>1</sup>, Satoshi Nomura<sup>1</sup>,  
Satoshi Mizutani<sup>1</sup>, Masanori Yoshino<sup>1</sup>, Naoto Chihara<sup>1</sup>, Keisuke Mishima<sup>1</sup>,  
Rina Oyama<sup>1</sup> and Eiji Uchida<sup>2</sup>

<sup>1</sup>Institute of Gastroenterology, Nippon Medical School Musashi Kosugi Hospital

<sup>2</sup>Department of Surgery, Nippon Medical School

**Background:** Single-incision laparoscopic surgery has gained increasing attention due to its potential to improve the benefits of laparoscopic surgery. However, the technique remains technically challenging for most surgeons. We developed a new technique utilizing a needle grasper held in the surgeon's left hand as an alternative to conventional single-incision laparoscopic cholecystectomy (SILC).

**Patients and Methods:** From August 2011 through May 2013, 29 patients at Nippon Medical School Musashi Kosugi Hospital, with gallbladder stones or polyps underwent single-incision laparoscopic cholecystectomy (SILC) with an additional needle grasper that was held in the surgeon's left hand (SILCAN) and introduced in the right subcostal region without a trocar. We analyzed intraoperative and postoperative outcomes of 29 patients for whom SILCAN was performed and retrospectively compared these outcomes to those of 32 patients who underwent conventional 4-port laparoscopic cholecystectomy (CLC) from January 2011 through May 2013.

**Results:** No differences in patient characteristics or intraoperative/postoperative outcomes were observed between the groups. None of the patients in either group required conversion to an open procedure or additional ports. In the SILCAN group, no patients had complications within the first 4 weeks after surgery, with the exception of 1 patient with severe chronic cholecystitis in whom bile duct stenosis developed due to inadvertent clipping of the common hepatic duct. The frequency of postoperative analgesic use was similar in both groups, although none of the patients in the SILCAN group received analgesics for pain from the small, inconspicuous wound in the right subcostal region.

**Conclusions:** SILCAN is a safe and feasible alternative to SILC which does not compromise the qualities of CLC. It is less technically challenging, and postoperative pain and cosmesis are comparable to those of conventional SILC. (*J Nippon Med Sch* 2015; 82: 43-49)

**Key words:** single incision, laparoscopic surgery, cholecystectomy, needle surgery, reduced port surgery

### Introduction

Single-incision laparoscopic surgery has gained increased attention owing to its potential to improve the benefits of laparoscopic surgery, such as decreased postoperative pain, a more rapid return to normal activity, and an improved cosmetic outcome<sup>1-5</sup>. Since the first report describing single-incision laparoscopic cholecystectomy (SILC) in 1997<sup>6</sup>, many new techniques and types of instrumentation have been reported. Despite these improvements,

SILC remains technically challenging for most surgeons<sup>7-15</sup>. We began performing reduced-port surgery for cholecystectomy in January 2010 and gradually consolidated the ports to a single umbilical incision. However, we recognized a limited range of motion for the forceps and the frequent conflict between the forceps and the laparoscope, which both increase the technical difficulty of SILC and potentially compromise patient safety. Therefore, in August 2011, to address these concerns, we began

---

Correspondence to Osamu Komine, Institute of Gastroenterology, Nippon Medical School Musashi Kosugi Hospital, 1-396 Kosugi-cho, Nakahara-ku, Kawasaki, Kanagawa 211-8533, Japan  
E-mail: ANA62519@nifty.com  
Journal Website (<http://www.nms.ac.jp/jnms/>)

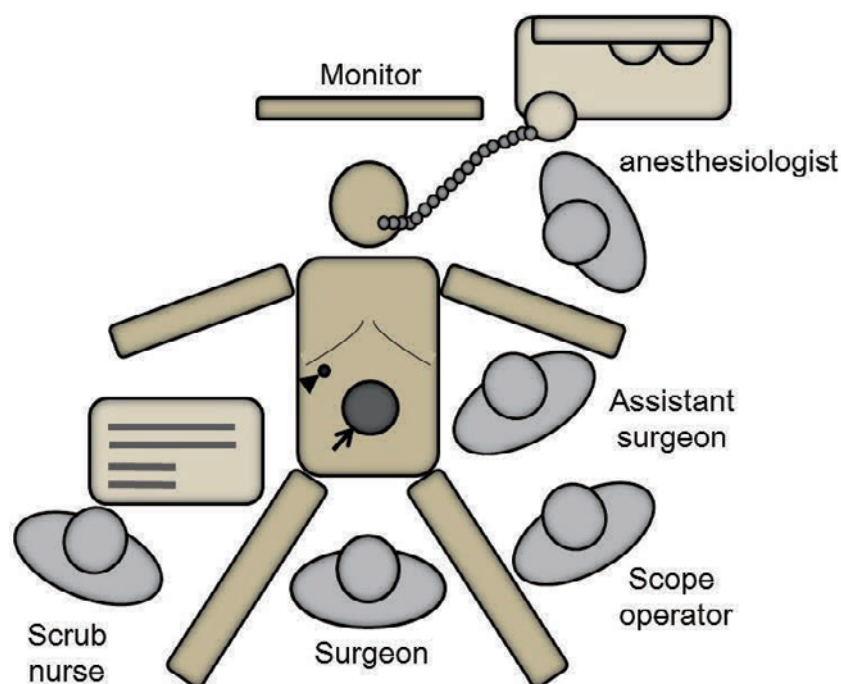


Fig. 1 Position of the patient, surgeons, and video monitor, and sites of the umbilical port (arrow) and the puncture for the clutch clamp (arrow head).

performing SILC with an additional needle grasper held in the surgeon's left hand (SILCAN). To date, we have performed SILCAN for 29 patients with benign gallbladder diseases. In this study, we describe our technique, retrospectively compared patient outcomes between our technique and conventional laparoscopic procedures, and examined the safety and feasibility of SILCAN as an alternative to SILC.

## Materials and Methods

### Patients

We retrospectively analyzed the medical records of 29 patients with benign diseases of the gallbladder who had undergone SILCAN at the Nippon Medical School, Musashi Kosugi Hospital, from August 2011 through May 2013 (SILCAN group). The indications for performing SILCAN at our institution are as follows: 1) benign diseases of the gallbladder without moderate to severe acute inflammation, 2) no previous laparotomy in the upper abdominal region, and 3) elective surgery. All procedures were performed by a single experienced surgeon who had previously performed conventional 4-port laparoscopic cholecystectomy (CLC) more than 200 times. From January 2011 through May 2013, 32 patients who fulfilled the same indications as those who had undergone SILCAN underwent CLC by the same surgeon, based on the same protocols for drainage and intraopera-

tive cholangiography as those used for the SILCAN. These patients served as the historical control group (CLC group), which included 22 patients who had undergone CLC before beginning SILCAN at our institution and 10 patients who chose to undergo CLC rather than SILCAN. Patient characteristics, operative time, cholangiography results, conversion to open surgery, addition of ports, wound pain severity, complications, and length of postoperative hospital stay were compared between the groups. Continuous variables are expressed as means  $\pm$  standard deviation (range). Differences between the groups were analyzed with Student's *t*-test for continuous variables and with the  $\chi^2$  test or Fisher's exact test for categorical variables. Statistical significance was defined as  $P < 0.05$ . This study was approved by the Ethics Committee at our institution (approved No. 160-22-01). Informed consent was obtained from all study participants.

### Surgical Methods

For postoperative analgesia an epidural catheter was inserted in all patients. Following induction of general anesthesia, the patients were placed in a split-leg position. The operating surgeon stood between the patient's legs, and the assistant surgeon and scope operator were located on the patient's left. The monitor was placed above the patient's head (Fig. 1). A 2-cm vertical incision for 3 trocar insertions was made through the center of

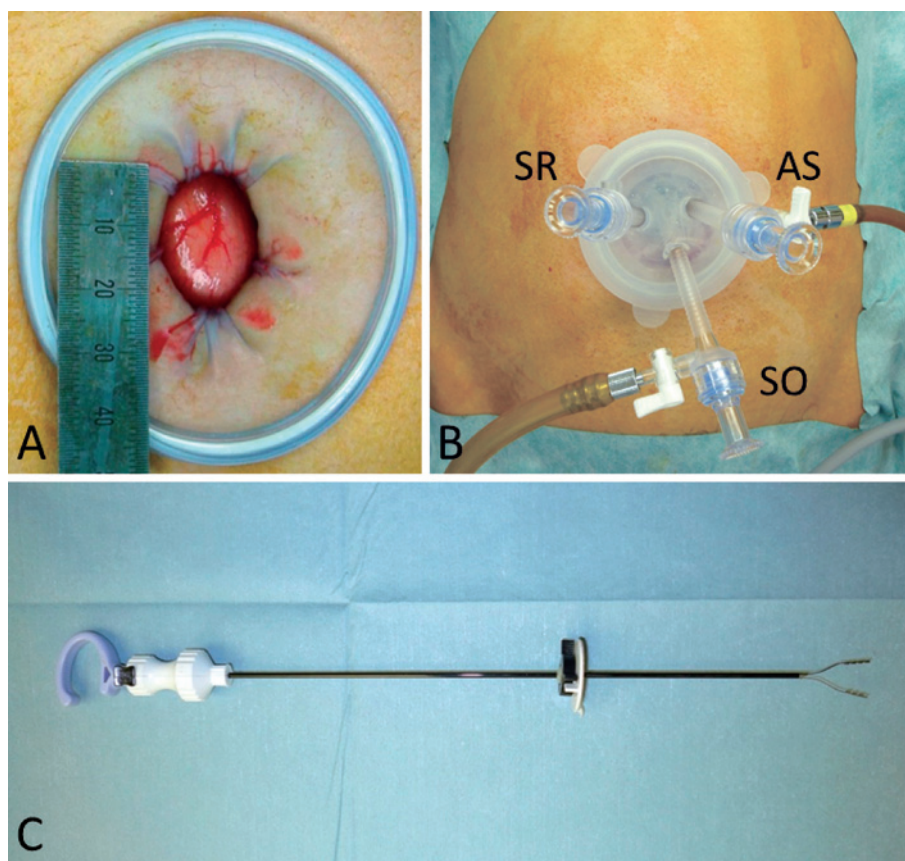


Fig. 2 A: A wound protector placed through the 2-cm umbilical incision.  
 B: Operative photograph of the single port setting with trocars through the wound cover. SR, trocar for a surgeon's right hand; AS, trocar for an assistant surgeon; SO, trocar for a scope operator.  
 C: The clutch clamp, which is a disposable needle instrument with a 2.3-mm outer diameter

the umbilicus, and a puncture was made in the right subcostal region for the additional needle grasper. After the umbilical fascial defect was identified, access to the peritoneal cavity was obtained by gently opening the defect without fasciotomy. A wound protector (Lap Protector Mini; Hakko Medical Co., Ltd., Nagano, Japan) was inserted through the 2-cm umbilical incision under direct visualization (Fig. 2A). A wound cover (E·Z Access, Hakko Medical Co., Ltd.) was mounted on the wound protector, and three 5-mm trocars (E·Z Trocar, Hakko Medical Co., Ltd.), including two 70-mm trocars and one 95-mm trocar, were placed through the wound cover in a reverse equilateral triangle configuration (Fig. 2B). The abdomen was insufflated with CO<sub>2</sub> to 8 mm Hg, and a 5-mm flexible scope (Endoeye Flex LTF-S190-5; Olympus Medical Systems, Corp., Tokyo, Japan) was placed into the abdominal cavity. Patients were positioned in the reverse Trendelenburg, right side-up position. Under laparoscopic vision, a clutch clamp (Mini-Lap Technologies, Inc., Dobbs Ferry, NY, USA), which is a disposable

instrument with a 2.3-mm outer diameter consisting of a small-diameter grasper and a delivery conduit, was introduced directly through the skin and abdominal wall at the mammillary line in the right subcostal region without the use of a trocar (Fig. 2C, 3A). To improve control of the clutch clamp in the surgeon's left hand, the surgeon held the instrument with the ring finger in the device's thumb handle while holding the torque collar between the thumb and index finger (Fig. 3A). The assistant surgeon placed the grasper on the fundus of the gallbladder and elevated it over the liver edge such that the grasper itself moved out of the field of view. The clutch clamp was used to grasp the infundibulum of the gallbladder and retract it laterally and slightly upward to expose Calot's triangle, which was then dissected in the standard fashion using standard straight laparoscopic instruments in the surgeon's right hand via an umbilical trocar. After the creation of the appropriate critical view (Fig. 3B), the cystic duct and cystic artery were clipped with a 5-mm clip applier (EndoClip, Covidien Ltd., Dublin, Ire-

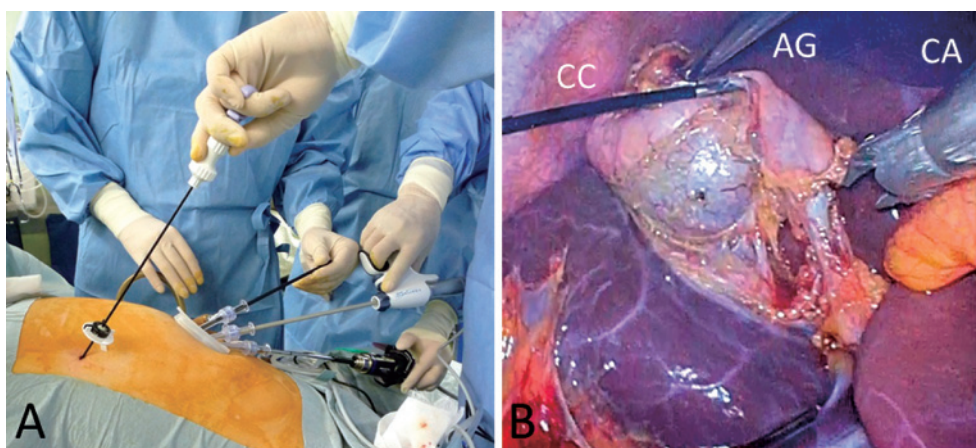


Fig. 3 A: Operative view of single-incision laparoscopic cholecystectomy with an additional needle forceps in the surgeon's left hand.

B: Creation of appropriate critical view. CC, Clutch clamp in a surgeon's left hand; CA, clip applicator in a surgeon's right hand; AG, assistant surgeon's grasper.

land) and divided with endoscopic scissors. Intraoperative cholangiography was not routinely performed when the critical view of safety was ensured and a cystic duct stone or bile tract injury was not suspected. While retracted in various directions with the clutch clamp, the gallbladder was dissected away from the liver bed in a retrograde manner with a hook monopolar electrocautery or laparoscopic coagulating shears and was removed directly via the umbilical port. The desirable triangular configuration of instruments, similar to that for conventional 4-port laparoscopic cholecystectomy, was obtained by using the 5-mm flexible scope and trocar placement, as shown in **Figure 3B**. Drainage was not routinely performed when no major bleeding or bile leakage occurred intraoperatively. After the wound protector was removed, the umbilical fascial defect was repaired with 2-0 Vicryl (Ethicon Inc., Somerville, NJ, USA) suture. The anchor suture was tied at the bottom of the umbilicus to recreate the umbilical depression. Subcuticular sutures with 3-0 Vicryl (Ethicon Inc.) were placed near the edges of the incision. A pledget cotton ball was packed under the dressing to maintain the natural contour of the umbilicus.

For CLC, a 2-cm vertical incision for laparoscope port insertion was made through the center of the umbilicus. A 12-mm operating port was placed in the epigastric region, and 5-mm operating and assistant ports were then placed in the right subcostal region along the midclavicular and anterior axillary lines, respectively. The remaining procedures, including administration of anesthetic agents, operative methods, and postoperative management, were similar to those used in SILCAN.

### Postoperative Management and Follow-up

Continuous epidural infusion of 0.25% levobupivacaine was typically used postoperatively at a rate of 3 mL/h for 33 hours. When epidural anesthesia alone was not sufficient to control the pain, or after the epidural catheter was removed, diclofenac suppositories or intravenous pentazocine was administered. After surgery, all patients were managed according to a clinical protocol with a targeted hospital discharge on postoperative day 6 or 7. All patients underwent follow-up at our outpatient clinic for a minimum of 3 postoperative weeks.

### Results

Patient characteristics and intraoperative/postoperative outcomes were similar between the groups (**Table 1, 2**). Blood loss was minimal and was thus immeasurable in all the patients, with the exception of 1 patient in the CLC group whose operative blood loss was estimated to be 50 g (**Table 2**). None of the patients in either group required conversion to an open procedure or additional ports. The only postoperative complication in the SILCAN group within the first 4 weeks after surgery was bile duct stenosis, which occurred in 1 patient (3.4%) with severe chronic cholecystitis. The common hepatic duct was partially occluded by a clip used to control intraoperative bleeding from the cystic artery in an area of severe inflammation. On postoperative day 3, the clip was removed laparoscopically, and the patient was discharged on the 13th day after SILCAN surgery. All other patients were discharged on postoperative day 6 or 7, according to the clinical protocol. None of the patients in the SILCAN group received analgesics for pain from the

Table 1 Patient characteristics

	SILCAN group (n=29)	CLC group (n=32)	P value
Age (years)	49.8±12.7 (23–76)	50.1±11.9 (31–73)	0.916
Sex (male/female)	12/17	20/12	0.1
Surgical indication (gallbladder stone/others)	27/2	29/3	0.725
gallbladder stone	27 (93.1%)	29 (90.6%)	
with acute cholecystitis	2 ( 6.9%)	3 ( 9.4%)	
without acute cholecystitis	25 (86.2%)	26 (81.3%)	
gallbladder polyp	1 ( 3.4%)	3 ( 9.4%)	
adenomyomatosis of the gallbladder	1 ( 3.4%)	0	
Height (cm)	163.1±8.9 (144–176)	165.7±8.6 (152–181)	0.241
Weight (kg)	67.3±17.3 (46–120)	64.6±11.7 (45–98)	0.471
Body-mass index (kg/m <sup>2</sup> )	25.1±4.8 (16.8–38.7)	25.1±4.8 (18.2–32.7)	0.118
American Society of Anesthesiologists classification (1–2/3)	27/2	32/0	0.222
History of laparotomy			
lower abdominal region	7 (24.1%)	10 (31.3%)	0.536

Data are expressed as means±standard deviation (range) or number of patients (percentages).

SILCAN, single-incision laparoscopic cholecystectomy with an additional needle grasper held in the surgeon's left hand; CLC, conventional 4-port laparoscopic cholecystectomy

Table 2 Operative and postoperative outcomes

	SILCAN group (n=29)	CLC group (n=32)	P value
Operation time (minutes)	91.2±32.1 (36–180)	80.5±16.7 (55–122)	0.115
Blood loss (minimal/others)*	0/29	1/31	>0.999
Cholangiography performed	1 ( 3.4%)	3 ( 9.4%)	0.614
Conversion to open	0	0	>0.999
Addition of ports	0	0	>0.999
Analgesic use for wound pain (%)**	15 (51.7%)	17 (53.1%)	0.913
Frequency of analgesic use for wound pain***	3.1±0.3 (1–5)	3.2±0.3 (1–5)	0.847
Complications	1 ( 3.4%)	3 ( 9.3%)	0.614
gallbladder injury	0	2 ( 6.3%)	0.493
bile duct trouble	1 ( 3.4%)	0	0.475
wound infection	0	1 ( 3.1%)	>0.999
Postoperative length of hospital stay (days)	7.2±1.1 (7–13)	6.9±0.3 (6–7)	0.133
Follow-up period (days)	59.1±5.9 (28–103)	45.4±5.6 (21–100)	0.098

Data are expressed as means±standard deviation (range) or number of patients (percentages).

\*Patients were divided into groups based on whether blood loss was minimal and immeasurable or was measurable.

\*\*All patients who needed analgesics for wound pain received analgesics within 2 days after operation.

\*\*\* Patients who did not use analgesics were excluded.

SILCAN, single-incision laparoscopic cholecystectomy with an additional needle grasper held in the surgeon's left hand; CLC, conventional 4-port laparoscopic cholecystectomy

minimal wound in the right subcostal region. No infections were noted, and no conspicuous umbilical scarring was observed in the SILCAN group (Fig. 4A–C).

### Discussion

With our technique of SILC, which we call SILCAN, an additional needle grasper is introduced in the right subcostal region and held in the surgeon's left hand. This allows a larger range of motion for the left hand than in

conventional SILC. Additionally, with the subcostal needle grasper, we are able to obtain the desirable triangular configuration of instruments similar to that in CLC. In the present study we found that SILCAN did not differ from CLC in terms of operative time, cholangiography results, conversion to open surgery, addition of ports, wound pain severity, complications, or length of postoperative hospital stay. The minimal wound in the right subcostal region was inconspicuous. Therefore, we be-

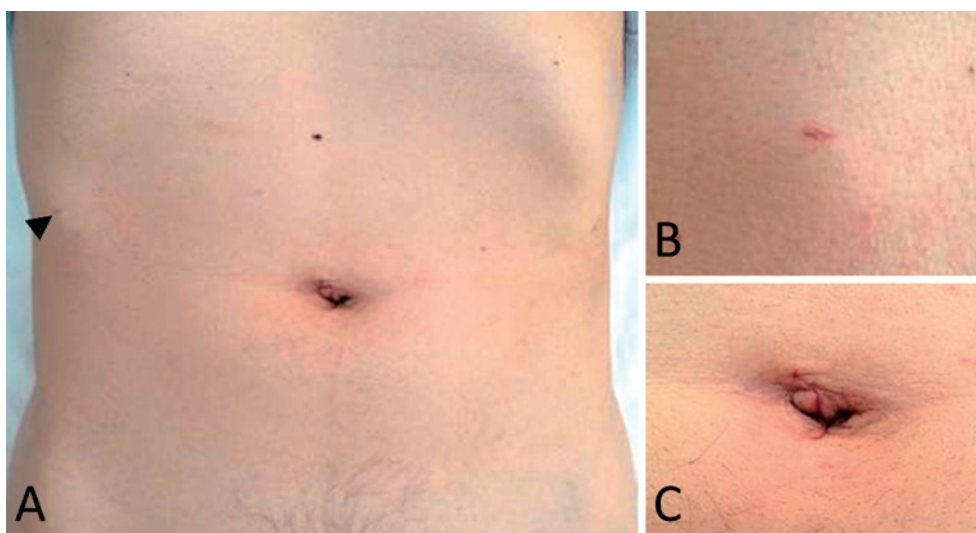


Fig. 4 A: Appearance of scars on postoperative day 14. A puncture by clutch clamp (**arrow head**) is inconspicuous.  
 B: A puncture by clutch clamp  
 C: An umbilical incision

lieve that SILCAN can reduce the technical challenges encountered in SILC while having qualities similar to those of CLC. With SILCAN, there are fewer conflicts between the forceps and the laparoscope in the abdominal cavity and less crowding of the surgeon's hands outside the body. SILCAN is a safe and feasible alternative to SILC which does not increase wound pain or compromise cosmetic benefits.

The protocol in our technique is the same as that in SILC, except for an additional port, which for most surgeons reduces the technical challenges associated with SILC. Although many variations of the SILC procedure have been described<sup>7-15</sup>, our technique is novel in several ways. The novelties in our technique are as follows: 1) use of a directly inserted and easily operable needle grasper with a 2.3-mm outer diameter without any trocars results in excellent cosmesis; 2) use of the needle grasper with the surgeon's left hand, which has been often used by an assistant surgeon to retract the gallbladder cephalad, permits surgeons to avoid conflict of instruments and to obtain the desirable triangular configuration of instruments similar to that in CLC; and 3) placement of 3 ports at the umbilicus and a needle grasper at an optimal position also has effects as those mentioned in 2).

A popular method of SILC utilizes placement of a percutaneous stay suture on the gallbladder to provide cephalad retraction<sup>8-10</sup>. Cosmesis is excellent with this technique, but retraction is limited and inferior to that obtained with instruments. Another method of SILC utilizes an additional port or needle instrument<sup>11-15</sup>. In most

reports of this method, the port or needle instrument has been operated by an assistant surgeon to retract the gallbladder cephalad<sup>11,12</sup>; and in some reports, it has been utilized with the surgeon's right hand at the epigastrium<sup>13,14</sup>. Glupinar et al. have reported performing SILC with a 2-mm atraumatic grasper that the assistant surgeon uses to retract the gallbladder without trocars<sup>11</sup>, although it remains technically challenging for most surgeons because in this technique and in conventional SILC, 2 instruments operated by the surgeon are inserted in a single port at the umbilicus. The techniques developed by Sakran et al. and Lee et al., which utilize an additional needle grasper held in the surgeon's right hand, are also highly effective. However, some surgical energy devices are unavailable due to a 3-mm port, and the cosmetic benefits are inferior due to a 5-mm port. Contrary to expectations, few studies have reported SILC with an additional needle grasper held in the surgeon's left hand<sup>15</sup>. Yasumoto et al. have reported performing SILC with a 2.1-mm-diameter reusable needle grasper held in the surgeon's left hand, as in our technique. However, in their method, Yasumoto et al. used an additional 3-mm trocar for the grasper<sup>12</sup> which increases the risk of scarring.

We believe our technique provides superior cosmetic results owing to the direct insertion of the needle grasper. Introducing an instrument without a trocar may increase the risk of incisional infections due to contamination with infectious bile. In our method, the delivery conduit of the clutch clamp replaces the trocar and, we be-

lieve, decreases the risk of infection. In addition, with the SILCAN technique, due to our trocar placement through the wound cover along with the subcostal placement of the needle grasper, conflicts between the forceps and the laparoscope in the abdominal cavity and crowding of the surgeon's hands outside the body decrease.

In 1 of our patients bile duct stenosis developed due to inadvertent clipping of the bile duct. We did not suspect intraoperative bile duct injury in this patient because intraoperative bleeding from the cystic artery was easily controlled with a clip, after which the critical view of safety was obtained as usual. Therefore, we did not perform intraoperative cholangiography or place additional ports to confirm the absence of bile duct injuries. We do not believe that this complication was directly attributable to our technique. Severe inflammation, as seen in this patient, may cause this complication, even when conventional 4-port cholecystectomy is performed.

The clutch clamp we used does have several drawbacks. It is a disposable instrument that is more expensive and less easy to recycle than other reusable graspers. This instrument may also be more difficult to manipulate than some small-caliber graspers. Finally, the clutch clamp is slightly thicker than other commercially available 2.1-mm diameter reusable graspers.

In conclusion, our SILCAN technique reduces the conflict between the forceps and laparoscope and reduces crowding of the surgeon's hands. These benefits lessen some of the technical challenges associated with SILC, without increased risk of pain or scarring, and maintain qualities similar to those of CLC. We believe that future advances will provide surgeons with improved instrumentation, which will make our method safer, technically less difficult, and more cosmetically beneficial.

### References

1. Ichikawa M, Akira S, Mine K, et al.: Evaluation of laparoendoscopic single-site gynecologic surgery with a multitrocar access system. *J Nippon Med Sch* 2011; 78: 235–240.
2. Omori T, Oyama T, Akamatsu H, Tori M, Ueshima S, Nishida T: Transumbilical single-incision laparoscopic distal gastrectomy for early gastric cancer. *Surg Endosc* 2011; 25: 2400–2404.
3. Bucher P, Pugin F, Morel P: Single-port access laparoscopic radical left colectomy in humans. *Dis Colon Rectum* 2009; 52: 1797–1801.
4. Bazzi WM, Stroup SP, Kopp RP, Cohen SA, Sakamoto K, Derweesh IH: Comparison of laparoendoscopic single-site and multiport laparoscopic radical and partial nephrectomy: a prospective, nonrandomized study. *Urology* 2012; 80: 1039–1045.
5. Yamashita K, Shimizu K: Endoscopic video-assisted breast surgery: procedures and short-term results. *J Nippon Med Sch* 2006; 73: 193–202.
6. Navarra G, Pozza E, Occhionorelli S, Carcoforo P, Donini I: One-wound laparoscopic cholecystectomy. *Br J Surg* 1997; 84: 695.
7. Hong TH, You YK, Lee KH: Transumbilical single-port laparoscopic cholecystectomy: scarless cholecystectomy. *Surg Endosc* 2009; 23: 1393–1397.
8. Brody F, Vaziri K, Kasza J, Edwards C: Single incision laparoscopic cholecystectomy. *J Am Coll Surg* 2010; 210: e9–e13.
9. Rawlings A, Hodgett SE, Matthews BD, Strasberg SM, Quasebarth M, Brunt LM: Single-incision laparoscopic cholecystectomy: initial experience with critical view of safety dissection and routine intraoperative cholangiography. *J Am Coll Surg* 2010; 211: 1–7.
10. Romanelli JR, Roshek TB 3rd, Lynn DC, Earle DB: Single-port laparoscopic cholecystectomy: initial experience. *Surg Endosc* 2010; 24: 1374–1379.
11. Gulpinar K, Ozdemir S, Ozis SE, Aydin T, Korkmaz A: Single Incision Laparoscopic Cholecystectomy by Using a 2 mm Atraumatic Grasper without Trocar. *HPB Surg* 2011; Article ID 761315.
12. Jategaonkar PA, Yadav SP: Prospective Observational Study of Single-Site Multiport Per-umbilical Laparoscopic Endosurgery versus Conventional Multiport Laparoscopic Cholecystectomy: Critical Appraisal of a Unique Umbilical Approach. *Minim Invasive Surg* 2014; Article ID 909321.
13. Sakran N, Goitein D, Raziell A, Hershko D, Szold A: Advantages of minimal incision laparoscopic cholecystectomy. *Isr Med Assoc J* 2014; 16: 363–366.
14. Lee SC, Choi BJ, Kim SJ: Two-port cholecystectomy maintains safety and feasibility in benign gallbladder diseases: A comparative study. *Int J Surg* 2014; 12: 1014–1019.
15. Yasumoto A, Tokumura H, Musya H, Saijou F, Matsu-mura N, Nomura R: Single-incision laparoscopic cholecystectomy with a small caliber forceps via additional 3 mm trocar in the right subcostal region. *J Jpn Soc Endosc Surg* 2012; 17: 535–538.

(Received, July 25, 2014)

(Accepted, January 8, 2015)