

## Pulmonary Nocardiosis due to *Nocardia asiatica* in an Immunocompetent Host

Sakina Okawa<sup>1</sup>, Kazunari Sonobe<sup>1,2</sup>, Yuzo Nakamura<sup>1</sup>,  
Takahito Nei<sup>2,3</sup>, Koichiro Kamio<sup>3</sup> and Akihiko Gemma<sup>3</sup>

<sup>1</sup>Department of Clinical Laboratory, Nippon Medical School

<sup>2</sup>Department of Infection Control and Prevention, Nippon Medical School

<sup>3</sup>Department of Respiratory Medicine, Nippon Medical School

We describe a case of pulmonary nocardiosis due to *Nocardia asiatica* in an immunocompetent 64-year-old female.

Wadowsky-Yee-Okuda- $\alpha$ -ketoglutarate (WYO $\alpha$ ) agar, a selective media for *Legionella* species, was useful for the detection based on the growth-inhibition of normal oral flora and growth-promotion of *Nocardia* species. (J Nippon Med Sch 2015; 82: 159–162)

**Key words:** pulmonary nocardiosis, *Nocardia asiatica*, immunocompetent host, WYO $\alpha$  agar

### Introduction

Nocardiosis generally occurs in immunocompromised hosts, such as patients with hematological malignancy or steroid administration, and their identification is still difficult in general laboratory tests without DNA sequencing. *Nocardia asiatica* was recently identified as a Genus *Nocardia* organism, in 2004.

Herein, we report a case of pulmonary nocardiosis due to *N. asiatica* in an immunocompetent 64-year-old female. Wadowsky-Yee-Okuda- $\alpha$ -ketoglutarate (WYO $\alpha$ ) agar, a selective media for *Legionella* species, was useful for immediately detecting the pathogen.

### Case Report

A 64-year-old female presented to the respiratory medicine section of our hospital with back pain. She had suffered from pulmonary tuberculosis at age 18 and had experienced several episodes of hemoptysis since age 37. She had undergone left lower lobe resection for bleeding and adhesions. Her medical history was otherwise unremarkable with no evidence of immunosuppression. A chest X-ray on admission revealed a nodular dense lesion in the upper left lung field (Fig. 1A), and computed tomography (CT) of the chest 2 months prior to admission had revealed a dense focal lesion in the left S<sup>1+2</sup>c (Fig. 1B). Biochemical data indicated neither hepatic nor renal system abnormalities. A sputum sample yielded Gram-

positive, filamentous rods on microscopic observation, and *Nocardia*-like bacteria grew in culture. Bronchoalveolar lavage confirmed these findings, and pulmonary nocardiosis was finally diagnosed. She was treated with trimethoprim-sulfamethoxazole (TMP/SMX; TMP 320 mg/day, SMX 1,600 mg/day) for 9 months, after which the pulmonary nodule was diminished on CT scans.

Smear studies of sputum but not bronchoalveolar lavage showed the presence of gram-positive filamentous bacilli in the background of the necrotic component without bacterial phagocytosis (Fig. 2A). Kinyoun staining also showed filamentous bacilli with mild acidity (Fig. 2B). Samples were cultured not only on 5% sheep blood agar (Eiken Chemical, Tokyo, Japan) but also on Wadowsky-Yee-Okuda- $\alpha$ -ketoglutarate (WYO $\alpha$ ) agar (Eiken Chemical), which is used for selective culture of *Legionella* species. We performed 4-day aerobic cultures at 35°C using 5% sheep blood agar (Fig. 2C) and WYO $\alpha$  agar (Fig. 2D) with bronchial lavage samples and obtained a white wrinkled colony swelling like soil smell on both blood agar and WYO $\alpha$  agar media. Interestingly, we were able to isolate only a single *Nocardia* colony in WYO $\alpha$  agar media, despite the fact that *Nocardia* colony was detected with normal oral flora in blood agar media. We accurately identified the strain with 16s ribosomal RNA genotyping, as previously described, and a similarity search was conducted using the BLAST program

Correspondence to Takahito Nei, MD, Department of Infection Control and Prevention, Nippon Medical School, 1-1-5 Sendagi, Bunkyo-ku, Tokyo 113-8603, Japan  
E-mail: takahitonei@gmail.com  
Journal Website (<http://www.nms.ac.jp/jnms/>)

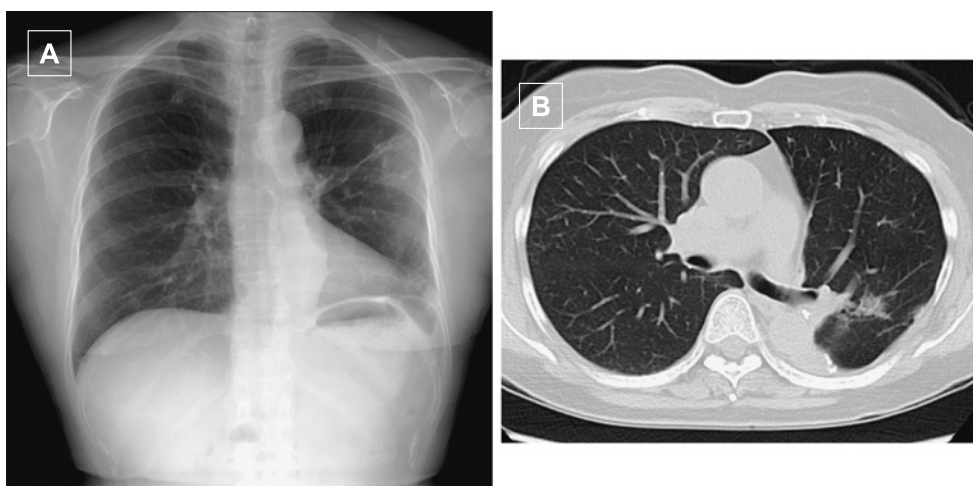


Fig. 1 (A) Chest X-ray on admission revealed a dense focal lesion in the upper left lung field. (B) Computed tomography of the chest 2 months prior to admission revealed a dense focal lesion in the left S<sup>1+2c</sup>. Internally, lesion appeared heterogeneous and the border was irregular.

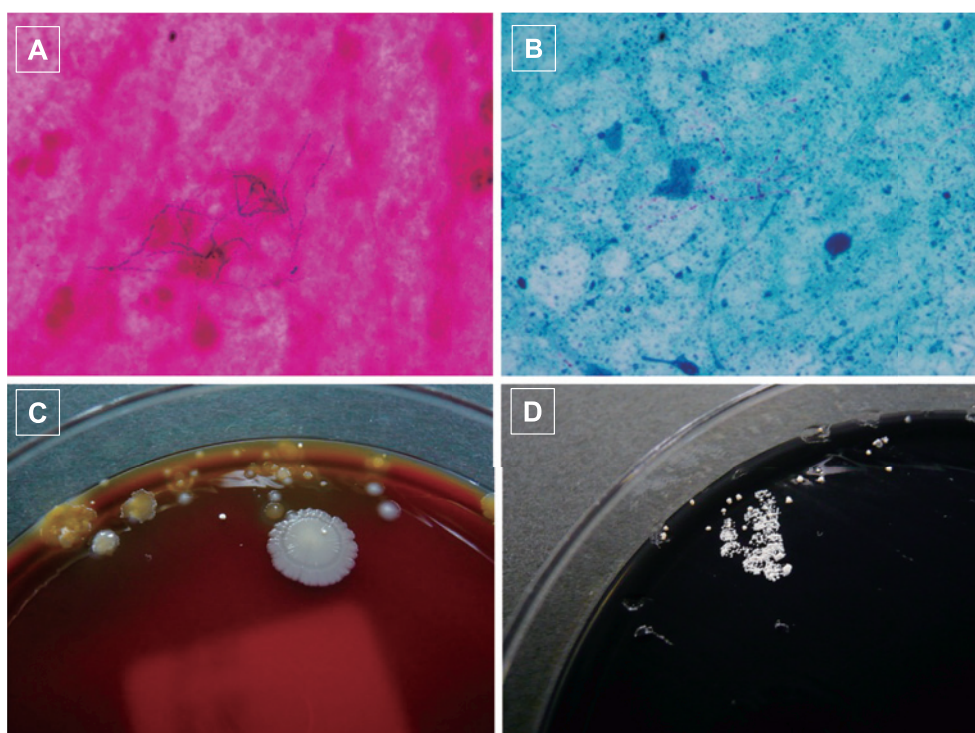


Fig. 2 Photomicroscopy of the Gram stained (A) sputum revealed filamentous bacilli. Kinyoun staining (B) also showed filamentous bacilli with mild acidity. A white wrinkled colony with the smell of soil was obtained with from both 5%-sheep blood supplemented blood agar (C) and WYO $\alpha$  agar medium (D). A *Nocardia* colony with growth of normal oral flora was isolated with the former, while a solitary *Nocardia* colony was obtained using WYO $\alpha$  medium.

(DNA Data Bank of Japan, Shizuoka, Japan). The results (1,432 bp; GenBank accession no. AB820725) showed 99.4% (1,387/1,395) similarity to the type strain (GenBank accession no. AB092566) of *Nocardia asiatica*, which was registered as a new species in 2004<sup>1</sup>. Furthermore, the

similarity between our strain and strain IFM 11100 (GenBank accession no. AB630967) was 99.9% (1,431/1,432).

Determination of minimum inhibitory concentrations (MICs) by microbroth dilution antimicrobial susceptibility testing (Walkaway™ Plus Systems, Siemens, Munich,

Germany) was performed according to the sample preparation and reading conditions recommended by the supplier. In short, isolated colonies were suspended in 3 mL of Inoculum Water (Siemens) until a density corresponding to the McFarland standard 0.5 ( $\approx 1.5 \times 10^8$  cfu/mL) was obtained. We then added 100  $\mu$ L to Mueller-Hinton broth supplemented with 3% lysed horse blood (Siemens), and determined MICs using the MICroFast™ series, Pos Combo Panel 3.1J (SIEMENS), Neg comb Panel 3.12J (SIEMENS), and Neg comb Panel 6.11J (SIEMENS). Susceptibilities (MIC  $\mu$ g/mL) to several antibiotics were: amoxicillin-clavulanic acid 16/8, ceftriaxone 1, cefotaxime  $\leq 8$ , cefepime  $\leq 4$ , imipenem  $\leq 1$ , tobramycin  $\leq 1$ , amikacin  $\leq 4$ , clarithromycin  $> 32$ , minocycline  $\leq 2$ , ciprofloxacin  $> 2$ , trimethoprim/sulfamethoxazole  $\leq 2/38$ , and linezolid  $\leq 2$ .

### Discussion

Genus *Nocardia* organisms are aerobic gram-positive rods and partially show acid-fast beaded filamentous branching. These bacteria are found worldwide in soil rich in organic matter. *Nocardia* species are often found as oral microflora in healthy gingiva and periodontal pockets. Generally, nocardiosis infections have a wide range of manifestations, from cutaneous infections caused by traumatic inoculation with the organism of a normal host to severe pulmonary or central nervous system (CNS) disease<sup>2</sup>, and are included in the differential diagnoses of infectious diseases in immunocompromised hosts. Pulmonary nocardiosis progresses to systemic infections, including brain abscesses or blood stream sepsis, and is associated with a high mortality rate. Spontaneous resolution is rare and these infections often require long-term therapy. Therefore, immediate detection is important for adequate therapy. However, identification and assessment of susceptibility are required to determine the optimal treatment based on differentiation of antimicrobial susceptibility patterns by species.

*Nocardia asiatica* was newly isolated by Kageyama *et al.* in 2004 from three *N. asteroides*-like strains obtained in Japan and Thailand<sup>1</sup>. Since 2004, *N. asiatica* has been isolated as a causative pathogen in Italy<sup>3</sup> and Belgium<sup>4</sup>. Though we attempt to identify this organism according to its biochemical characteristics, including organic resolution and usage, as well as the productive pattern of organic acid from glucose, the identification of *Nocardia* species is often difficult in general laboratory tests unless the DNA sequence can be determined. Therefore, in our present case, we employed an isolation method based on 16S rRNA sequencing, as described in a previous report<sup>5</sup>.

However, interestingly, the identification results did not correspond to the antimicrobial susceptibilities of *N. asiatica*. In this regard, we consider it to be important not only to identify isolates but also to determine antimicrobial susceptibilities, because there might be unusual strains with a distinct susceptibility pattern.

WYO $\alpha$  agar medium was established by adding amphotericin B to GVP (Glycine-Vancomycin-Polymyxin) medium<sup>6</sup>, which was developed as a selective medium for genus *Legionella* by Wadowsky and Lee in 1981<sup>7</sup>. Compared with BCYE (buffered charcoal yeast extract) agar medium as the common selective medium for *Legionella*<sup>8</sup>, WYO $\alpha$  agar inhibited the growth of fungi and normal oral flora and was thus effective for selective isolation. Therefore, we often use WYO $\alpha$  agar medium for isolation of *Legionella* from sputum that contains normal oral flora. On the other hand, we often use agar medium containing 5% sheep blood for isolation of genus *Nocardia*. However, the growth of fungi and normal flora is often problematic. Though it is often difficult to selectively isolate genus *Nocardia* with agar medium containing 5% sheep blood, WYO $\alpha$  agar medium has recently been used for the isolation of genus *Nocardia* from respiratory samples<sup>9</sup>. *Nocardia asteroides* is easily isolated with amphotericin B supplemented BCYE agar medium, so we used this medium for isolating *Nocardia* species from obtained samples. Interestingly, WYO $\alpha$  agar culture effectively produces preferential segregation of *Nocardia* species as compared with 5%-sheep blood agar culture.

Our present patient had pulmonary nocardiosis due to *N. asiatica*, despite being an immunocompetent host. Few cases of pulmonary nocardiosis due to *N. asiatica* have been reported in the literature<sup>10,11</sup>, so we consider this case to be rare. It is likely that nocardiosis predominantly occurs in immunocompromised patients. Furthermore, *N. asiatica* is a rare *Nocardia* species. A few reports of *N. asiatica* infection include respiratory infections such as pneumonia, intrabronchial infection and mediastinal infection, as well as cutaneous infections, and olecranon bursitis. Though bronchial endoscopic evaluation showed neither inflammatory changes nor bronchial diverticula, we suspected our patient had suffered from hemoptysis. Therefore, a structural abnormality might have been the source of infection.

In conclusion, we have described pulmonary nocardiosis due to *N. asiatica* in an immunocompetent host. This organism was newly identified in 2004. We recommend that WYO $\alpha$  agar medium be used for detecting *Nocardia* species in respiratory samples.

**Acknowledgements:** We thank Dr. Ryoichi Saito (Tokyo Medical and Dental University, Tokyo, Japan) for identifying the strain with 16s ribosomal RNA genotyping, Dr. Bierta Barfod for editing the manuscript, and Toshie Sekine for secretarial assistance. We also thank Dr. Yoshinobu Saito (Nippon Medical School, Tokyo, Japan) and Dr. Kazue Fujita (Nippon Medical School, Tokyo, Japan) for their help with the present report.

**Conflict of Interest:** None of the authors have any financial relationships with a commercial entity with an interest in the subject of this study.

### References

1. Kageyama A, Poonwan N, Yazawa K, Mikami Y, Nishimura K: *Nocardia asiatica* sp. nov., isolated from patients with nocardiosis in Japan and clinical specimens from Thailand. *Int J Syst Evol Microbiol* 2004; 54: 125–130.
2. Brown-Elliott BA, Brown JM, Conville PS, Wallace RJ: Clinical and laboratory features of the *Nocardia* spp. based on current molecular taxonomy. *Clin Microbiol Rev* 2006; 19: 259–282.
3. Iona E, Giannoni F, Brunori L, de Gennaro M, Mattei R, Fattorini L: Isolation of *Nocardia asiatica* from cutaneous ulcers of a human immunodeficiency virus-infected patient in Italy. *J Clin Microbiol* 2007; 45: 2088–2089.
4. Verfaillie L, De Regt J, De Bel A, Vincken W: *Nocardia asiatica* visiting Belgium: nocardiosis in a immunocompetent patient. *Acta Clin Belg* 2010; 65: 425–427.
5. Nei T, Hyodo H, Sonobe K, Dan K, Saito R: First report of infectious pericarditis due to *Bordetella holmesii* in an adult patient with malignant lymphoma. *J Clin Microbiol* 2012; 50: 1815–1817.
6. Okuda K, Ikedo M, Yabuuchi E: [Wadowsky-Yee-Okuda (WYO) medium: a new selective medium for the isolation of Legionellae strains from environmental water specimens]. *Kansenshogaku Zasshi* 1984; 58: 1073–1082.
7. Wadowsky RM, Yee RB: Glycine-containing selective medium for isolation of Legionellaceae from environmental specimens. *Appl Environ Microbiol* 1981; 42: 768–772.
8. Pasculle AW, Feeley JC, Gibson RJ, Cordes LG, Myerowitz RL, Patton CM, Gorman GW, Carmack CL, Ezzell JW, Dowling JN: Pittsburgh pneumonia agent: direct isolation from human lung tissue. *J Infect Dis* 1980; 141: 727–732.
9. Vickers RM, Rihs JD, Yu VL: Clinical demonstration of isolation of *Nocardia asteroides* on buffered charcoal-yeast extract media. *J Clin Microbiol* 1992; 30: 227–228.
10. Saraya T, Ohkuma K, Kikuchi K, Tamura M, Honda K, Yamada A, Araki K, Ishii H, Makino H, Takei H, Karita S, Fujiwara M, Takizawa H, Goto H: Cytomegalovirus pneumonia in a patient with interstitial pneumonia and *Nocardia asiatica* presenting as cavitary lung lesions. *Intern Med* 2013; 52: 593–597.
11. Matsumoto T, Shimizu T, Aoshima Y, Oda H, Kikuchi K, Katsura H, Fujiwara T, Onuki T: Endobronchial hamartoma with obstructive pneumonia due to *Nocardia asiatica*. *Gen Thorac Cardiovasc Surg* 2011; 59: 141–144.

(Received, August 22, 2014)

(Accepted, January 5, 2015)