

Prenatal Detection of Peters' Plus Syndrome in a Patient with No Known Family History

Yoshio Shima¹ and Makoto Migita²

¹Department of Neonatal Medicine, Nippon Medical School Musashi Kosugi Hospital, Kanagawa, Japan

²Department of Pediatrics, Nippon Medical School Musashi Kosugi Hospital, Kanagawa, Japan

Peters' plus syndrome is a rare autosomal recessive condition characterized by a combination of typical ocular defects and other systemic abnormalities. We present a case of this uncommon syndrome that we diagnosed during a fetal ultrasonographical examination. Because the patient exhibited microcephaly and anterior staphyloma of the right eye and because impending rupture was feared, we performed ophthalmectomy during the neonatal period. Fetal ophthalmological anomalies are often detected during ultrasonographic examination targeting other systemic abnormalities, with positive family histories providing important diagnostic clues. This case is, to our knowledge, the first to be reported of prenatally diagnosed Peters' plus syndrome in a patient with no known family history in whom total blindness was prevented with an early referral to specialists. (*J Nippon Med Sch* 2016; 83: 130-132)

Key words: Peters' plus syndrome, prenatal diagnosis

Introduction

Congenital anomalies of the eye may appear in isolation or as part of a systemic syndrome, with cases having a genetic inheritance pattern particularly seen in the latter situation. Peters anomaly is a rare congenital anomaly of the anterior segment of the eye that is characterized by central corneal opacity (leukoma), thinning of the posterior aspect of the cornea, and iridocorneal adhesions attached to the edges of a leukoma with varying levels of severity¹. Anterior staphyloma, which is ectasia of the cornea caused by remnants of the anteriorly displaced iris that covers the posterior surface, is the most severe expression of this anomaly. Cataracts and glaucoma at birth are also common due to structural vulnerability and high ocular pressures.

Peters anomaly can also occur as part of a multiple malformation syndrome, which is referred to as the Peters' plus syndrome. In these types of cases, there is a typical ocular anomaly, distinctive craniofacial features, disproportionate stature, along with a variable degree of growth and developmental delay². The diagnosis of this syndrome has been made on clinical grounds. The true prevalence is not known, but fewer than 50 cases have

been reported in the literature³. Peters' plus syndrome was also described to follow an autosomal recessive pattern of inheritance³, and the gene mutation responsible for these changes was subsequently identified⁴. Although the clinical features of Peters' plus syndrome have been reviewed^{3,5} only a few fetal cases have been reported. All these cases have shown that an abnormal obstetrical history or a family history or both can provide important diagnostic clues⁶⁻⁸.

Here, we report a fetal case of Peters' plus syndrome that was diagnosed with fetal ultrasonography despite the absence of any family history.

Case Report

A 38-year-old Japanese woman, gravida 0, para 0, at 36 weeks' gestation came to our hospital for a routine obstetric evaluation. This visit to our hospital was her first, but no obstetric data from her former clinic was available because she did not have a referral letter. The ultrasonographic examination performed at our hospital revealed no abnormal findings of fetal structure, biometrics, or amniotic fluid volume until a significantly small fetal biparietal diameter of 2.5 standard deviations (SDs)

Correspondence to Yoshio Shima, MD, Department of Neonatal Medicine, Nippon Medical School Musashi Kosugi Hospital, 1-396 Kosugi-cho, Nakahara-ku, Kawasaki, Kanagawa 211-8533, Japan

E-mail: shima-p@nms.ac.jp

Journal Website (<http://www.nms.ac.jp/jnms/>)

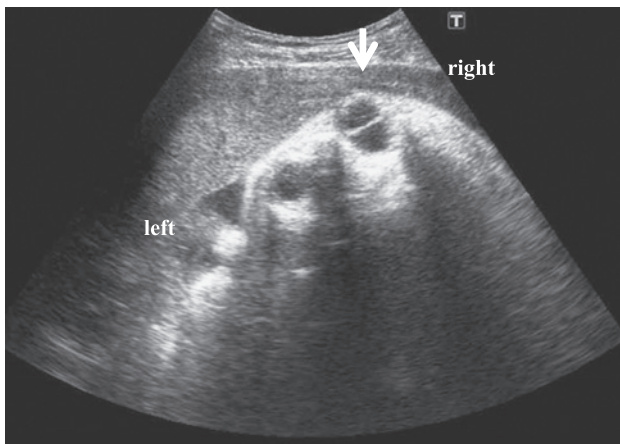


Fig. 1 Fetal ultrasonographic findings at 36 weeks' gestation. A disproportionate size of the eye globes (left microphthalmia) and hyperechogenicity in the anterior part of the enlarged right eye (arrow) were noted.

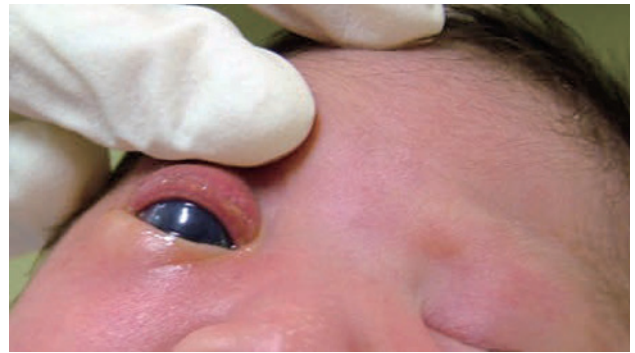

Fig. 2 Clouding in the right eye was observed, and the eye was protruding from the orbit.

less than the mean for the gestational age without lateral molding was detected. The pregnancy had been uneventful, and no significant family history was recorded. Although an elaborate ultrasonographic examination found no additional anomalies, it did reveal peculiar features of the fetal eyes. These features were disproportionate size between both sides of the eye globes, left microphthalmia with an axial ocular diameter of 9 mm (normal average for gestational age is 15 mm), and a relatively large right eye with a hyperechogenic anterior chamber (Fig. 1).

A female neonate (2,574 g) was vaginally delivered at 37 weeks' gestation with Apgar scores of 9/9 at 1 and 5 minutes, respectively. The initial physical examination revealed bilateral corneal clouding and an enlarged right eye, which was protruding from the orbit (Fig. 2). Except for a head circumference of 28.0 cm (-3.3 SD), the findings of all additional examinations, including radiographic and ultrasonographic were otherwise normal. Because impending rupture of the right eye was feared and because panophthalmitis of the left eye occurred after sympathetic ophthalmia, right ophthalmectomy was performed when the neonate was 17 days old. The enucleated right eye showed central corneal opacity, lack of apparent anterior chamber structure, and iridocorneal adhesion, all of which were consistent with Peters' anomaly. Peters' plus syndrome was diagnosed because of the presence of the typical triad of ocular anomaly, peculiar facial characteristic, and microcephaly at birth.

Following hospital discharge, the neonate had delayed developmental milestones and growth deficiency, shown

by a height and weight of 3 SD less than the means for her age. However, she achieved relatively good motor and cognitive development. She learned to speak and acquired simple skills without trouble in carrying out her daily activity. Furthermore, because the corneal opacity was less severe in the residual small left eye, her visual identification ability was preserved despite extreme short-sightedness. Magnetic resonance imaging of the brain performed when the patient was 3 years old showed no abnormalities of structure or maturation. The patient is now attending a special school for the blind. However, her family decided against pursuing any further genetic testing for the disease.

Discussion

Peters' plus syndrome is a rare condition characterized by a combination of a developmental anomaly of the eye and extraocular defects that result in a variety of neurodevelopmental delays. Despite its rarity, this syndrome can be easily recognized clinically because of its characteristic ophthalmologic features and the presence of the extraocular defects. However, prenatal diagnosis based solely on an ultrasonographic examination would be more difficult because both the ocular and extraocular findings are variable and nonspecific. Indeed, in previous case reports of fetal Peters' plus syndrome, diagnoses were only confirmed at autopsy with the help of the family or an abnormal past obstetrical history or both⁶⁻⁸.

In the present patient, routine obstetric scanning during a hospital visit detected a small biparietal diameter without lateral molding by head compression, which led to further ultrasonographic examinations that ultimately obtained the peculiar fetal ocular findings. The essential feature of Peters anomaly is dysgenesis of the anterior chamber of the eye. Thus, the striking ultrasonographic

features of the fetal right eye were considered to reflect an anterior staphyloma, the presence of which we were eventually able to confirm after birth. In addition to having microcephaly, the patient was strongly suspected before birth of having Peters' plus syndrome, despite the absence of any family history. We carefully explained the ultrasonographic findings to the family and encouraged them that their child's condition was not life-threatening. Defects of the anterior chamber of the eye may be found in other syndromes, but the literature review emphasized that between Peters' plus syndrome and other diseases characterized by anterior segment cleavage disturbances of the eye the boundary is not clearly defined³. Peters' plus syndrome has been reported with a variety of associated congenital anomalies, which explain its wide spectrum of phenotypes. However, the key feature of this syndrome is a combination of typical ocular anomaly and deficiencies of growth and developmental, which was observed in the present case.

Although current guidelines for imaging the face of a fetus do not include examination of the eye, recent technological advancements of obstetrical ultrasonography have allowed orbital and ocular defects to be detected before birth^{9,10}. Furthermore, prenatal treatment does not yet exist, but prenatal detection of an ophthalmological abnormality enables patients to be referred to specialists who can make early decisions about postnatal management. Although the prenatal diagnosis of typical Peters anomaly did not have a positive effect on the final visual acuity in the present patient, surgical treatment during the neonatal period helped prevent total blindness.

Fetal ophthalmological anomalies are often discovered during ultrasonographic examinations to screen for systemic abnormalities in patients with obstetrical risk factors or a family history or both¹⁰. To our knowledge, the present report is the first of a case of prenatal of Peters' plus syndrome diagnosed solely on the basis of ultrasonographic findings. Thus, when such cases occur, a multidisciplinary team of specialists, including genetic

counselors, should be called upon to assist in the prenatal and postnatal management.

Conflict of Interest: The authors have no conflicts of interest to disclose.

References

1. Harissi-Dagher M, Colby K: Anterior segment dysgenesis: Peters anomaly and sclerocornea. *Int Ophthalmol Clin* 2008; 48: 35-42.
2. Mayer UM: Peters' anomaly and combination with other malformations (series of 16 patients). *Ophthalmic Paediatr Genet* 1992; 13: 131-135.
3. Maillette de Buy Wenniger-Prick LJ, Hennekam RC: The Peters' plus syndrome: a review. *Ann Genet* 2002; 45: 97-103.
4. Lesnik Oberstein SA, Kriek M, White SJ, Kalf ME, Szuhai K, den Dunnen JT, Breuning MH, Hennekam RC: Peters plus syndrome is caused by mutations in B3GALTL, a putative glycosyltransferase. *Am J Hum Genet* 2006; 79: 562-566.
5. Ozeki H, Shirai S, Nozaki M, Sakurai E, Mizuno S, Ashikari M, Matsunaga N, Ogura Y: Ocular and systemic features of Peters' anomaly. *Graefe's Arch Clin Exp Ophthalmol* 2000; 238: 833-839.
6. Boog G, Le Vaillant C, Joubert M: Prenatal sonographic findings in Peters-plus syndrome. *Ultrasound Obstet Gynecol* 2005; 25: 602-606.
7. Gupta N, Kaul A, Kabra M: Prenatal diagnosis of fetal peters' plus syndrome: a case report. *Case Rep Genet* 2013; 364529.
8. Schoner K, Kohlhase J, Muller AM, Schramm T, Plassmann M, Schmitz R, Neesen J, Wieacker P, Rehder H: Hydrocephalus, agenesis of the corpus callosum, and cleft lip/palate represent frequent associations in fetuses with Peters' plus syndrome and B3GALTL mutations. Fetal PPS phenotypes, expanded by Dandy Walker cyst and encephalocele. *Prenat Diagn* 2013; 33: 75-80.
9. Leung E, Diaz-Barbosa M, Alabiad C, Hodapp E, Tse D, Murray TG, Castaner JC, Martin D, Borrocal AM: Prenatal ultrasonographic detection of ophthalmic diseases. *J Pediatr Ophthalmol Strabismus* 2012; 49: e26-e29.
10. Mashiach R, Vardimon D, Kaplan B, Shalev J, Meizner I: Early sonographic detection of recurrent fetal eye anomalies. *Ultrasound Obstet Gynecol* 2004; 24: 640-643.

(Received, July 1, 2015)

(Accepted, February 3, 2016)