

Objective Spectrometric Measurement of Keloid Color in the East Asian Population: Pitfalls of Subjective Color Measurements

Masayo Aoki, Satoshi Akaishi, Junichi Nakao,
Teruyuki Dohi, Hiko Hyakusoku and Rei Ogawa

Department of Plastic, Reconstructive and Aesthetic Surgery, Nippon Medical School, Tokyo, Japan

Background: Keloids are characterized by the formation of excessive scar tissue that extends beyond the area of the initial wound. Keloid redness is due to angiogenesis and chronic inflammation and is an important indicator of the severity of the lesion and the effectiveness of treatment.

Methods: The color of 33 untreated keloids from 30 patients was measured with a narrow-band reflectance colorimeter. The erythema and melanin levels in the keloids (Ek and Mk, respectively) were recorded with control data obtained from the flexor aspect of the forearm (Ec and Mc, respectively). The keloid color was also evaluated subjectively.

Results: The Ek or Mk values did not vary significantly according to symptom intensity, scar region, patient age, and patient sex. Younger patients (<40 years) and female patients had significantly higher Ek/Ec ratios than did older patients and male patients, respectively. Subjective keloid redness evaluations distinguished keloids with high Ek/Ec ratios from keloids with low Ek/Ec ratios ($P<0.0001$) but could not distinguish keloids with high Ek from keloids with low Ek.

Conclusions: Subjective evaluations of keloids in Japanese subjects reflected Ek/Ec ratios, which were strongly affected by variation in background skin color. The subjective assessment of the color of keloids or other skin disorders should be performed with caution in Asian populations.

(J Nippon Med Sch 2016; 83: 142–149)

Key words: keloid, scar assessment, skin color assessment, spectrometer, erythema

Introduction

Keloids are a result of abnormal wound healing that results in excessive scar tissue formation that extends beyond the area of the initial wound and does not regress spontaneously¹. These scars are generally difficult to treat, although there are many therapeutic options, including surgery, corticosteroid injections, cryotherapy, radiation, and antitumor/immunosuppressive agents². Determining the efficacy of these therapies is sometimes difficult. One possibility is to assess these scars' color, which reflects hemoglobin and melanin concentrations. The redness of keloids and hypertrophic scars (HSs) appears to relate to angiogenesis and chronic inflammation, which suggests that the color of keloids is an important indicator of the severity of the lesion and the effectiveness of treatment.

Scars are rated with a variety of scales. The most well-known and widely used scale is the Vancouver Burn Scar Assessment Scale, which was established in 1995 and is usually referred to as the Vancouver Scar Scale³. This scale also assesses color and thus can be used to assess the severity of keloids/HSs or the efficacy of a therapy on such scars. Other scales have also been used for this purpose, namely, the Manchester Scar Scale⁴, a visual analog scale scar scoring⁵, and the Japan Scar Workshop Scar Scale⁶. However, these scales require that color is judged with the naked eye; thus, the measurement is subjective and may vary depending on the evaluator.

The color of scars and other skin disorders has been measured for more than 50 years with spectrophotometry^{7,8}. The ability of spectrophotometry to measure the color of different skin lesions (both pigmented and vas-

Correspondence to Masayo Aoki, Department of Plastic, Reconstructive and Aesthetic Surgery, Nippon Medical School, 1-1-5 Sendagi, Bunkyo-ku, Tokyo 113-8602, Japan
E-mail: masayok@nms.ac.jp
Journal Website (<http://www.nms.ac.jp/jnms/>)

cular) is good^{9,10}. The measurement of scar color with either a tri-stimulus colorimeter (Minolta Chroma Meter[®]) or a narrow-band reflectance meter (DermaSpectrometer[®]); has yielded fairly good results¹¹. However, whether these methods can measure HS/keloid color in an objective and quantitative fashion has not been determined.

On the basis of our clinical experience, we have postulated that keloid erythema levels are higher in female patients than in male patients and higher in younger patients than in older patients. We have also hypothesized that keloid erythema and melanin levels correlate with symptom intensity and vary depending on the body region of the keloid. In the present study, keloid color was measured with a color measurement device. The relationships of these color measurements with the scar region, the intensity of the symptoms, and patient age, and sex were assessed.

Materials and Methods

Ethical Considerations

The research complied with the Declaration of Helsinki and was approved by the Ethical Committee of Nippon Medical School. Informed consent was obtained from all patients.

Instruments

The DermaSpectrometer[®] (Cortex Technology, Hadsund, Denmark) narrow-band reflectance meter was used to measure the color of keloids. The light-emitting diodes of this instrument emit light at 2 defined wavelengths: 568 nm (green) and 655 nm (red). A photodetector measures the light reflected by the skin. Because hemoglobin strongly absorbs green light wavelengths (which is why blood is red), the DermaSpectrometer estimates erythema levels by measuring how much green light is absorbed. In contrast, melanin readily absorbs both red light and green light. The DermaSpectrometer can measure melanin levels by measuring the reflectance of red light. The area of skin that is measured is 6 mm in diameter (surface, 0.28 cm²). The probe is applied to the skin surface (3.46 cm²) with no more force than the weight of the instrument (640 g). Thus, the skin is placed under a pressure of 158 g/cm². The instrument is calibrated with a black and white calibration plate¹².

Patients

The color of 33 untreated keloids from 30 patients (12 men and 18 women) was measured with the spectrophotometer. All patients first presented at the outpatient department of our hospital in 2009 or 2010.

Assessment of Symptom Intensity

Before keloid color was measured, the patients were asked to subjectively evaluate the intensity of their keloid symptoms by scoring the overall pain, itch, and/or subjective redness of their keloid with a 4-point system: 1, slight; 2, mild; 3, strong; and 4, very strong.

Measurement of Keloid Color with Spectrophotometry

The erythema and melanin levels in the keloids (designated as Ek and Mk, respectively) were recorded with control data taken from the flexor aspect of the forearm (Ec and Mc, respectively). Each measurement was performed 3 times, and the mean was calculated. The Ek/Ec and Mk/Mc ratios were then calculated.

Subjective Evaluations of Keloid Redness

The redness of 8 of the keloids was evaluated subjectively by 6 plastic surgeons with a 10-point system. To ensure that this evaluation was not affected by the age or sex of the patient or by the keloid region, the plastic surgeons were given digital photos of the keloid lesions. The redness was evaluated by comparing the keloid to the color of the surrounding skin.

Statistics

The relationships of Ek, Mk, Ek/Ec, and Mk/Mc to the scar region, symptom intensity, patient age, and patient sex were assessed with the Tukey-Kramer method or Student's *t*-test. Two-factor repeated measures ANOVA was used to assess the accuracy of the subjective evaluations of keloid redness relative to the DermaSpectrometer measurements. The Statcel2 software program (OMS Ltd., Saitama, Japan) was used for statistical analyses. Differences were considered to be statistically significant if *P* was <0.05.

Results

Patient Characteristics

Of the 30 patients, 12 were men (40%) and 18 were women (60%; **Table 1**). The ages of the patients ranged from 18 to 64 years, and the mean age was 33.09 ± 12.79 years. In total, 23 patients (76.7%) were younger than 40 years, and 7 (23.3%) were 40 years and older. All patients were Japanese. Of the 33 keloids, 14 (42.4%) were on the anterior chest, 5 (15.2%) were on an ear lobe, 4 (12.1%) were on a shoulder, and 3 (9.1%) were on the lower abdomen. The remaining 7 keloids were on the mandible, lateral chest (2 each, 6.1%), dorsum, upper limb, and axilla (1 each, 3.0%). Of the patients, 2 (6.1%), 11 (33.3%), 15 (45.5%), and 5 (15.2%) rated the intensity of the symptoms of the keloid(s) as slight, mild, strong, and very

Table 1 Characteristics of the patients in this study

Variable		Number (% relative to the total number of patients or keloids)
Patients		30
Keloids		33
Sex	Male	12 (40.0%)
	Female	18 (60.0%)
Age	18–39 years	23 (76.7%)
	40–64 years	7 (23.3%)
	Mean (SD)	33.09 (12.79)
Location of keloids	Anterior chest	14 (42.4%)
	Ear lobe	5 (15.2%)
	Shoulder	4 (12.1%)
	Lower abdomen	3 (9.1%)
	Mandible	2 (6.1%)
	Lateral chest	2 (6.1%)
	Dorsal	1 (3.0%)
	Upper limb	1 (3.0%)
	Axilla	1 (3.0%)
	Intensity of symptoms	2 (6.1%)
Intensity of symptoms	1: Slight	2 (6.1%)
	2: Mild	11 (33.3%)
	3: Strong	15 (45.5%)
	4: Very strong	5 (15.2%)

Table 2 Keloid color measured in all patients (n=30) by using a color measurement device

Subject	Mean of measured values (SD)
Erythema level in keloid (Ek)	18.29 (4.27)
Erythema level in forearm control (Ec)	9.76 (2.93)
Ek/Ec ratios	1.96 (0.72)
Melanin level in keloid (Mk)	42.70 (6.44)
Melanin level in forearm control (Mc)	33.30 (2.65)
Mk/Mc ratios	1.32 (0.22)

strong, respectively (Table 1).

Erythema and Melanin Levels in the Keloids, as Measured with the Color Measurement Device

The Ek and Ec means (SD) were 18.29 (4.27) and 9.76 (2.93), respectively, and the Mk and Mc means (SD) were 42.70 (6.44) and 33.30 (2.65), respectively (Table 2). The Ek and Mk values were significantly higher than the Ec ($P < 1 \times 10^{-11}$) and Mc ($P < 1 \times 10^{-9}$) values, respectively. The Ek/Ec and Mk/Mc ratios were 1.96 (0.72) and 1.32 (0.22), respectively (Table 2).

Relationship of Ek and Mk to Scar Region, Severity of Symptoms, Age, and Sex

Student's *t*-test revealed that patients older than 40 years did not differ from patients younger than 40 years in terms of Ek and Mk values. Men and women also had similar Ek and Mk values. The Tukey-Kramer method re-

vealed that these values of keloids on the lower abdomen did not differ significantly from those of keloids on the chest or shoulder. Finally, Ek or Mk values of keloids that were rated as being slightly or mildly symptomatic did not differ from those of keloids that were rated as being strongly or very strongly symptomatic (Fig. 1).

Relationship between Ek/Ec and Mk/Mc Ratios and Scar Region, Severity of Symptoms, Age, and Sex

Patients younger than 40 years had significantly higher Ek/Ec ratios than did patients older than 40 years. Furthermore, women had significantly higher Ek/Ec ratios than did men. Both of these observations reflected the fact that Ec values were significantly lower in both younger patients than in older patients ($P = 0.01$) and in women than in men ($P = 0.0003$). In other words, in Japanese subjects, there is a stronger color contrast between

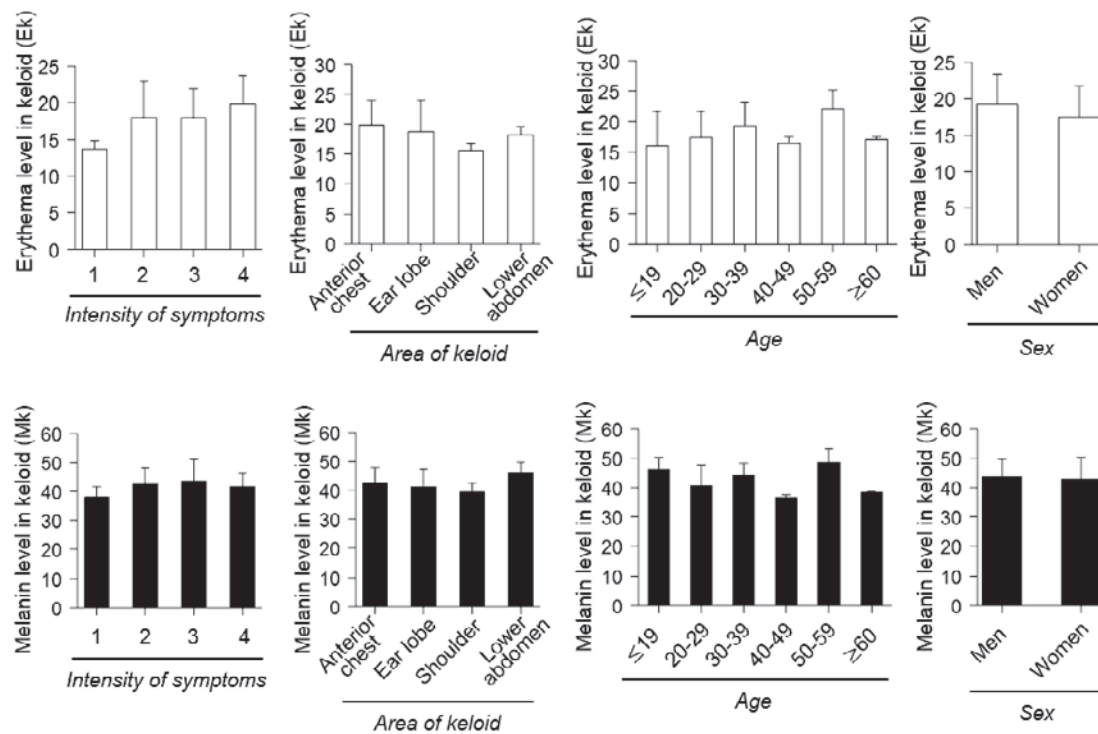


Fig. 1 Association of keloid erythema (Ek) or keloid melanin (Mk) with symptom intensity, body area, age, or sex. None of these factors associated significantly with Ek (*above*) or Mk (*below*).

the keloid and normal skin when the patient is younger or a woman than when the patient is older or a man, even though the actual erythema levels of the keloids are equivalent. The patients whose keloids were slightly or mildly symptomatic did not have Ek/Ec ratios that differed significantly from those of patients who had strongly or very strongly symptomatic keloids. Similarly, Ek/Ec ratios of keloids on the lower abdomen did not differ from those of keloids on the shoulder or chest.

The Mk/Mc ratios of keloids on the lower abdomen were significantly higher than those of keloids of the chest or shoulder (**Fig. 2**). However, the Mk/Mc ratios of keloids that were rated as slightly or mildly symptomatic did not differ from those of keloids that were rated as strongly or very strongly symptomatic. The Mk/Mc ratios was also not affected by the patients' age or sex (**Fig. 2**).

Ability of Subjective Evaluations to Distinguish between Keloids with High and Low Ek Values and between Keloids with High and Low Ek/Ec Values

We did not observe that the objectively measured Ek values of the younger or female patients differed significantly from those of older or male patients, respectively. Instead, we found that younger or female patients had significantly lower Ec values than did older or male pa-

tients, respectively, which in turn led to significant but clinically irrelevant age and sex associations with Ek/Ec ratios. This result suggested that subjective evaluations of keloid redness, which require that the keloid is compared to the surrounding skin, might overestimate the redness of keloids in younger or female patients.

To assess this possibility, 8 patients were selected on the basis of spectrophotometrically measured Ek and Ek/Ec values, as follows. The Ek values <16.5 and >20.0 were considered to be low and high, respectively, and the Ek/Ec ratios <1.65 and ≥ 1.65 were considered to be low and high, respectively. Keloids with Ek and Ek/Ec values that were both low ($n=2$), both high ($n=2$), low and high, respectively ($n=2$), and high and low, respectively ($n=2$), were selected. **Figure 3** shows 1 patient from each of the 4 groups. Photos of the 8 selected keloids were given to 6 plastic surgeons, who were asked to evaluate the keloid redness subjectively with a 10-point system. The normal skin around the keloids served for comparison.

Division of the keloids into high and low Ek groups revealed that while the high-Ek keloids did tend to be subjectively evaluated as being somewhat redder than the low-Ek keloids, a statistically significant difference with two-factor repeated measures ANOVA was not observed ($P=0.094$). In contrast, when the keloids were di-

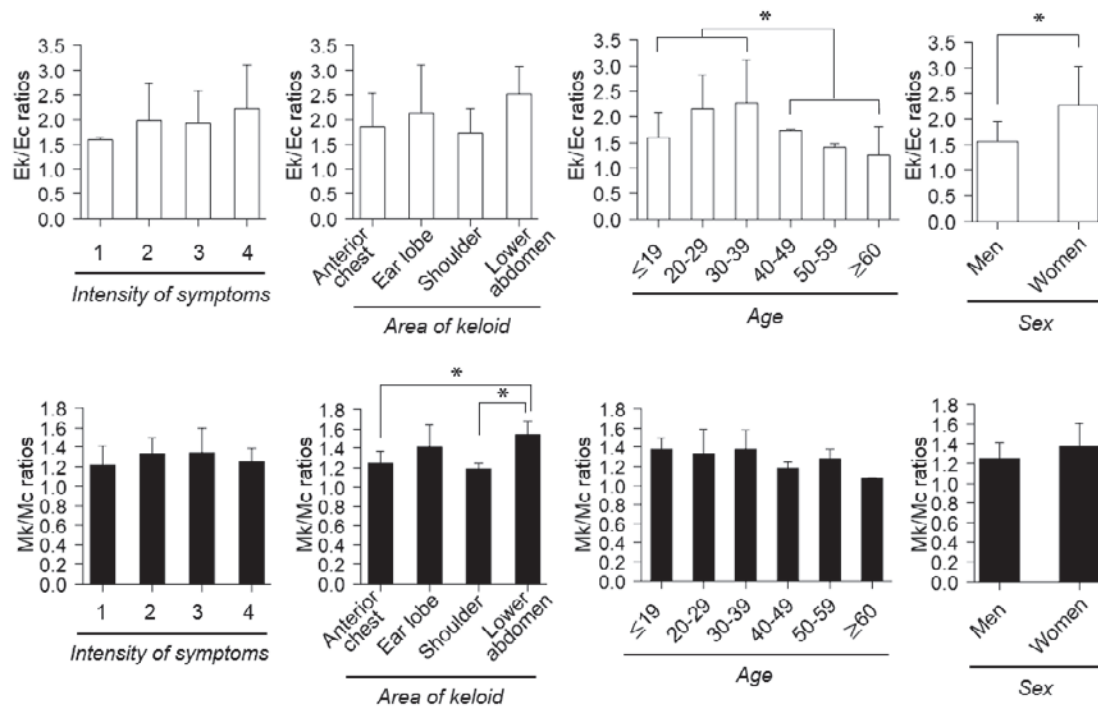


Fig. 2 Association of the Ek/Ec ratio or the Mk/Mc ratio with symptom intensity, body area, age, or sex. Patients who were younger than 40 years and women had significantly higher Ek/Ec ratios than did patient older than 40 years patients or men, respectively, but symptom intensity and body area did not associate with Ek/Ec (*above*). Patients with lower abdomen keloids had significantly higher Mk/Mc ratios that patients with chest or shoulder keloids, but symptom intensity, age, and sex was not associated with the Mk/Mc ratio (*below*). * $P < 0.05$.

vided into low and high Ek/Ec ratio groups, the high Ek/Ec ratio keloids were evaluated as being highly significantly redder than the low Ek/Ec ratio keloids ($P < 0.0001$; Fig. 4).

Discussion

Pathological cutaneous scars, such as keloids and HSs, are characterized by a diffuse redness that is caused by chronic inflammation-driven overgrowth of capillary vessels¹³. Hyperpigmentation is also commonly attributed to the inflammatory response. The mechanisms involved might be related to the activation of melanocytes by inflammatory mediators or reactive oxidative species that are released by the damaged skin¹⁴. Additional melanin is produced in response to the injury, and this production is engulfed by macrophages, which are also involved in the inflammatory response. The macrophages then retain the melanin in the dermis until the cells and melanin are degraded; in this way, the pigment can persist in the dermis for an extended period after the injury¹⁵. Notably, topical intralesional steroid injections have been shown to suppress the expression of vascular endothelial growth factor (VEGF) in keloid tissue and induce its regression

*in vivo*¹⁶. Thus, improving the inflammation in keloids might also cause the redness or pigmentation to subside. This knowledge, in turn, suggests that redness and hyperpigmentation might be important indicators of the intensity of inflammation or the effect of topical intralesional steroid injections on aberrant scars.

However, the present study has shown that the intensity of symptoms, the body region, patient age, and patient sex were not associated with keloid colors (Ek and Mk) when they were measured objectively. Thus, at least in Japanese patients, the severity of keloids/HSs cannot be evaluated on the basis of redness only, even if it is measured objectively. However, because lesion color might change during the course of treatment and, thus, can be used to estimate the therapeutic effect, the accurate evaluation of color might be useful for both the treatment and study of aberrant scarring.

Several scar assessment scales include a color assessment component. However, the present study was, to the best of our knowledge, the first to suggest that subjective evaluations of lesion color in Japanese patients are inaccurate: although young or female patients were found to have Ek/Ec ratios significantly higher than those of older

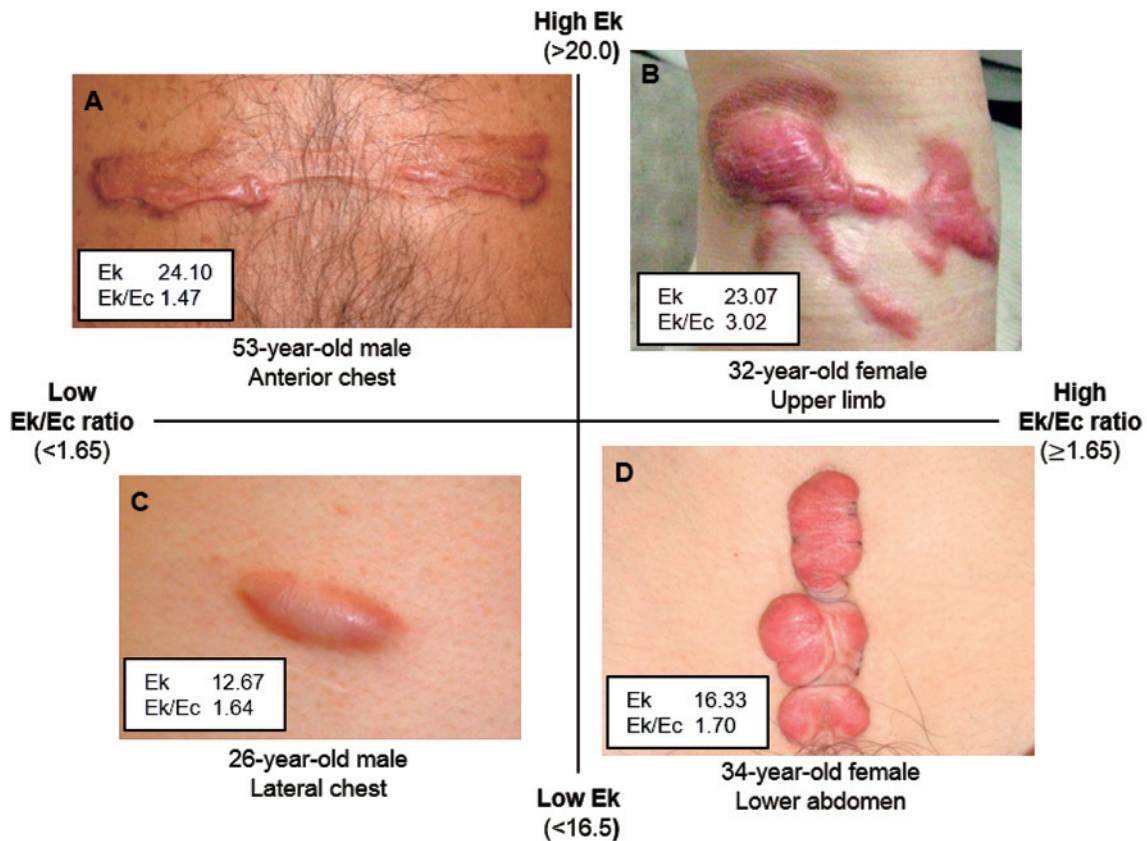


Fig. 3 Four representative patients. Keloids with Ek and Ek/Ec values that were simultaneously high and low, respectively (A), both high (B), both low (C), and low and high, respectively (D). For example, 1 patient was young (<40 years old) and female and had a keloid on the lower abdomen (D), whereas an older (>40 years old) male patient had a keloid on the anterior chest (A). The keloid in the female patient had a low Ek (defined as <16.5 see the legend to Fig. 4) of 16.33, whereas the keloid of the male patient had a high Ek (defined as >20.0 see the legend to Fig. 4) of 24.10. However, because the Ek/Ec ratio of the female patient (1.70) was higher than that of the male patient (1.47), subjective evaluations of the redness of these scars may consider the scar of the female patient to be strongly red but consider the scar of the male patient to be only moderately red.

or male patients, this increase was not because their lesions had more erythema; rather, it was because they had significantly lower erythema levels in the forearm control which resulted in a more marked contrast between the colors of the keloid and normal skin. Thus, in subjective evaluations of skin color in Japanese patients and, perhaps, also in other East Asian patients, skin lesions might be evaluated as being redder in patients with fair skin than in patients with darker skin. Indeed, this subjective error led to our now-disproven hypothesis in the present study that younger or female patients are more likely to have greater erythema (strong redness) than are older or male patients. Thus, subjective evaluations of lesion color in Japanese patients (and probably most other East Asian patients) should be approached with great caution.

The present study has shown that, although the severity of the color of keloids/HSs was difficult to judge

with the naked eye, skin color can be characterized and changes in small skin color can be quantified with the DermaSpectrometer^{®12}. Such instruments have been used for many years to quantitatively estimate the results of the treatment of pigmented lesions^{17,18}. These instruments are useful for evaluating the effectiveness of laser treatment¹⁹, for quantitatively assessing the skin erythema that is due to radiotherapy²⁰, and for evaluating scars¹¹. Thus, a DermaSpectrometer[®] or other color measurement devices can be used to estimate the color of red scars accurately and in an objective and quantitative manner. These instruments for measuring color might also be useful for evaluating the effects of therapies on keloids/HSs. When a scar is assessed, a high priority should not be placed on the subjective evaluation of color. Furthermore, the objective and accurate evaluation with color-assessment devices might be useful for monitoring HS/

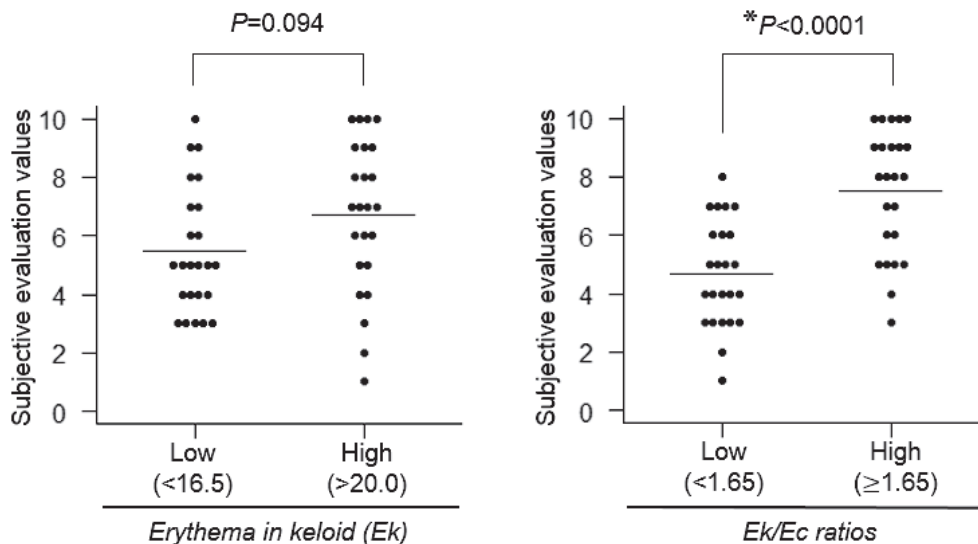


Fig. 4 Subjective evaluation of the redness of 8 keloids by 6 plastic surgeons. The 8 patients were selected on the basis of their spectrophotometrically measured Ek and Ek/Ec values, as follows. The Ek values <16.5 and >20.0 were considered to be low and high, respectively, whereas Ek/Ec ratios <1.65 and ≥ 1.65 were considered to be low and high, respectively. Patients with Ek and Ek/Ec values that were both low (n=2), both high (n=2), low and high, respectively (n=2), and high and low, respectively (n=2), were selected. The subjective evaluation values of the high and low Ek groups did not differ significantly ($P=0.063$) (left), but the keloids with high Ek/Ec ratios were evaluated as being significantly redder than the keloids with low Ek/Ec ratios ($P<0.0001$) (right).

keloid color in patients.

Conclusions

When keloid color was objectively and accurately measured with a color measurement device, the intensity of the symptoms, the body region, patient age, and patient sex were not associated with either erythema or melanin levels in the keloids. However, young or female patients were found to have statistically significantly higher Ek/Ec ratios than did older or male patients. Subjective evaluations of Ek were then shown to actually reflect these ratios rather than Ek itself. As a result, in Japanese patients and, perhaps, other East Asian patients, the lesions of patients who are young or female may be erroneously considered to be redder than the lesions of patients who are older or male when relying on subjective skin color evaluations. In contrast, a DermaSpectrometer® or other color measurement devices can be used to estimate the color of red scars accurately and in an objective and quantitative manner and, thus, might also be useful for evaluating the effects of therapies on keloids/HSs. Thus, subjective evaluations of the color of keloids or other skin disorders in Japanese patients and, probably, most other East Asian patients should be approached

with great caution.

Acknowledgements: This study received no financial support. None of the authors has a financial interest in any of the products, devices, or drugs mentioned in this manuscript.

Conflict of Interest: The authors have no conflicts of interest to declare.

References

1. Marneros AG, Krieg T: Keloids—clinical diagnosis, pathogenesis, and treatment options. *J Dtsch Dermatol Ges* 2004; 2: 905–913.
2. Ogawa R: The most current algorithms for the treatment and prevention of hypertrophic scars and keloids. *Plast Reconstr Surg* 2010; 125: 557–568.
3. Kaartinen IS, Va PO, Alander JT, Kuokkanen HO: Objective scar assessment — a new method using standardized digital imaging and spectral modelling. *Burns* 2011; 37: 74–81.
4. Beausang E, Floyd H, Dunn K, Orton C, Ferguson M: A new quantitative scale for clinical scar assessment. *Plast Reconstr Surg* 1998; 102: 1954–1961.
5. Duncan JA, Bond JS, Mason T, Ludlow A, Cridland P, O’Kane S, Ferguson MW: Visual analogue scale scoring and ranking: a suitable and sensitive method for assessing scar quality? *Plast Reconstr Surg* 2006; 118: 909–918.
6. Ogawa R, Akaishi S, Akita S, Tosa Y, Yamawaki S, Okabe K, Nagao M, Yamamoto J: JSW Scar Scale Working

- Group: Japan Scar Workshop (JSW) Scar Scale. Available online at: <http://www.scar-keloid.com/en>.
7. Jung B, Choi B, Durkin AJ, Kelly KM, Nelson JS: Characterization of port wine stain skin erythema and melanin content using cross-polarized diffuse reflectance imaging. *Laser Surg Med* 2004; 34: 174–181.
 8. Latreille J, Gardinier S, Ambroisine L, Mauger E, Tenenhaus M, Guéhenneux S, Morizot F, Tschachler E, Guinot C: Influence of skin colour on the detection of cutaneous erythema and tanning phenomena using reflectance spectrophotometry. *Skin Res Technol* 2007; 13: 236–241.
 9. Takiwaki H, Miyaoka Y, Arase S: Analysis of the absorbance spectra of skin lesions as a helpful tool for detection of major pathophysiological changes. *Skin Res Technol* 2004; 10: 130–135.
 10. Takiwaki H, Miyaoka Y, Kohno H, Arase S: Graphic analysis of the relationship between skin colour change and variations in the amounts of melanin and haemoglobin. *Skin Res Technol* 2002; 8: 78–83.
 11. Draaijers LJ, Tempelman FR, Botman YA, Kreis RW, Middekoop E, van Zuijlen PP: Colour evaluation in scars: tristimulus colorimeter, narrow-band simple reflectance meter or subjective evaluation? *Burns* 2004; 30: 103–107.
 12. Clarys P, Alewaeters K, Lambrecht R, Barel A: Skin color measurements: comparison between three instruments: the Chromameter®, the Dermaspectrometer® and the Mexameter®. *Skin Res Technol* 2000; 6: 230–238.
 13. Koike S, Akaishi S, Nagashima Y, Dohi T, Hyakusoku H, Ogawa R: Nd:YAG laser treatment for keloids and hypertrophic scars: an analysis of 102 cases. *Plast Reconstr Surg Glob Open* 2015; 2: e272.
 14. Ortonne JP, Bissett DL: Latest insights into skin hyperpigmentation. *J Invest Dermatol* 2008; 13: 10–14.
 15. Chadwick S, Heath R, Shah M: Abnormal pigmentation within cutaneous scars: a complication of wound healing. *Indian J Plast Surg* 2012; 45: 403–411.
 16. Wu W, Wang F, Yang K, Huang C, Kuo Y: Dexamethasone induction of keloid regression through effective suppression of VEGF expression and keloid fibroblast proliferation. *J Invest Dermatol* 2006; 126: 1264–1271.
 17. Lualdi M, Colombo A, Carrara M, Scienza L, Tomatis S, Marchesini R: Optical devices used for image analysis of pigmented skin lesions: a proposal for quality assurance protocol using tissue-like phantoms. *Phys Med Biol* 2006; 51: N429–440.
 18. Manousaki AG, Manios AG, Tsompanaki EI, Tosca AD: Use of color texture in determining the nature of melanocytic skin lesions—a qualitative and quantitative approach. *Comput Biol Med* 2006; 36: 419–427.
 19. Chang C, Kou C: Comparing the effectiveness of Q-switched ruby laser treatment with that of Q-switched Nd:YAG laser for oculodermal melanosis (Nevus of Ota). *J Plast Reconstr Aesthet Surg* 2011; 64: 339–345.
 20. Wengstrom Y, Forsberg C, Naslund I, Bergh J: Quantitative assessment of skin erythema due to radiotherapy—evaluation of different measurements. *Radiother Oncol* 2004; 72: 191–197.

(Received, January 28, 2016)

(Accepted, April 6, 2016)