

Clinical Complete Response from Chemotherapy in an Elderly Patient with Metastatic Gastric Cancer: A Case Report

Tetsuro Kawagoe, Yuta Maruki, Hiroyuki Nagoya, Yuki Kosugi,
Teppei Akimoto, Hiroshi Yamawaki, Yasuhiro Kodaka, Mayumi Shimpuku,
Nobue Ueki, Seiji Futagami, Kazumasa Miyake and Katsuhiko Iwakiri

Division of Gastroenterology, Department of Internal Medicine, Nippon Medical School, Tokyo, Japan

An 81-year-old man was admitted with upper abdominal pain and weight loss. Esophagogastroduodenoscopy revealed a large tumor located from the gastric angle to the body. Histological analysis of a biopsy revealed a moderately differentiated adenocarcinoma. Computed tomography revealed metastases in the liver and lung and the patient was subsequently diagnosed with metastatic advanced gastric cancer. He was treated with chemotherapy using S-1 (80 mg/m²) and cisplatin (CDDP) (60 mg/m²). Twenty-two months after chemotherapy, the gastric tumor, and the nodules in the liver and lung, had disappeared. We subsequently diagnosed a clinical complete response. The patient was treated with further S-1 monotherapy for 7 months after complete response assessment. He has lived for more than 7 years since the initial diagnosis without recurrence. Chemotherapy using S-1 and CDDP may be a potent strategy for improving survival in elderly patients with advanced gastric cancer.

(J Nippon Med Sch 2016; 83: 199–202)

Key words: elderly patients, advanced gastric cancer, chemotherapy

Introduction

Gastric cancer is currently the fourth most common cancer worldwide¹. Patients with advanced gastric cancer (AGC) have a poor prognosis with a median survival time of 3 to 6 months². According to many randomized studies, chemotherapy for AGC has been accepted as palliative treatment leading to improved survival and quality of life compared with the best supportive care³. However, most patients older than 70 years of age were excluded from these studies, and accordingly, the impact of chemotherapy has not been evaluated for these types of patients⁴. The incidence of elderly patients with gastric cancer is increasing, and the majority of these patients have advanced disease at diagnosis. Thus, it is important to develop better treatments for elderly patients with AGC. Here we report a case of an elderly patient with AGC who experienced a complete response to chemotherapy.

Case Presentation

An 81-year-old man was hospitalized for upper abdominal pain and weight loss of 5 kg over 3 months. His past history included hypertension. A physical examination revealed a hard, palpable mass in the middle upper abdomen approximately 6 cm in diameter. Laboratory data showed an elevated leukocyte count of 10,100 cells/mm³, a decreased hemoglobin level of 10.8 g/dL, and an elevated tumor marker level of carbohydrate antigen 19-9 (CA 19-9) of 67 mg/dL. Esophagogastroduodenoscopy (EGD) showed a large ulcerated tumor located from the gastric angle to the body (**Fig. 1**). Histological analysis of a biopsy specimen from the tumor revealed it as a moderately differentiated adenocarcinoma. Computed tomography (CT) showed a thickened gastric wall, lymph nodes swelling at the greater curvature of the stomach, as well as liver and lung metastases (**Fig. 2**). Based on the above findings, the cancer was clinically staged as T3 N1M1, stage IV (Union for International Cancer Control [UICC]).

Correspondence to Tetsuro Kawagoe, Division of Gastroenterology, Department of Internal Medicine, Nippon Medical School, 1-1-5 Sendagi, Bunkyo-ku, Tokyo 113-8602, Japan
E-mail: tetsuro@nms.ac.jp
Journal Website (<http://www.nms.ac.jp/jnms/>)

The patient was diagnosed with metastatic gastric cancer, and chemotherapy with S-1 (a combination of three pharmacological compounds: tegafur, gimeracil, and oteracil potassium) and cisplatin (CDDP) was initiated. Oral S-1 (80 mg/m²) was administered for 3 weeks, and intravenous (IV) CDDP (60 mg/m²) was administered on day 8. The patient received six cycles of this regimen at 14 day intervals, followed by S-1 monotherapy. Six months after initial therapy, analysis via EGD revealed that the primary tumor had become a scar (Fig. 3). Histo-

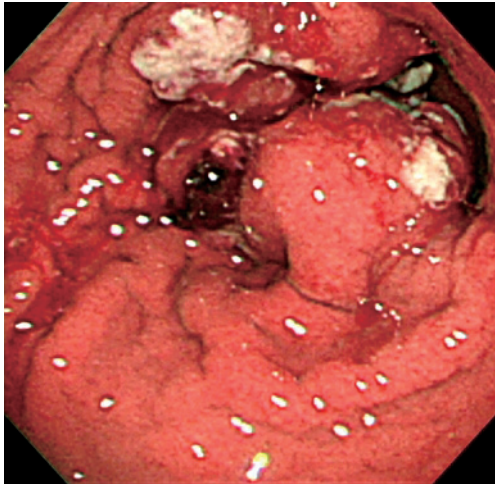


Fig. 1 Esophagogastroduodenoscopy showing a large tumor spanning from the gastric angle to the body.

logical analysis of the biopsy specimen from the scar revealed no malignancy. Eighteen and 22 months after initial therapy, the liver and lung metastases had disappeared in the CT (Fig. 4). Thus, we diagnosed the patient with a clinical complete response (CR). S-1 monotherapy was continued for a further 7 months after CR assessment.

Some of the adverse effects were grade 3 pancytopenia, based on the National Cancer Institute common toxicity criteria (NCI-CTC; version 3.0 of the toxicity scale) and febrile neutropenia (FN) from treatment with S-1 plus CDDP. Pneumonia was grade 3, enteritis was grade 2, and pancytopenia was grade 1 during S-1 monotherapy. Although S-1 plus CDDP was started at the full dose, from course 4 the drug dose was reduced to 80% because of the grade 3 adverse events. As the cumulative dose of CDDP became more than 300 mg/m², we changed to S-1 monotherapy (4 weeks of administration followed by a 2-week rest period). Because of grade 3 pneumonia after the first course of S-1 monotherapy, modified S-1 monotherapy (2 weeks of treatment followed by a 2-week rest period) was given to the patient from the second course. Two years and five months after initial therapy, when the patient was 84 years of age, chemotherapy was stopped because of grade 2 enteritis. Five years after that (7 years and 5 months after initial diagnosis), with the patient

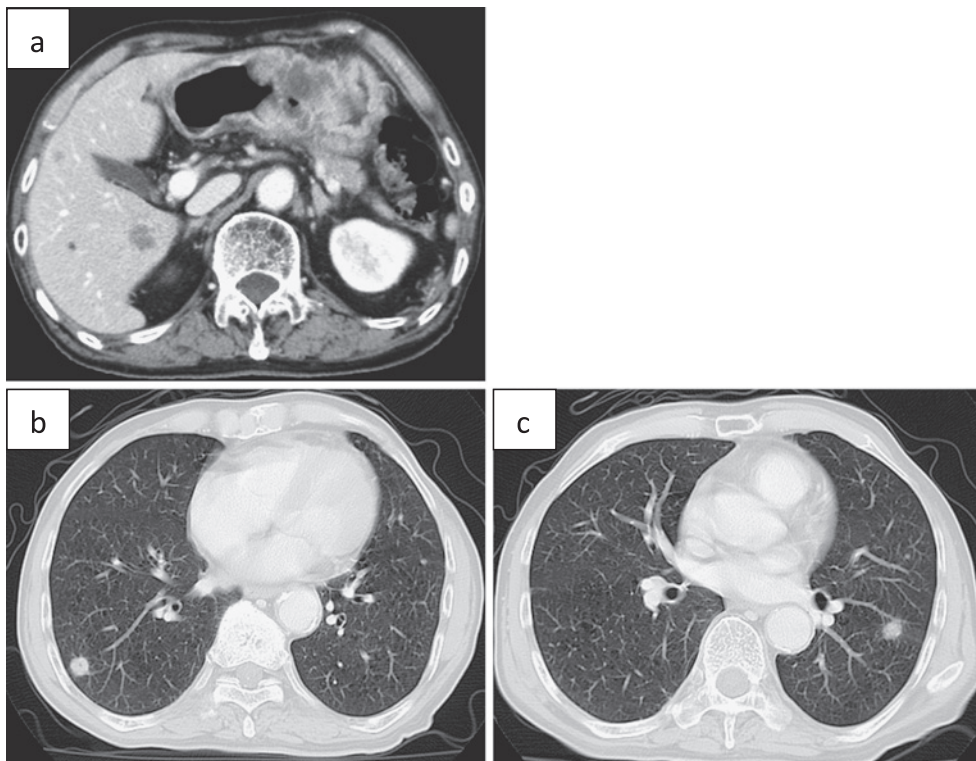


Fig. 2 Abdominal computed tomography (CT) showing gastric wall thickness and nodules in the liver (a). Chest CT shows nodules in the lung (b) and (c).

now 89 years of age, he remained free from gastric cancer.

Discussion

Although the standard chemotherapy regimen for AGC is S-1 plus CDDP in Japan, in the phase III SPIRITS trial, which compared S-1 plus CDDP with S-1 monotherapy, a

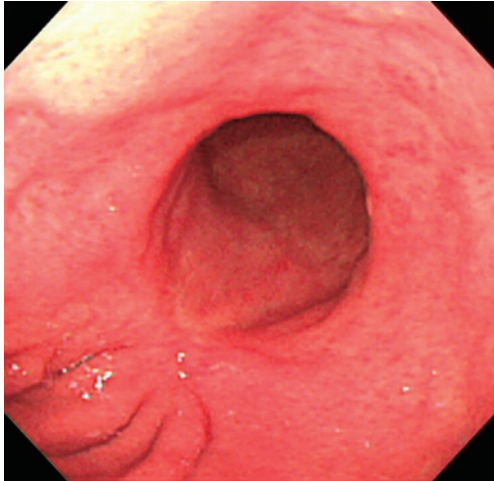


Fig. 3 Follow-up esophagogastroduodenoscopy showing a scar in the gastric angle.

subgroup analysis of the effect of S-1 plus CDDP showed no significant difference in overall survival (OS) but a significant increase in adverse events among patients who were older than 70 years of age⁵. Although there have been no phase III studies examining the treatment of elderly patients (over 70 years of age) with incurable AGC, several retrospective or phase II trials have suggested that regimens that do not include CDDP, such as S-1 monotherapy or S-1 plus oxaliplatin, might achieve a high efficacy and a more tolerable toxicity profile in elderly patients with AGC⁶⁻⁸.

There are risks connected with administration of CDDP to elderly patients. During CDDP chemotherapy, patients need to maintain adequate hydration by ingesting over 3,000 mL/day of water to avoid acute renal failure. In elderly patients, the risk of over hydration is high because of an age-related decrease in cardiac function. Additionally, monitoring of an age-related decrease in renal function is critical during administration of CDDP. For this reason, regimens that do not include CDDP have been investigated in elderly patients with AGC. In the present case, we administered S-1 plus CDDP to an 81-year-old patient because the patient had sufficient organ

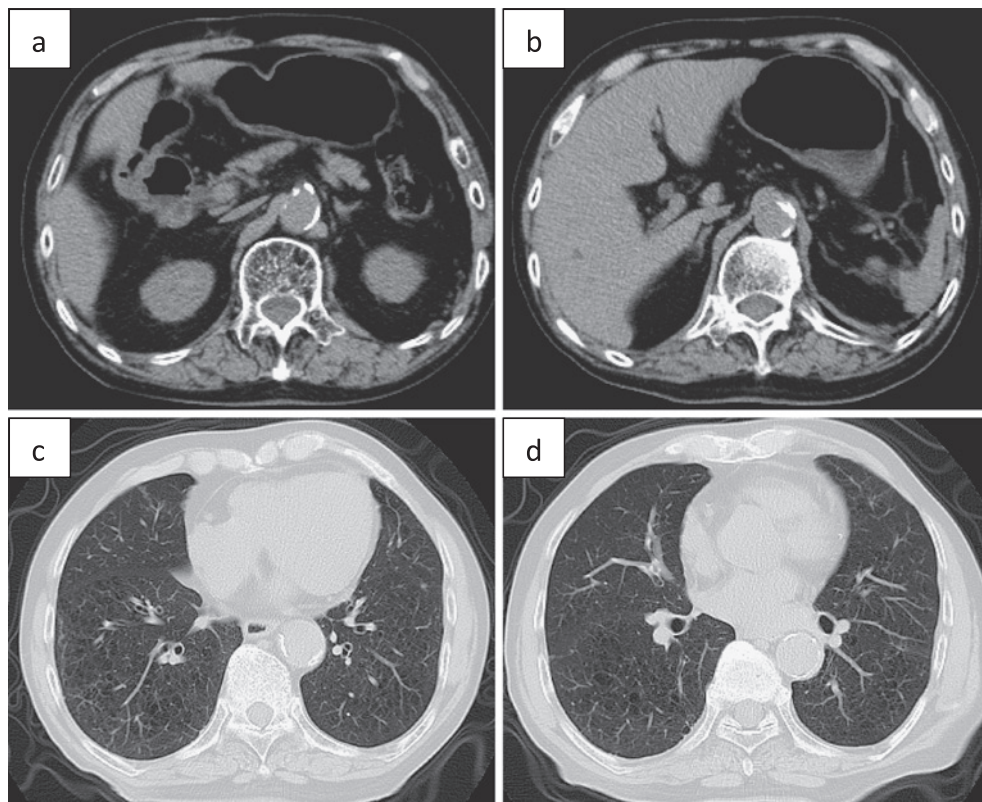


Fig. 4 Follow-up abdominal CT showing that gastric wall thickness and the nodules in the liver had disappeared, (a) and (b). Follow-up chest CT showing that the nodules in the lung had disappeared, (c) and (d).

function. The result of the therapy was a clinical CR and the patient has lived more than 7 years since initial diagnosis without recurrence. This case indicates that in elderly patients with ACG, S-1 plus CDDP chemotherapy may be as useful for elderly patients as it is for younger patients.

In this case, although the therapeutic benefit was great, the patient also experienced serious high grade adverse effects. At the time of pancytopenia and FN, the patient was given, as an inpatient, a blood transfusion, granulocyte colony-stimulating factor (G-CSF), and antibiotics. Elderly patients do not generally have a high tolerance for chemotherapy compared with younger patients, because of age related reduced organ function, such as of the heart, liver, kidney, and bone-marrow, and because of comorbidities. Therefore, a delicate balance between survival benefit and toxicity is an important consideration when treating elderly patients with chemotherapy. Physicians must take care when selecting elderly patients who are sufficiently healthy to be administered chemotherapy.

In conclusion, this case indicates that for selected elderly patients with AGC, chemotherapy of S-1 plus CDDP may be a potent strategy for improving survival, but further clinical studies will be needed to establish the most appropriate chemotherapy regimen.

Conflict of Interest: The authors declare no conflict of interest.

References

1. Jemal A, Siegel R, Ward E, Hao Y, Xu J, Thun MJ: Cancer statistics. 2009 CA Cancer J Clin 2009; 59: 225–249.
2. Wagner AD, Grothe W, Haerting J, Kleber G, Grothey A,

Fleig WE: Chemotherapy in advanced gastric cancer: a systematic review and meta-analysis based on aggregate data. J Clin Oncol 2006; 24: 2903–2909.

3. Glimelius B, Ekström K, Hoffman K, Graf W, Sjöden PO, Haglund U, Svensson C, Enander LK, Linné T, Sellström H, Heuman R: Randomized comparison between chemotherapy plus best supportive care with best supportive care in advanced gastric cancer. Ann Oncol 1997; 8: 163–168.
4. Hutchins LF, Unger JM, Crowley JJ, Coltman CA Jr, Albain KS: Underrepresentation of patients 65 years of age or older in cancer-treatment trials. N Engl J Med 1999; 341: 2061–2067.
5. Koizumi W, Narahara H, Hara T, Takagane A, Akiya T, Takagi M, Miyashita K, Nishizaki T, Kobayashi O, Takiyama W, Toh Y, Nagaie T, Takagi S, Yamamura Y, Yanaoka K, Orita H, Takeuchi M: S-1 plus cisplatin versus S-1 alone for first-line treatment of advanced gastric cancer (SPIRITS trial): a phase III trial. Lancet Oncol 2008; 9: 215–221.
6. Koizumi W, Akiya T, Sato A, Sakuyama T, Sasaki E, Tomidokoro T, Hamada T, Fujimori M, Kikuchi Y, Shimada K, Mine T, Yamaguchi K, Sasaki T, Kurihara M: Phase II study of S-1 as first-line treatment for elderly patients over 75 years of age with advanced gastric cancer: the Tokyo Cooperative Oncology Group study. Cancer Chemother Pharmacol 2010; 65: 1093–1099.
7. Zhong DT, Wu RP, Wang XL, Huang XB, Lin MX, Lan YQ, Chen Q: Combination Chemotherapy with S-1 and Oxaliplatin (SOX) as First-Line Treatment in Elderly Patients with Advanced Gastric Cancer. Pathol Oncol Res 2015; 21: 867–873.
8. Sun DS, Jeon EK, Won HS, Park JC, Shim BY, Park SY, Hong YS, Kim HK, Ko YH: Outcomes in elderly patients treated with a single-agent or combination regimen as first-line chemotherapy for recurrent or metastatic gastric cancer. Gastric Cancer 2015; 18: 644–652.

(Received, November 20, 2015)

(Accepted, December 4, 2015)