

Modified Marionette Technique for Laparoscopic Colorectal Surgery

Seiichi Shinji, Hayato Kan, Takeshi Yamada, Michihiro Koizumi,
Aya Yamagishi, Yasuyuki Yokoyama, Goro Takahashi, Takuma Iwai,
Keisuke Hara, Kohki Takeda, Keiichiro Ohta and Eiji Uchida

Department of Gastrointestinal and Hepato-Biliary-Pancreatic Surgery, Nippon Medical School, Tokyo, Japan

Introduction: Single-port laparoscopic surgery has some technical limitations with respect to control of the forceps inserted through the single-access site, which results in increased internal collisions due to coaxial alignment of the instruments, as well as and decreased range of motion and visualization. To overcome these limitations, we employ a “modified marionette technique” as a way to carry out laparoscopic colorectal surgery.

Materials and Surgical Technique: The procedures for the modified marionette technique are performed as follows: An Internal Organ Retractor (IOR)[™] and an atraumatic clip designed to firmly grasp tissue, with 1-0 nylon thread, are inserted through a 12-mm trocar and secured in place where adequate visualization and traction for cutting with a radio knife is required. A looped 1-0 nylon thread put through an 18-gauge injection needle is pierced through the abdominal wall, the looped nylon extruded, and the nylon attached to the IOR is pulled out by threading the looped nylon thread. This allows for adequate traction from outside the body through the abdominal wall and appropriate placing adjustments.

Conclusion: The “modified marionette technique” using IOR introduced here is an easy, economical, effective and safe traction technique for colorectal surgeries. This technique will be a useful tool for performing both reduced port and multiport laparoscopic colorectal surgeries.

(J Nippon Med Sch 2017; 84: 49–53)

Key words: marionette technique, laparoscopic surgery, colorectal cancer, reduced port, retraction

Introduction

In recent years, laparoscopic surgeries have become feasible and safe procedures for colorectal diseases. To decrease parietal trauma and visible scarring during laparoscopic surgeries, various approaches, such as reduced/single port access and Natural Orifice Transluminal Endoscopic Surgeries (NOTES), have been attempted¹. However, these approaches have some technical limitations, including increased internal collisions due to coaxial alignment of instruments and decreased range of motion and visualization. In some instances, additional ports are required to overcome these limitations.

In contrast, traction techniques using the abdominal wall have been reported in various fields. In 2003, Greca et al. first introduced the “marionette trick,” which is a modified suture traction technique for laparoscopic resec-

tion of an abdominal wall desmoid that overcomes difficulties with mobilizing and grasping masses using common laparoscopic instruments². Ghezzi et al. reported on the “marionette-like technique” using sutures on straight needles for the treatment of tubal pregnancy by retracting fallopian tubes³. Guru et al. introduced the “marionette technique” for robot-assisted intracorporeal creation of ileal conduits⁴. Kuroki et al. reported on the “marionette method” for trans-umbilical single-incision, two-trocar laparoscopic cholecystectomy, which is a nylon suture with a laparoscopic sliding knot to tighten the fundus of the gallbladder for suspending nylon sutures⁵. Hsu et al. introduced the “marionette technique” for 3-port laparoscopic liver resection, performed by traversing the liver edge using a 2-0 nylon straight needle line for traction and counter traction of the liver⁶. However, these

Correspondence to Seiichi Shinji, MD, PhD, Department of Gastrointestinal and Hepato-Biliary-Pancreatic Surgery, Nippon Medical School, 1-1-5 Sendagi, Bunkyo-ku, Tokyo 113-8603, Japan
E-mail: s-shinji@nms.ac.jp
Journal Website (<http://www.nms.ac.jp/jnms/>)

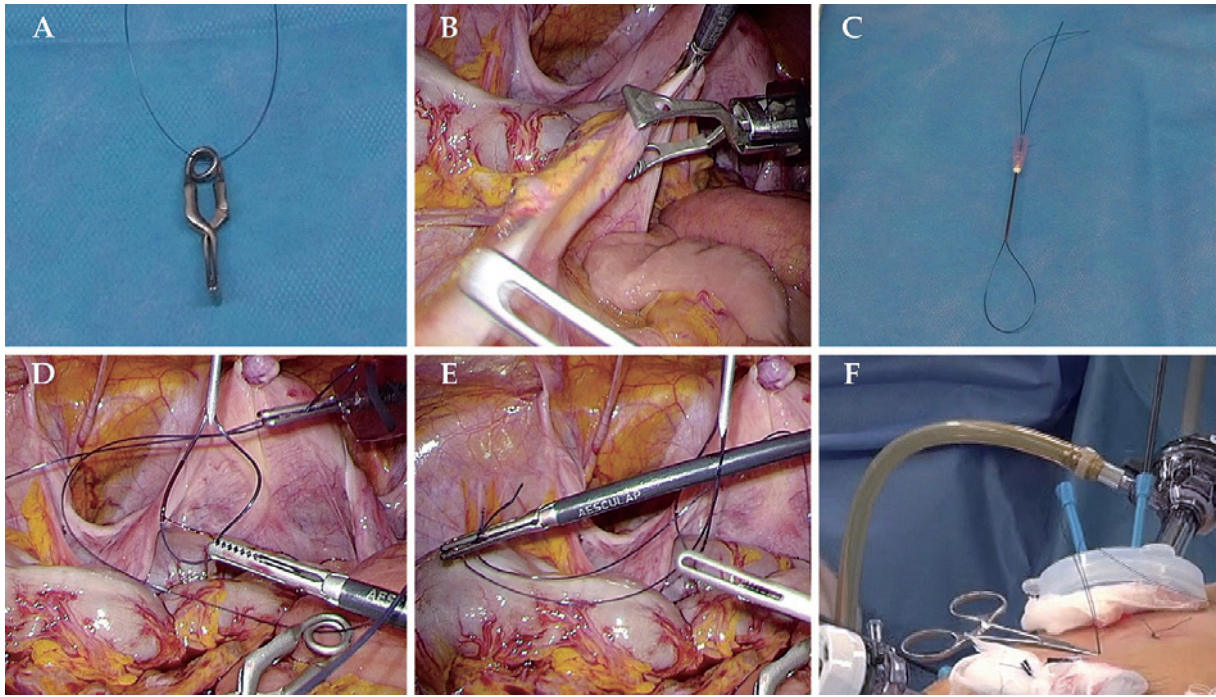


Fig. 1 Modified Marionette Technique. **A:** Internal Organ Retractor (IOR)TM attached to 1-0 nylon thread. **B:** securing apparatus where adequate visualization and traction is required. **C:** a looped 1-0 nylon threaded 18-gauge injection needle. **D:** piercing through the abdominal wall and extruding looped nylon in the abdomen. **E:** pulling out the 1-0 nylon thread attached to the IOR by threading the looped nylon. **F:** clamping the line using mosquitos for traction.

methods are traumatic and adjustments of the direction of traction are difficult.

Thus, we perform a “modified marionette technique”, which helps to safely maintain adequate counter traction instead of using a standard straight laparoscopic forceps when performing laparoscopic colorectal surgeries. We believe this technique will not only be helpful for multiport laparoscopic approaches but can also reduce the number of ports. No complications resulted from the use of this technique, and here we introduce this technique.

Materials and Surgical Technique

The procedures for the modified marionette technique are performed as follows: An Internal Organ Retractor (IOR)TM (B. Braun Aesculap, Melsungen, Germany) with 1-0 nylon suture (**Fig. 1A**), is inserted through a 12-mm trocar and secured in place where adequate visualization and traction for cutting with a radio knife is required (**Fig. 1B**). A looped 1-0 nylon thread put through an 18-gauge injection needle (**Fig. 1C**) is pierced through the abdominal wall, the looped nylon in the abdomen is extruded (**Fig. 1D**), and the 1-0 nylon thread attached to IOR is pulled out by threading the looped nylon (**Fig. 1E**). The line is subsequently clamped using mosquitos for

traction (**Fig. 1F**). This allowed for adequate traction from outside the body through the abdominal wall and appropriate changes in traction power. Furthermore, to change the retraction angle, changing the hanging part is easy using a bulldog clip Applier/Remover for atraumatic clips (B. Braun Aesculap, Melsungen, Germany) or changing the thread attached to the part of the IOR penetrating the abdominal wall using a looped 1-0 nylon threaded 18-gauge injection needle as previously stated.

This surgical technique was used in thirteen patients (seven men and six women). Eleven patients had right-side colon cancer (ileocecal resection; 7, right colectomy; 2, right hemicolectomy; 1, extended right hemicolectomy; 1) and this technique was used for suspending an ileocolic pedicle using a medial-lateral approach (**Fig. 2A**) and for traction of the ascending colon during outside detachment (**Fig. 2B**). The other two patients had rectal cancer (high anterior resection; 1, low anterior resection; 1), and this technique was used for suspending a pedicle of the inferior mesenteric artery using a medial lateral approach (**Fig. 2C**) and for mobilizing the rectum (**Fig. 2D**). Procedures were performed similar to multiport laparoscopic colorectal surgeries using the same laparoscopic instruments.

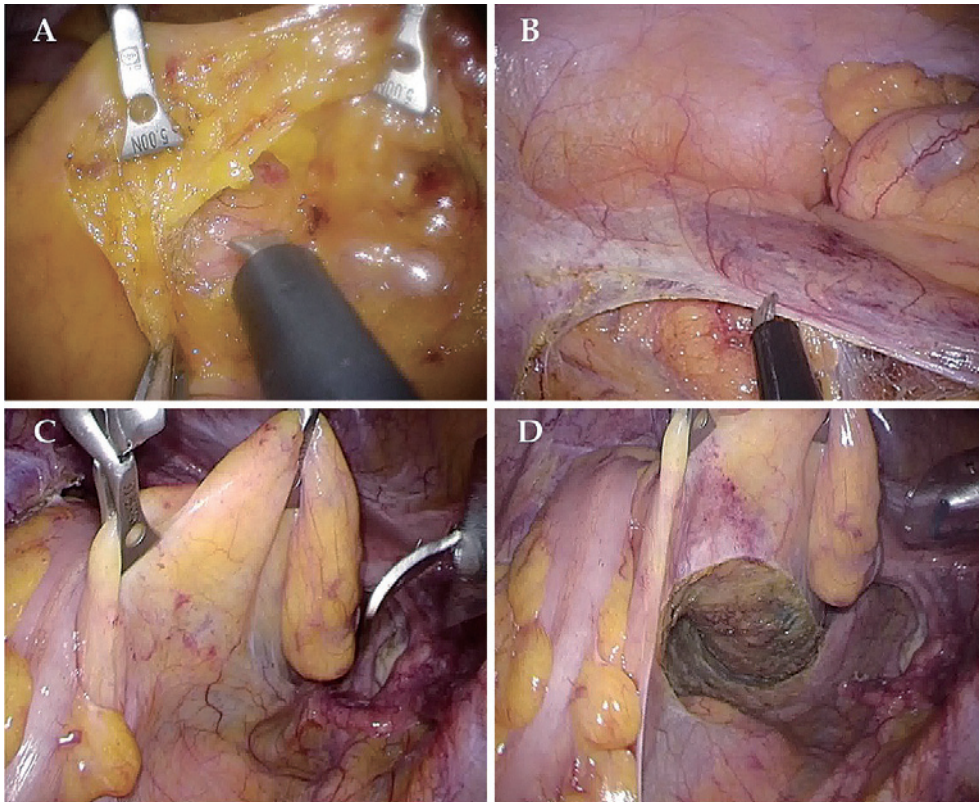


Fig. 2 Clinical Patients. **A:** suspending an ileo-colic pedicle using a medial-lateral approach during right-side colon cancer surgery. **B:** traction of ascending colon during outside detachment. **C:** suspending a pedicle of inferior mesenteric artery using a medial lateral approach during rectal cancer surgery. **D:** mobilization of the rectum.

This study was carried out in accordance with the principles of the Declaration of Helsinki (as revised in Brazil 2013). When obtaining informed consent for a surgical procedure, a general consent was also obtained from all patients for publication and presentation.

Statistical Analyses

All statistical analyses were performed with EZR (Saitama Medical Center, Jichi Medical University, Saitama Japan), which is a graphical user interface for R (The R Foundation, Vienna, Austria). More precisely, it is a modified version of R commander designed to add statistical functions frequently used in biostatistics⁷. Fisher's exact test, and Mann-Whitney *U* test were used for categorical variables comparison and analysis. All analyses were two-sided, and a *P* value of <0.05 was considered statistically significant.

Results

Seven patients in a single incision laparoscopic surgery (SILS) group who had undergone ileocecal resection with the use of the modified marionette technique between

October 2013 and October 2015 were compared with 39 patients in a conventional group who had undergone conventional 5-port ileocecal resection during the same period. There were no differences in patient characteristics, operation time, blood loss, D number, number of harvested lymph nodes, or length of postoperative stay, but wound length was significantly shorter in the SILS group (**Table 1**). All surgeries were successful. This method did not cause any tissue damage or hemorrhage during the surgery and postoperative complications were not observed.

Discussion

Surgical stress is reportedly proportionately related to the influence on the body. Therefore, performing less invasive procedures as much as possible on patients is important. For the purpose of optimizing the benefits of minimally invasive procedures, surgeons have tried to reduce overall abdominal wall incision by decreasing either the size and the number of trocars¹. However, carefully balancing technical difficulty and cosmetic outcome is required, and differences between single/reduced port and

Table 1 Clinicopathological Characteristics and Surgical findings who underwent Laparoscopy-assisted Ileocecal Resection

	SILS using modified marionette technique (n=7)	Conventional (n=39)	<i>p</i>
Sex, n (%)			0.41 [†]
Male	4 (57)	14 (36)	
Female	3 (43)	25 (64)	
Age, yr, mean (range, median)	66.0 (40–83, 70)	72.4 (40–92, 74)	0.24 [‡]
BMI, mean (range, median)	20.6 (17.1–26.4, 21.6)	21.9 (13.6–32.7, 22.6)	0.34 [‡]
Location, n (%)			0.41 [†]
C	5 (71)	18 (46)	
A	2 (29)	21 (54)	
pStage, n (%)			0.10 [†]
0	0 (0)	2 (5)	
I	5 (71)	8 (21)	
II	0 (0)	10 (26)	
IIIa	2 (29)	8 (21)	
IIIb	0 (0)	9 (23)	
IV	0 (0)	2 (5)	
OP time (min), mean (range, median)	172.1 (134–225, 166)	195.5 (132–174, 194)	0.13 [‡]
Blood loss (mL), mean (range, median)	11.7 (0–20, 10)	32.8 (0–220, 15)	0.26 [‡]
D number, mean±SD	2.9±0.4	2.9±0.4	0.80 [¶]
LN's harvested, mean (range, median)	19.9 (16–27, 18)	18.9 (2–35, 18)	0.76 [‡]
Wound length (mm), mean (range, median)	39.3 (30–60, 40)	69.3 (57–107, 67)	<0.001 [‡]
Post OP stay (day), mean (range, median)	8.4 (5–19, 7)	9.1 (6–38, 8)	0.74 [‡]

SILS: Single incision laparoscopic surgery, [†] Fisher's exact test, [‡] t test, [¶] Mann-Whitney U test

multiport laparoscopic approaches should not be observed⁸.

The standard technique for colorectal surgeries involves the placement of five trocars and requires adequate flexible counter traction to mobilize the colon and rectum with assistant's forceps. Our technique can provide appropriate strain continuously via threads through the abdominal wall like a marionette without inserting additional ports. In laparoscopic colorectal surgeries, some techniques have been reported as follows: the magnetic retraction system using intracorporeally detached instruments⁹, and intracorporeal attachable and detachable instruments retracted with a fine-loop retractor¹⁰. In other fields, various marionette techniques have been reported^{2–6}; however, all of these techniques were fixed to one location and traction angle adjustments were difficult, thereby preventing use in the colorectal field. Thus, we perform a "modified marionette technique," using IOR, an atraumatic clip designed to firmly grasp tissue, to easily grasp areas using an Applier/Remover for atraumatic clips as necessary. Furthermore, replacement of the thread attached to the IOR penetrating site on the abdominal wall using a looped 1-0 nylon threaded 18-gauge injection needle can be performed at will and low

cost. Conversely, Choo et al. reported on the utility of using a silicone ring combined with IOR by affixing the anchoring needle to the abdominal wall when performing urologic laparoscopic single port surgeries¹¹. However, during laparoscopic colorectal surgeries, frequent changes are required for adequate counter traction and, thus, if this technique is utilized, frequent readjustments of the IOR by moving the anchoring needles in order to get optimal traction would be required.

In summary, the "modified marionette technique" we describe here using IOR with manual assistance via threads through the abdominal wall is an easy, economical, effective and safe traction technique and tool for laparoscopic colorectal surgeries. This technique will be a useful tool for performing both single/reduced port and multiport laparoscopic colorectal surgeries using the same laparoscopy instruments.

Conflict of Interest: The authors have no conflicts of interest to disclose and received no financial support for this study.

References

1. Sehgal R, Cahill RA: Advanced laparoscopic surgery for colorectal disease: NOTES/NOSE or single port? Best

- Pract Res Clin Gastroenterol 2014; 28: 81–96.
2. La Greca G, Randazzo V, Barbagallo F, Di Stefano A, Greco L, Rapisarda D, Russello D: Laparoscopic resection of an abdominal wall desmoid using a modified suture traction technique: the “marionette trick”. *Surg Endosc* 2003; 17: 2028–2031.
 3. Ghezzi F, Cromi A, Fasola M, Bolis P: One-trocar salpingectomy for the treatment of tubal pregnancy: a ‘marionette-like’ technique. *BJOG* 2005; 112: 1417–1419.
 4. Guru K, Seixas-Mikelus SA, Hussain A, Blumenfeld AJ, Nyquist J, Chandrasekhar R, Wilding GE: Robot-assisted intracorporeal ileal conduit: Marionette technique and initial experience at Roswell Park Cancer Institute. *Urology* 2010; 76: 866–871.
 5. Kuroki T, Adachi T, Kitasato A, Okamoto T, Tajima Y, Kanematsu T: Marionette method for transumbilical single-incision, two-trocar laparoscopic cholecystectomy: a new, simple technique. *Hepatogastroenterology* 2011; 58: 729–731.
 6. Hsu KF, Liu TP, Yu JC, Chen TW, Shih ML, Ou KL, Chen CJ, Chan DC, Hsieh CB: Application of marionette technique for 3-port laparoscopic liver resection. *Surg Laparosc Endosc Percutan Tech* 2012; 22: e186–189.
 7. Kanda Y: Investigation of the freely available easy-to-use software ‘EZR’ for medical statistics. *Bone Marrow Transplant* 2013; 48: 452–458.
 8. Poon JT, Cheung CW, Fan JK, Lo OS, Law WL: Single-incision versus conventional laparoscopic colectomy for colonic neoplasm: a randomized, controlled trial. *Surg Endosc* 2012; 26: 2729–2734.
 9. Uematsu D, Akiyama G, Magishi A, Nakamura J, Hotta K: Single-access laparoscopic left and right hemicolectomy combined with extracorporeal magnetic retraction. *Dis Colon Rectum* 2010; 53: 944–948.
 10. Uematsu D, Magishi A, Sano T, Niitsu H: Single-scar laparoscopic colectomy with intracorporeal attachable and detachable instruments. *Dis Colon Rectum* 2012; 55: 815–820.
 11. Choo SH, Jung W, Jeong U, Jeong BC, Han DH: Initial experiences of a novel self-retaining intracorporeal retractor device for urologic laparoendoscopic single-site surgery. *J Endourol* 2014; 28: 404–409.

(Received, August 30, 2016)

(Accepted, January 6, 2017)