

## Laparoscopic Excision of a Uterine Adenomatoid Tumor and a Coexisting Ovarian Teratoma: A Case Report and Literature Review

Tomohiko Matsushashi<sup>1</sup>, Ryoko Matsui<sup>1</sup>, Chikako Hasegawa<sup>2</sup>,  
Tsutomu Hatori<sup>2</sup>, Seiryu Kamoi<sup>1</sup> and Toshiyuki Takeshita<sup>3</sup>

<sup>1</sup>Department of Obstetrics and Gynecology, Nippon Medical School Chiba Hokusoh Hospital, Chiba, Japan

<sup>2</sup>Department of Pathology, Nippon Medical School Chiba Hokusoh Hospital, Chiba, Japan

<sup>3</sup>Department of Obstetrics and Gynecology, Nippon Medical School, Tokyo, Japan

Adenomatoid tumors (ATs) are rare, benign neoplasms occurring mainly in reproductive organs such as the uterus, ovaries, fallopian tubes, and testes. Uterine adenomatoid tumors (UATs) are generally incidentally diagnosed during histopathological examination of excisional biopsies performed for other indications, most commonly uterine leiomyomas. We herein present a 38-year-old woman who underwent laparoscopic excision of a uterine leiomyoma and a right ovarian teratoma. Microscopic examination of the excisional biopsy revealed that the enucleated uterine tumor was composed of proliferating glandular tissue covered with single-layered cells that were surrounded by proliferating smooth muscle cells, corresponding exactly to the features of UATs. The excised ovarian cyst was confirmed to be a typical mature cystic teratoma. According to these histopathological findings, the patient was finally diagnosed with a UAT and coexisting teratoma. No recurrence was detected up to 6 months after excision. To the best of our knowledge, this is the eighth case report on laparoscopically enucleated UATs. Although recurrence risk may be low in UATs, further case reports are necessary to elucidate the safety and validity of laparoscopic excision for UATs. (*J Nippon Med Sch* 2017; 84: 139–143)

**Key words:** adenomatoid tumor, laparoscopic surgery, uterus, teratoma

### Introduction

Adenomatoid tumors (ATs) are rare, benign tumors that mainly arise in the uterine body, ovaries, fallopian tubes, and testes<sup>1,2</sup>. Sixty percent of uterine adenomatoid tumors (UATs) coexist with uterine leiomyomas<sup>3</sup>. UATs are usually diagnosed as uterine leiomyomas or fibroids preoperatively, and extra perioperative care should be taken for complete excision because the border between UATs and myometrium is often ill-defined as compared to typical uterine fibroids. Herein, we present a rare case of a laparoscopically excised UAT coexisting with an ovarian teratoma, and review previous reports to assess the efficacy of laparoscopic surgery for UATs.

### Case Report

A 38-year-old nulliparous woman was referred to our hospital for an incidentally discovered uterine tumor and

right ovarian cyst. She had no relevant past history or subjective complaints including dysmenorrhea, abdominal pain, or infertility. Pelvic ultrasonography and pelvic magnetic resonance imaging (MRI) revealed a 5-cm well-circumscribed mass in the anterior uterine wall, along with an 8-cm cystic mass in the right ovary. The uterine mass was iso-intense on T1-weighted images (T1WI), and hypo-intense on T2-weighted images (T2WI). Compared with normal myometrium, this uterine mass showed less gadolinium (Gd) enhancement (**Fig. 1A**). In addition, the uterine mass appeared hypo-intense on diffusion-weighted images (DWI) that were obtained to evaluate the cellular density (**Fig. 1B**). The right ovarian cystic mass was hyper-intense on T1WI images (**Fig. 1C**), and was extremely hypo-intense on fat suppression (**Fig. 1D**).

Suspecting a uterine leiomyoma coexisting with a right ovarian teratoma, laparoscopic-assisted myomectomy and

---

Correspondence to Tomohiko Matsushashi, MD, PhD, Department of Obstetrics and Gynecology, Nippon Medical School Chiba Hokusoh Hospital, 1715 Kamagari, Inzai, Chiba 270-1694, Japan

E-mail: t-matsushashi@nms.ac.jp

Journal Website (<http://www2.nms.ac.jp/jnms/>)

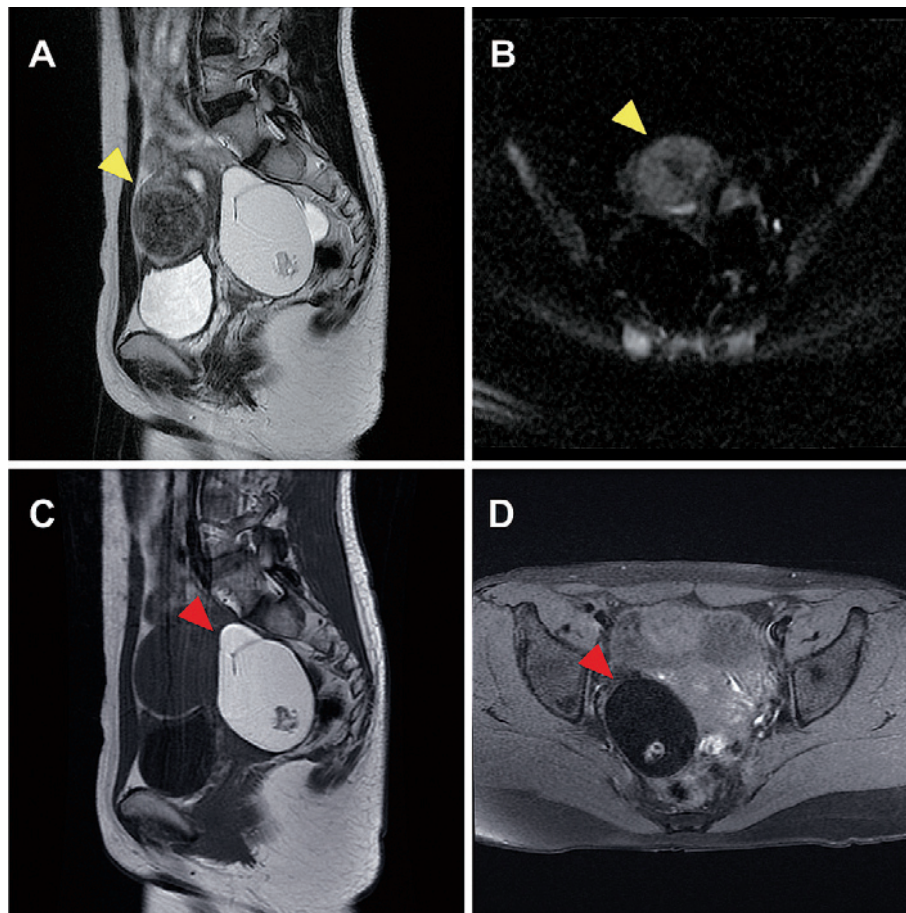


Fig. 1 Magnetic resonance imaging features of uterine adenomatoid tumors. A 5-cm well-circumscribed mass can be observed in the anterior uterine wall (**yellow arrowhead**), with hypo-intensity on both T2WI (A) and DWI (B), and less Gd enhancement, compared to the normal myometrium (A). An 8-cm right ovarian cyst (**red arrowhead**) showing hyper-intensity on T1WI (C), and extreme hypo-intensity with fat suppression (D).

laparoscopic-assisted cystectomy were performed. Briefly, the patient was placed in the lithotomy position, and then, under general anesthesia, a 1.5-cm vertical incision was made in the umbilical region to insert the lifting device and a 5-mm port. Two additional 5-mm ports were inserted from the left and right lower quadrants, respectively. A 3-cm transverse incision was made in the median suprapubic region mainly to remove the laparoscopically excised tumors without morcellation. During laparoscopic exploration, a hen-egg sized rounded tumor was identified in the anterior uterine wall (**Fig. 2A**). After injecting diluted vasopressin into the myometrium, a vertical incision was made (**Fig. 2B**). The border between the uterine mass and the normal myometrium was clear, and both the uterine and the right ovarian masses were completely enucleated (**Fig. 2C**). After removal of the uterine mass, the uterine wall was reconstructed by suturing it in

two layers with absorbable stitches (2-0 Coated VICRYL<sup>®</sup>, ETHICON Inc., Somerville, NJ, USA) (**Fig. 2D**).

The operative time was 107 minutes, and the total blood loss was 10 mL. On macroscopic observation, the excised uterine mass was white, globular, measuring 4.6 × 3.6 cm, with a smooth outer surface and firm consistency, similar to a leiomyoma. On histopathological examination, the uterine mass was composed of proliferating glandular tissue covered with single-layered flattened cells and surrounded by proliferating smooth muscle cells (**Fig. 3A, 3B**). To confirm that these histological features were homogenous and consistent throughout the tumor, multiple biopsies were examined from the excised specimen. In all these biopsies, no cellular atypia or mitotic activity was observed, and no coexisting leiomyoma was found, even on detailed examination. Immunohistochemical staining revealed that the single-layered tumor

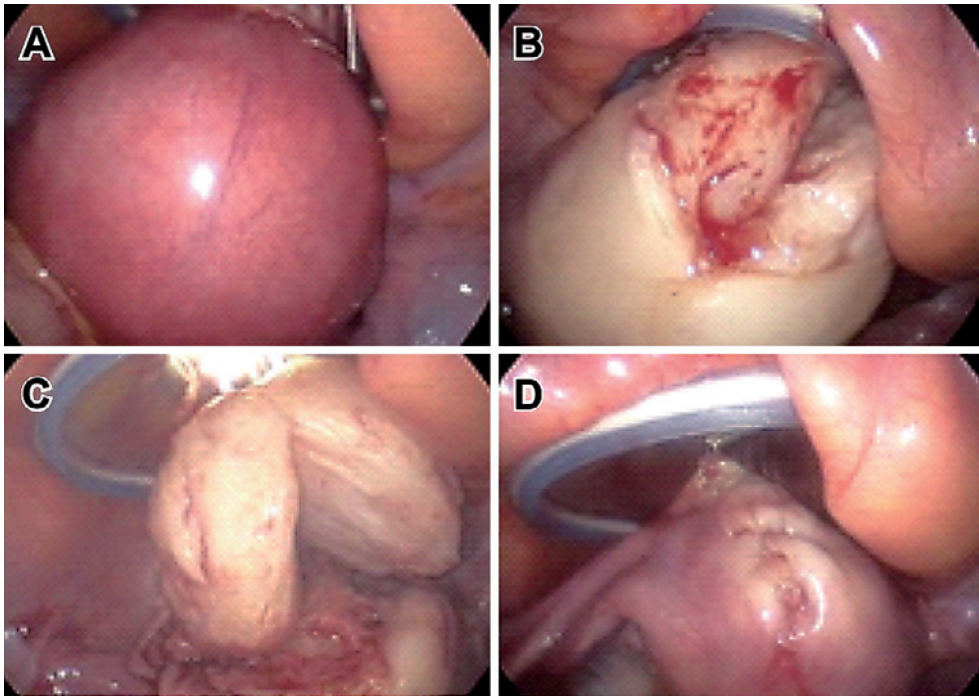


Fig. 2 Intraoperative images of uterine adenomatoid tumors. (A) A rounded tumor was seen in the uterine anterior wall. (B) A vertical incision was made above the tumor, followed by injection of diluted vasopressin into the myometrium. The border between the tumor and myometrium was clearly separated. (C) The enucleated uterine tumor. (D) The myometrium was reconstructed with absorbable stitches (baseball suturing).

cells were positive for cytokeratin (CK) AE1/AE3 (Fig. 3C), CK 7 (Fig. 3D), epithelial markers, calretinin (Fig. 3E), and mesothelial markers; and negative for cluster of differentiation (CD) 31 (Fig. 3F), CD 34 (Fig. 3G), D2-40 (podoplanin) (Fig. 3H), and endothelial markers.

According to the identified markers, the uterine mass was diagnosed as an adenomatoid tumor. The coexisting ovarian mass was a typical mature cystic teratoma consisting of ectodermal tissues such as fat, hair, and nerves; mesodermal tissues such as bone and cartilage; and endodermal tissues such as bronchial and gastrointestinal mucosae, smooth muscle, and thyroid tissue. The postoperative period was unremarkable, and she was discharged on postoperative day 4. There has been no recurrence up to 6 months from the laparoscopic excision of the UAT and teratoma. The patient provided verbal and written consent for the use of her anonymized clinical records for research, including the publication of this case report.

#### Discussion

Although the accurate frequency of UATs' occurrence is unknown as they are incidentally diagnosed, Tiltman et al. reported that 12 of 1,000 (1.2%) hysterectomy speci-

mens contained UATs<sup>4</sup>. On the other hand, Nakayama et al. advocated that the frequency of UATs is greater than that previously reported because microscopic examination revealed coexistent UATs in 9 of 199 cases (5%) that were treated with uterine tumor resection or hysterectomy<sup>5</sup>.

UATs are generally detected as small (less than 2–3 cm), solitary solid lesions<sup>6</sup>, and are histopathologically formed from glandular tissue covered with single-layered, flattened epithelial cells surrounded by hypertrophic smooth muscle cells. On immunohistochemical examination, UATs stain positive for cytokeratin and calretinin, and negative for CD31 and CD34; thus, they are considered mesothelial tumors<sup>6,7</sup>. To date, no malignant transformation of UATs or metastasis to other organs has been reported.

Similar to our case, almost all UATs are initially diagnosed as leiomyomas or fibroids before the microscopic examination of resected specimens<sup>4,5</sup>. To improve the preoperative accuracy of differentiating between UATs and leiomyomas, Meng et al. retrospectively reviewed the MRI features of 26 patients with UATs confirmed by histopathology<sup>8</sup>. UATs were typically iso-intense on T1WI and hypo-intense on T2WI, with a median size of 3.8 cm



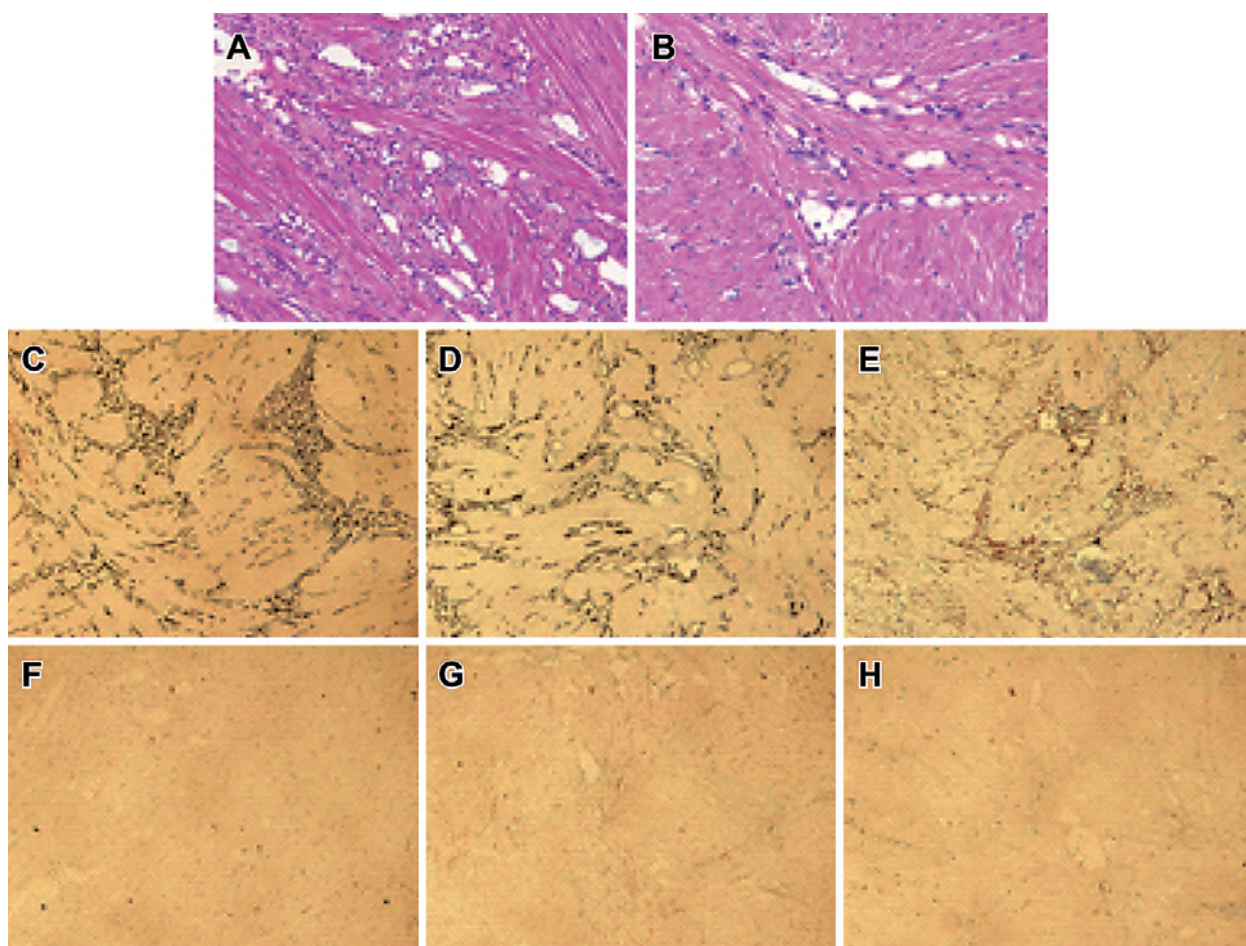


Fig. 3 Microscopic appearance of uterine adenomatoid tumors. Proliferating tubular glandular tissue was covered with single-layered flattened cells between bundles of smooth muscle. Hematoxylin and eosin staining. Low ( $\times 20$ , A) and high ( $\times 40$ , B) magnifications. (C, D, E, F, G, H) The tumor cells stained positive for CK AE1/3, CK7, and calretinin, and negative for CD31, CD34, and D2-40.

(range: 1–7 cm). The authors postulated that the hypo-intensity on T2WI might be owing to the pathologic features of UATs, which consist of flattened mesothelial cells surrounded by a smooth muscle component. More than 90% of UATs show a solid pattern, and the degree of Gd enhancement is lower than that of the myometrium in 75% of cases. The glandular structures and tubular cavities, which characterize UATs, are thought to correlate with their low enhancement. The authors concluded that small uterine masses with hypo-intensity on T2WI and lower Gd enhancement than the myometrium may indicate a diagnosis of UATs. These MRI features match the features of our case, except for the intensity of UATs on DWI, which has not been mentioned in previous articles and remains to be assessed.

Seven cases of laparoscopically resected UATs were previously reported between 2009 and 2011<sup>9–13</sup> (Table 1). The patients' ages (range: 19–39 years; median: 34 years)

and tumor sizes (range: 2.1–7.8 cm; median: 6.3 cm) were similar to those of our case. All cases were preoperatively diagnosed as uterine fibroids.

The frequency of coexisting UATs and teratomas is less, and the relationship between them is less apparent. Hong et al. reported a case of a UAT coexisting with an ovarian teratoma, both of which were successfully resected laparoscopically<sup>11</sup>.

Although no recurrence or intraperitoneal implantation of UATs was recognized in these laparoscopically resected cases, the operative procedure for resection of UATs should be determined because there is no conclusion yet. Sieunarine et al. reported an instructive case of a submucosal UAT that relapsed three times after transcervical resection of the tumor<sup>14</sup>. They achieved complete resection of the UAT by using the Strassman technique. As mentioned above, the border between the uterine mass and the normal myometrium is often poorly deline-

Table 1 Previous reports on laparoscopic resection of UATs

Author	Year Published	Age	Parity	Chief Complaint	Preoperative Diagnosis	Procedure	Tumor Size (cm)
Hong R, et al <sup>11</sup>	2009	24	unknown	Lower abdominal pain	Uterine fibroid	Laparoscopically-assisted transvaginal resection	4.5
Kalidindi M, et al <sup>10</sup>	2010	39	0	Lower abdominal pain	Uterine fibroid	Laparoscopic enucleation	6.9
		36	0	Infertility	Uterine fibroid	Laparoscopic enucleation	6.3
Yazawa H, et al <sup>9</sup>	2011	37	0	Infertility	Uterine fibroid	Laparoscopically-assisted enucleation	5
Alkatout I, et al <sup>13</sup>	2011	26	0	Symptomatic ovarian cyst	Uterine fibroid	Laparoscopic enucleation	2.1
		19	0	Lower abdominal pain, back pain, dyspareunia	Uterine fibroid	Laparoscopic enucleation	5
Sakurai N, et al <sup>12</sup>	2011	34	0	Nothing	Uterine fibroid	Laparoscopic enucleation	7.8

ated in UATs, so the incidence of postoperative residual lesion in UATs is thought to be higher compared to uterine fibroids. Therefore, more intensive intraoperative exploration and complete resection are necessary for UATs to avoid re-operating. The present case report, to our knowledge, is the eighth report of a UAT that was excised laparoscopically. Compared to uterine fibroids, the relatively small size and hypo-intensity on T2WI with lower Gd enhancement, compared to myometrium on MRI, might point to a preoperative diagnosis of UAT. The definitive diagnosis of UATs should be based on histopathology. While UATs are thought to have a low potential for relapse or metastasis based on their histopathological features and previous case reports, further case reports are needed to evaluate the safety and validity of laparoscopic surgery, because residual tumors may be more common in UATs as they are poorly delineated from the surrounding myometrium.

**Conflict of Interest:** None.

### References

1. Manucha V, Azar A, Shwayder JM, Hudgens JL, Lewin J: Cystic adenomatoid tumor of the uterus. *J Cancer Res Ther* 2015; 11: 967-969.
2. Ranjan R, Singh L, Nath D, Sable MN, Malhotra N, Bhatla N, Kumar S, Datta Gupta S: Uterine adenomatoid tumors: a study of five cases including three cases of the rare leiomyoadenomatoid variant. *J Obstet Gynaecol India* 2015; 65: 255-258.
3. Nogales FF, Isaac MA, Hardisson D, Bosincu L, Palacios J, Ordi J, Mendoza E, Manzarbeitia F, Olivera H, O'Valle F, Krasević M, Márquez M: Adenomatoid tumors of the uterus: an analysis of 60 cases. *Int J Gynecol Pathol* 2002; 21: 34-40.
4. Tiltman AJ: Adenomatoid tumours of the uterus. *Histopathology* 1980; 4: 437-443.
5. Nakayama H, Teramoto H, Teramoto M: True incidence of uterine adenomatoid tumors. *Biomed Rep* 2013; 1: 352-354.
6. Crum CP, Nucci MR, Lee KR: *Diagnostic Gynecologic and Obstetric Pathology*, 2nd edition. 2006; Elsevier Saunders, Philadelphia.
7. Terada T: An immunohistochemical study of adenomatoid tumors of the uterus and fallopian tube. *Appl Immunohistochem Mol Morphol* 2012; 20: 173-176.
8. Meng Q, Zeng Q, Wu X, Wan Q, Lei Y, Song T, Gu X, Hong G, Zhang W, Li X: Magnetic resonance imaging and pathologic findings of 26 cases with uterine adenomatoid tumors. *J Comput Assist Tomogr* 2015; 39: 499-505.
9. Yazawa H, Endo S, Hayashi S, Suzuki S, Ito A, Fujimori K: Spontaneous uterine rupture in the 33rd week of IVF pregnancy after laparoscopically assisted enucleation of uterine adenomatoid tumor. *J Obstet Gynaecol Res* 2011; 37: 452-457.
10. Kalidindi M, Odejinmi F: Laparoscopic excision of uterine adenomatoid tumour: two cases and literature review. *Arch Gynecol Obstet* 2010; 281: 311-315.
11. Hong R, Choi DY, Choi SJ, Lim SC: Multicentric infarcted leiomyoadenomatoid tumor: a case report. *Int J Clin Exp Pathol* 2009; 2: 99-103.
12. Sakurai N, Yamamoto Y, Asakawa Y, Taoka H, Takahashi K, Kubushiro K: Laparoscopically resected uterine adenomatoid tumor with coexisting endometriosis: case report. *J Minim Invasive Gynecol* 2011; 18: 257-261.
13. Alkatout I, Bojahr B, Dittmann L, Warneke V, Mettler L, Jonat W, Schollmeyer T: Precarious preoperative diagnostics and hints for the laparoscopic excision of uterine adenomatoid tumors: two exemplary cases and literature review. *Fertil Steril* 2011; 95: 1119.e5-8.
14. Sieunarine K, Cowie AS, Bartlett JD, Lindsay I, Smith JR: A novel approach in the management of a recurrent adenomatoid tumor of the uterus utilizing a Strassman technique. *Int J Gynecol Cancer* 2005; 15: 671-675.

(Received, October 18, 2016)

(Accepted, January 19, 2017)