

Subcuticular Suturing with Closed Suction Drainage for Wound Closure Following Stoma Reversal

Kazuhiko Yoshimatsu, Masano Sagawa, Hajime Yokomizo, Yuki Yano, Sachiyo Okayama, Masaya Satake, Yasufumi Yamada, Atsuo Matsumoto, Shunichi Shiozawa, Takeshi Shimakawa, Takao Katsube and Yoshihiko Naritaka

Department of Surgery, Tokyo Women's Medical University, Medical Center East, Tokyo, Japan

Incisional surgical site infection (SSI) is a leading complication of stoma reversal procedures. This retrospective study was conducted to assess the incidence of incisional SSI and other wound complications when wound closure was achieved by subcuticular suturing and closed suction drainage following stoma reversal. We analyzed data from a total of 49 patients, all of whom had undergone insertion of a 10 Fr closed suction drainage tube in the fascia, following irrigation with approximately 300 mL of physiological saline. We then performed subcuticular suturing with 4-0 monofilament absorbable sutures. The median age of our patient population (34 men and 15 women) was 68 (range, 35–84) years. Six patients had an end stoma and 43 had a loop stoma. The wound category was 'contaminated' in 18 patients, while an incisional SSI was observed in one patient (2.0%). No wound disruptions, seromas, or drain infections were evident. Our data are reliable, but our study is limited in terms of general applicability; however, the low SSI rate indicates that the procedure is acceptable. Further research into this procedure will require a randomized trial design. (*J Nippon Med Sch* 2018; 85: 183–186)

Key words: subcuticular suture, closed suction drain, stoma reversal, wound infection

Introduction

Incisional surgical site infection (SSI) is a leading complication in colorectal surgery^{1,2}, especially in stoma creation and closure³. It is also one of the most frequent complications following stoma closure. Several studies have reported a 40% incidence in incisional SSI, a complication which increases medical costs and prolongs a patient's hospital stay^{1,2,4}. A prospective randomized study and meta-analysis found that delayed primary closure decreased the rate of wound infection more readily than conventional primary closure^{5,6}. However, the optimal timing of wound closure following stoma takedown has yet to be determined. All patients with delayed sutures must receive dressing before closure, which can be painful. Recent reports have found that purse-string suturing is superior to conventional suturing after stoma takedown, with a reported incidence of incisional SSI of less than 10%^{7–10}.

Subcuticular suturing is usually used in plastic surgery

because it enables primary wound healing to occur with wound closure. A recent meta-analysis of randomized controlled trials found abdominal wound closure with subcuticular suturing to be superior, with regard to wound complications, to the use of a skin stapler after caesarean delivery¹¹. Kobayashi et al. also reported that subcuticular skin closure protected against incisional SSI after closure of a diverting stoma¹². While this has not been demonstrated by a randomized controlled study, additional subcutaneous drainage could lower the rates of incisional SSI in some higher risk cases such as those involving obesity^{13,14} or stoma creation¹⁵.

This retrospective study was conducted to assess the incidence of incisional SSI and other wound complications when wound closure was achieved by subcuticular suturing and closed suction drainage after stoma reversal.

Correspondence to Masano Sagawa, PhD, Department of Surgery, Tokyo Women's Medical University, Medical Center East, 2-1-10 Nishiogu Arakawa-ku, Tokyo 116-8567, Japan

E-mail: masanosagawa@yahoo.co.jp

Journal Website (<http://www2.nms.ac.jp/jnms/>)

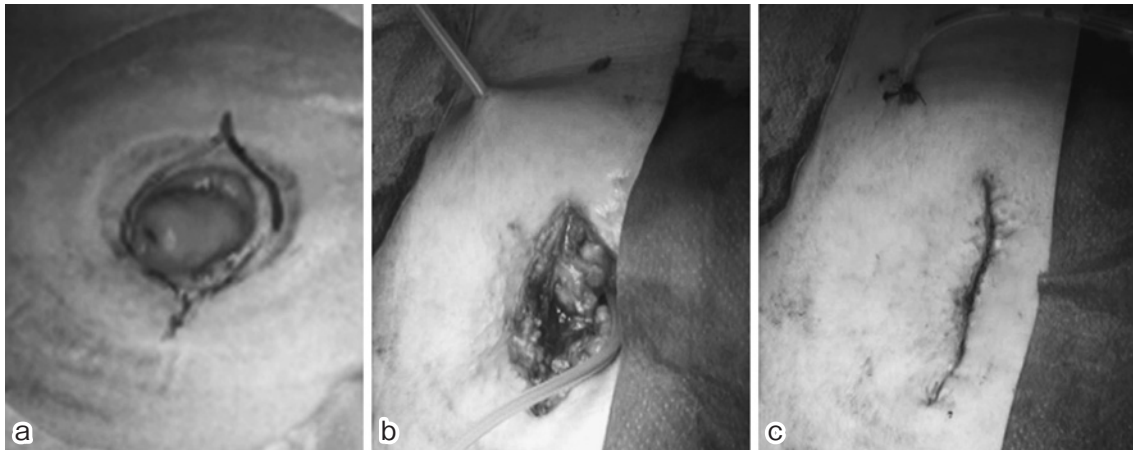


Fig. 1 A spindle-shaped skin marking was made before incision (a). After fascia closure, a 10 Fr closed suction drainage tube was placed on the fascia (b). Skin closure was done by subcuticular suturing (c), followed by film dressing.

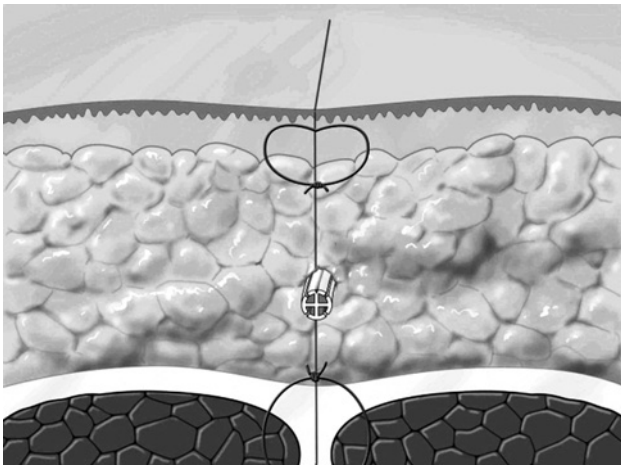


Fig. 2 A schematic of the procedure, used with permission from Ethicon.

Materials and Methods

Patients

We analyzed data from 49 patients who had undergone a stoma reversal operation prior to December 2014. All patients underwent the procedure as described below with regard to wound closure at the stoma site.

Wound Closure Procedure at the Stoma Site and Wound Management

A spindle-shaped skin marking was made before the incision (Fig. 1a). The stoma was closed tightly using inversion sutures on the intestinal mucosa, after which a spindle-shaped skin incision was made. Laparotomy was performed once the fascia was exposed through the intestine. After completely dividing the intestine from the abdominal wall, extra- or intra-corporeal reconstruction was performed. The abdominal fascia was closed by interrupted suturing, using a gradually absorbable mon-

ofilament suture (PDS II R, Johnson & Johnson). Following irrigation with approximately 300 mL of physiological saline, a 10 Fr closed suction drainage tube (J-VAC drainage system, Johnson & Johnson) was placed on the fascia (Fig. 1b). Skin closure was achieved by interrupted subcuticular suturing with 4-0 monofilament absorbable sutures (PDS II R Johnson & Johnson), followed by a film dressing (Fig. 1c).

Schematic of Procedure

The procedure is illustrated in Figure 2. Subcuticular sutures were made at 1 cm intervals. The film dressing was removed on postoperative day 2. The wound was monitored every day and the subcutaneous drain was removed by postoperative day 5.

Results

Patient Characteristics

The median age of our patient population (34 men and 15 women) was 68 (range, 35–84) years. Six patients with diabetes mellitus and twenty smokers were included in the patient population. With regard to the ASA category, ASA 1, 2, and 3 comprised 14, 32, and 3 patients, respectively. Six patients had end stomas and 43 had loop stomas. Stomas were in the small intestine for 28 patients and in the colon for 21 patients. A loop stoma closure was performed in 30 patients, including 2 patients who underwent synchronous hepatic resection and 1 with a cholecystectomy. Sixteen patients underwent curative colorectal cancer resection, including synchronous liver resection. Reconstruction after a Hartmann's procedure was performed in 3 patients. The mean operating time was 159 minutes (range, 52–491 minutes). Thirty-one patients were classified with a wound category of 'clean contami-

nated'(CC) and 18 with 'contaminated'(con). Risk indices were 0, 1, and 2 for 19, 25, and 5 patients, respectively.

Wound Complications

Incisional SSI was observed in one patient (2.0%) with ileostomy takedown created for diversion of low anterior resection. No wound disruption, seroma, or infection of the drain was noted. Primary healing was achieved in most cases, with the exception of the one incisional SSI case.

Discussion

Primary subcuticular suturing was performed with closed suction drainage, because a low incidence of incisional SSI has been noted in patients who undergo this type of skin closure with stoma creation¹⁷. Although our single-arm retrospective analysis may have skewed our data somewhat, the incidence of incisional SSI was only 2.0% in our study population. Our procedure used closed suction drainage, whereas Kobayashi et al. reported an incisional SSI incidence of 11.1% in their patients who underwent subcuticular suturing without closed suction drainage for closure of a diverting stoma¹². SSI was observed in one patient with an ileostomy takedown created for diversion of a low anterior resection; the wound class of this case was class III (contaminated). Since subcuticular suturing can approximate the dermis tightly, the conditions for wound healing are maintained through the blood supply and collagen formation from the reconstructed dermis^{16,17}. Additionally, closed suction drainage can provide adequate approximation of subcutaneous adipose tissue without dead space, avoiding the deposit of blood and serous discharge (Fig. 2). For the approximation of subcutaneous adipose tissue, suturing is not adequate as it can easily cause tissue necrosis through ischemia, potentially creating major obstacles for wound healing. Accordingly, subcutaneous suturing with closed suction drainage that can discharge the infectious source may be the best procedure to promote wound healing, even though the wound may increase the risk for incisional SSI.

The authors of a recent retrospective study reported on the use of subcuticular purse-string suturing following stoma takedown⁸. Although it is unclear whether this procedure can promote primary wound healing, the reported incidence of incisional SSI was 0%, as opposed to the 23% noted for primary closure. Moreover, a meta-analysis of purse-string suturing for stoma reversal found that, while the quality of supporting evidence is limited, this type of suturing is the best skin closure tech-

nique following stoma reversal, specifically with regard to SSI rates¹⁸. Indeed, although the length of the wound in our case was long, healing was relatively quick due to primary healing without SSI.

Several study limitations should be noted. First, this study was a single-arm, single-center retrospective study, and thus comprised a relatively small number of patients. Further investigation into this procedure will require a randomized trial design. In addition, we know very little about other complications such as incisional hernia or the medical costs involved in this procedure. A comprehensive study is required to further examine these potentially relevant issues.

References

1. Mangram AJ, Horan TC, Pearson ML, Silver LC, Jarvis WR: Guideline for prevention of surgical site infection, 1999: Hospital Infection Control Practices Advisory Committee. *Infect Control Hosp Epidemiol* 1999; 20: 250-278; quiz 279-280.
2. Weiss CA 3rd, Statz CL, Dahms RA, Remucal MJ, Dunn DL, Beilman GJ: Six years of surgical wound infection surveillance at a tertiary care center: review of the microbiologic and epidemiological aspects of 20,007 wounds. *Arch Surg* 1999; 134: 1041-1048.
3. Konishi T, Watanabe T, Kishimoto J, Nagawa H: Elective colon and rectal surgery differ in risk factors for wound infection: results of prospective surveillance. *Ann Surg* 2006; 244: 758-763.
4. Cruse PJ, Foord R: The epidemiology of wound infection: a 10-year prospective study of 62,939 wounds. *Surg Clin North Am* 1980; 60: 27-40.
5. Lahat G, Tulchinsky H, Goldman G, Klauzner JM, Rabau M: Wound infection after ileostomy closure: a prospective randomized study comparing primary vs. delayed primary closure techniques. *Tech Coloproctol* 2005; 9: 206-208.
6. Li LT, Hicks SC, Davila JA, Kao LS, Berger RL, Arita NA, Liang MK: Circular closure is associated with the lowest rate of surgical site infection following stoma reversal: a systematic review and multiple treatment meta-analysis. *Colorectal Dis* 2014; 16: 406-416.
7. Li LT, Brahmabhatt R, Hicks SC, Davila JA, Berger DH, Liang MK: Wound infection following stoma takedown: primary skin closure versus subcuticular purse-string suture. *Dig Surg* 2014; 31: 73-78.
8. Marquez TT, Christoforidis D, Abraham A, Madoff RD, Rothenberger DA: Prevalence of surgical site infection at the stoma site following four skin closure techniques: a retrospective cohort study. *World J Surg* 2010; 34: 2877-2882.
9. Reid K, Pockney P, Pollitt T, Draganic B, Smith SR: Randomized clinical trial of short-term outcomes following purse-string versus conventional closure of ileostomy wounds. *Br J Surg* 2010; 97: 1511-1517.
10. Bozzetti F, Nava M, Bufalino R, Menotti V, Marolda R, Doci R, Gennari L: Early local complications following colostomy closure in cancer patients. *Dis Colon Rectum* 1983; 26: 25-29.
11. Cruse PJ, Foord R: The epidemiology of wound infection: a 10-year prospective study of 62,939 wounds. *Surg Clin North Am* 1980; 60: 27-40.

12. Kobayashi S, Ito M, Sugito M, Kobayashi A, Nishizawa Y, Saito N: Association between incisional surgical site infection and the type of skin closure after stoma closure. *Surg Today* 2011; 41: 941-945.
13. Inotsume-Kojima Y, Uchida T, Abe M, Doi T, Kanayama N: A combination of subcuticular sutures and a drain for skin closure reduces wound complications in obese women undergoing surgery using vertical incisions. *J Hosp Infec* 2011; 77: 162-165.
14. Fujii T, Tabe Y, Yajima R, Yamaguchi S, Tsutsumi S, Asao T, Kuwano H: Effects of subcutaneous drain for the prevention of incisional SSI in high-risk patients undergoing colorectal surgery. *Int J Colorectal Dis* 2011; 26: 1151-1155.
15. Yoshimatsu K, Yokomizo H, Matsumoto A, Yano Y, Nakayama M, Okayama S, Shiozawa S, Shimakawa T, Katsube T, Naritaka Y: Liquid tissue adhesive, subcuticular suture and subcutaneous closed suction drain for wound closure as measures for wound infection in a colorectal cancer surgery with stoma creation. *Hepatogastroenterology* 2014; 61: 363-366.
16. Singer AJ, Clark RA: Cutaneous wound healing. *N Engl J Med* 1999; 341: 738-746.
17. Li J, Chen J, Kirsner R: Pathophysiology of acute wound healing. *Clin Dermatol* 2007; 25: 9-18.
18. McCartan DP, Burke JP, Walsh SR, Coffey JC: Purse-string approximation is superior to primary skin closure following stoma reversal: a systematic review and meta-analysis. *Tech Coloproctol* 2013; 17: 345-351.

(Received, September 11, 2017)

(Accepted, February 5, 2018)