

Small Cell Lung Cancer with Sarcoidosis in Spontaneous Remission: A Case Report

Yumeka Sasaki¹, Yasuhiko Koga¹, Norimitsu Kasahara¹, Yoshimasa Hachisu¹, Keisuke Murata¹, Hiroaki Tsurumaki¹, Masakiyo Yatomi¹, Yusuke Tsukagoshi¹, Yuri Sawada¹, Reiko Sakurai², Akihiro Ono¹, Noriaki Sunaga¹, Kyoichi Kaira³, Junko Hirato⁴, Toshitaka Maeno¹, Kunio Dobashi⁵ and Takeshi Hisada¹

¹Department of Allergy and Respiratory Medicine, Gunma University Graduate School of Medicine, Gunma, Japan

²Oncology Center, Gunma University Graduate School of Medicine, Gunma, Japan

³Department of Oncology Clinical Development, Gunma University Graduate School of Medicine, Gunma, Japan

⁴Department of Pathology, Gunma University Hospital, Gunma, Japan

⁵Gunma University Graduate School of Health Sciences, Gunma, Japan

A 69-year-old woman was diagnosed with sarcoidosis, which was not treated with corticosteroid therapy. Her levels of angiotensin converting enzyme decreased significantly over 4 years and a mass lesion was detected near the lower part of her left main bronchus, and diagnosed as small cell lung cancer (SCLC). Treatment of the SCLC with a series of chemotherapeutic agents produced excellent results. The pulmonary sarcoidosis did not show any deterioration despite the frequent use of amrubicin, which is known to be a cause of interstitial pneumonia. This is a case report of SCLC complicated with sarcoidosis in a stage of spontaneous remission, possibly suggesting an association between sarcoidosis and tumor immunity, since recent reports have suggested that immune checkpoint inhibitors might be involved in the development of sarcoidosis. (J Nippon Med Sch 2018; 85: 291–296)

Key words: sarcoidosis, small cell lung cancer, checkpoint inhibitor, ipilimumab, amrubicin

Introduction

Sarcoidosis is a disease of unknown cause characterized by the formation of non-caseating epithelioid cell granulomas in all organs of the body. The relationship between sarcoidosis and the development of cancer has been discussed for many years, but remains unclear. Steinfort *et al.* reported that the presence of sarcoid reactions in the regional lymph nodes in lung cancer resulted in a better prognosis¹. In recent years, numerous cases have been reported in which patients with cancer treated with immune checkpoint inhibitors developed sarcoidosis, suggesting that sarcoidosis might be linked to tumor immunity^{2–9}. Herein, we report a case of small cell lung cancer (SCLC) complicated with sarcoidosis during a stage of spontaneous remission that demonstrated a remarkable positive response to chemotherapy.

Case Report

In 2012, a 69-year-old woman was referred to our hospital due to bilateral hilar lymphadenopathy (BHL) with widespread reticular shadows in both lung fields, as observed on an annual chest X-ray examination (**Fig. 1a**). A chest computed tomography (CT) scan demonstrated BHL with a classical peri-lymphatic distribution of small nodules. She had a history of smoking 15 cigarettes a day for 35 years. She had elevated serum angiotensin converting enzyme (ACE), lysozyme, and γ -globulin levels: 56.4 IU/L (normal range: 8.3–21.4 IU/L), 22.2 μ g/mL (normal range: 5.0–10.0 μ g/mL), and 26.6% (normal range: 10.7–20.3%), respectively. Bronchoalveolar lavage fluid examination revealed the proportion of lymphocytes to be elevated (lymphocytes 32%; neutrophils 2%; macrophages 66%), and a CD4 to CD8 T lymphocyte ratio of 6.54 (CD4 83.7%; CD8 12.8%). Histological examination of the transbronchial lung biopsy at the right up-

Correspondence to Yasuhiko Koga, Department of Allergy and Respiratory Medicine, Gunma University Graduate School of Medicine, 3–39–15 Showa-machi, Maebashi, Gunma 371–8511, Japan

E-mail: ykoga@gunma-u.ac.jp

Journal Website (<http://www2.nms.ac.jp/jnms/>)

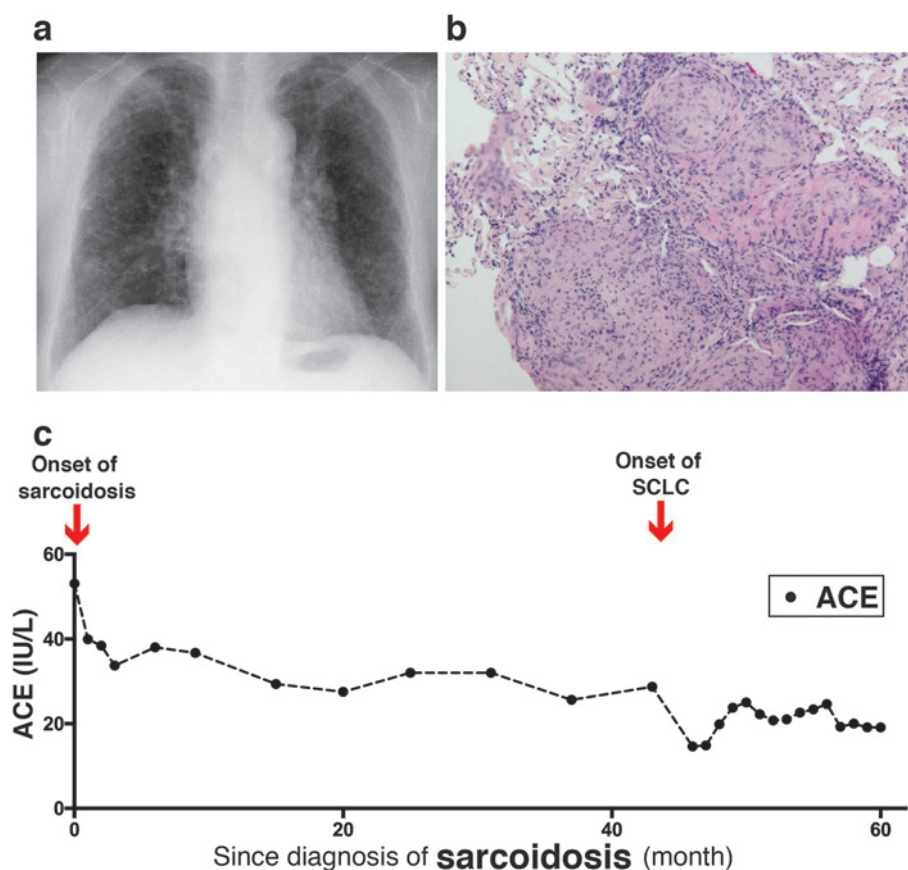


Fig. 1 Pulmonary sarcoidosis at initial diagnosis and its natural remission.

a. Chest X-ray image showing reticular shadows in both lung fields and bilateral hilar lymphadenopathy. b. Histological preparation showing non-caseating epithelioid cell granulomas containing giant cells in the lung biopsy. c. Decrease in serum angiotensin converting enzyme levels without corticosteroid therapy during the first 4 years after the initial diagnosis of sarcoidosis.

per lobe (B3) revealed non-caseating epithelioid cell granulomas containing giant cells (Fig. 1b); thus, she was diagnosed with sarcoidosis. The patient was followed-up for 4 years without oral corticosteroid therapy for pulmonary sarcoidosis but with local treatment for eye and skin lesions due to sarcoidosis. The serum ACE levels gradually decreased from 54.6 to 25.6 IU/L (Fig. 1c), even though she did not take any ACE inhibitors.

In 2016, a CT examination revealed a mass lesion in the lower part of her left main bronchus. Furthermore, an ^{18}F -fluorodeoxyglucose (FDG) positron-emission tomography (PET) scan showed intense FDG activity in the bronchus of the left lower lobe (maximum standardized uptake value, 8.49) (Fig. 2a), in the lymph node just above the cardia, and on the right side of the upper abdominal aorta. The patient's serum neuron-specific enolase (NSE) and pro-gastrin releasing peptide (pro-GRP) levels were elevated to 19.1 ng/mL (normal range: 0–12 ng/mL) and 6,220 pg/mL (normal range: 0–80 pg/mL), respectively.

Histological examination of the bronchoscopic biopsy specimen obtained from the left main bronchus showed proliferation of small cells with a high nucleus-cytoplasm ratio that were positive for CD56 and synaptophysin (Fig. 2b). On the basis of these findings, the patient was diagnosed with extensive-stage SCLC with abdominal lymph node metastasis (T2bN3M1c) in a stage of spontaneous remission from sarcoidosis (Fig. 1c). The mass around the bronchus of the left lower lobe and the lymph node metastases were dramatically reduced after four courses of chemotherapy consisting of intravenous administration of cisplatin and etoposide, and showed almost complete response. The NSE and pro-GRP levels were also normalized. Thereafter, the patient was given amrubicin monthly due to refractory relapse of SCLC and was maintained under complete response for more than 1 year (Fig. 3a and b). The pulmonary sarcoidosis was found to be similar before and after the chemotherapeutic treatment. It should be noted that amrubicin had

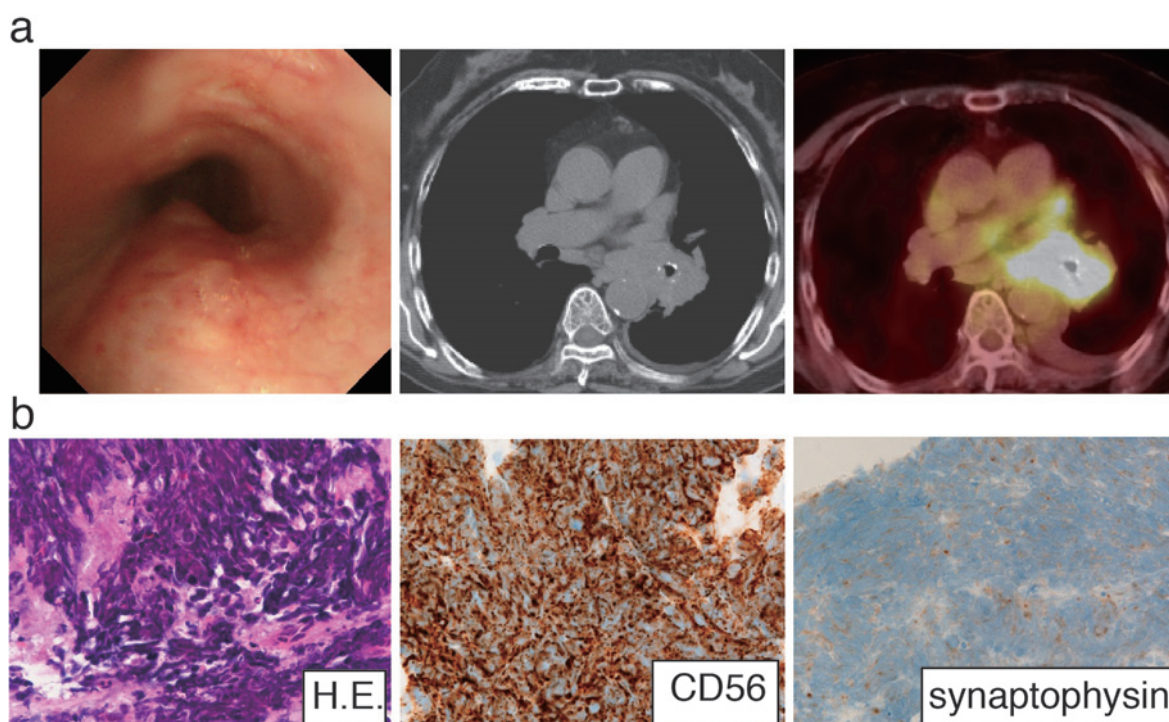


Fig. 2 Diagnosis of small cell lung cancer in a stage of spontaneous remission of sarcoidosis
 a. Observation of swelling bronchial mucosa in the left main bronchus by bronchoscopy (left). Appearance of a mass lesion around the lower part of the left main bronchus by computed tomography examination (middle), and the accumulation of ^{18}F -fluorodeoxyglucose (FDG) in the mass lesion (standardized uptake value max 8.49) visualized by FDG-positron emission tomography (right).
 b. Histological preparation of the bronchoscopic biopsy specimen taken from the left main bronchus showing proliferation of small cells with a high nuclear-cytoplasm ratio (left) that are positive for CD56 (middle) and synaptophysin (right).

no effect on either pulmonary sarcoidosis or fibrotic markers during the chemotherapy (Fig. 4a and b).

Discussion

The association of sarcoidosis with malignant tumors has been debated for many years. Recently, a meta-analysis found that the relative risk of lung cancer increases within 4 years after the diagnosis of sarcoidosis¹⁰, which is similar to that observed in our case. Seven cases of concomitant occurrence of sarcoidosis and SCLC have been reported (Table 1)¹¹⁻¹⁷. The onset of SCLC occurred within 2 to 12 years after the diagnosis of sarcoidosis. There were four cases of development of cancer within 4 years after the diagnosis of sarcoidosis, including our case, and four cases of later development. The median duration between the diagnosis of sarcoidosis and subsequent occurrence of SCLC was 5.6 years and the mean serum ACE level was 19.7 (IU/L), which is within normal limits. Interestingly, Hatakeyama *et al.* reported a case of a patient with spontaneous remission of sarcoidosis who was diagnosed with SCLC 2 years later, with reduction in serum ACE levels from >40.0 to 20.8 IU/L¹¹.

Decreased sarcoidosis activity, such as shrinkage of BHL or disappearance of non-caseating granulomas on autopsy, was shown in 4 of 7 cases (Table 1). The other 3 cases either underwent corticosteroid treatment or showed onset of sarcoidosis and SCLC at the same time. Ogata *et al.* reported 6 cases of primary lung cancer complicated with sarcoidosis and found normal serum ACE levels in all cases, indicating decreased activity of sarcoidosis¹⁴. Kamei *et al.* discussed the relationship between sarcoidosis activity and the occurrence of lung cancer¹².

In recent years, several reports have been published regarding the relationship between sarcoidosis and immune checkpoint inhibitors²⁻⁹. Suozzi *et al.* reported a case of sarcoidosis developing in a patient with lung adenocarcinoma managed with ipilimumab and nivolumab immunotherapy⁹. Ipilimumab and nivolumab are immune checkpoint inhibitors that exert anti-tumor effects by activating tumor immunity. Suozzi *et al.* also reported on 11 patients who developed sarcoidosis associated with immune checkpoint inhibitor therapy for cancer treatment. Sarcoidosis is a disease of unidentified cause, but it has been established that its pathogenesis involves abnor-

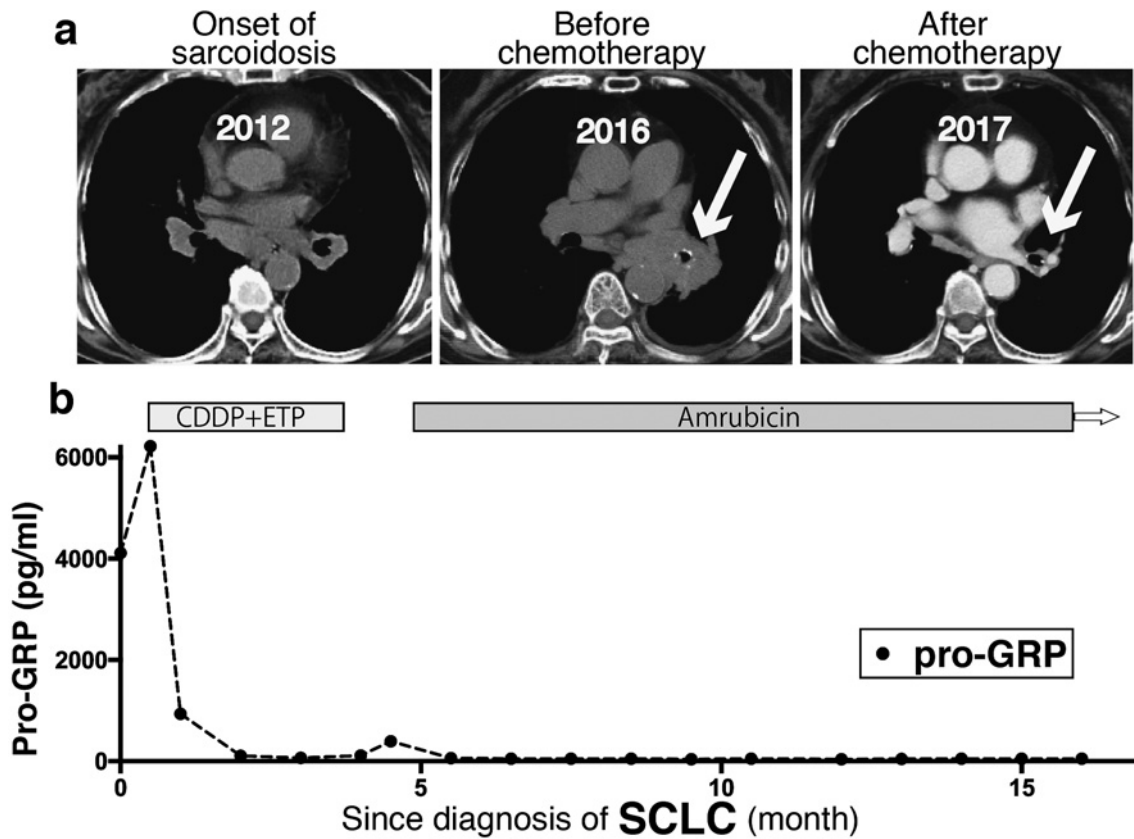


Fig. 3 Effect of chemotherapy on small cell lung cancer.

a. A combination of cisplatin and etoposide and amrubicin monotherapy produced a nearly complete response of the mass lesion around the lower part of the left bronchus.

b. Decrease of pro-gastrin releasing peptide levels after treatment with cisplatin and etoposide and amrubicin.

malities in cellular immunity^{18,19}. It can be reasoned that if the inhibition of immune checkpoints results in sarcoidosis, sarcoidosis may be involved in tumor immunity. In accordance with this idea, Steinfert *et al.* reported that the presence of sarcoid reactions within regional lymph nodes of lung cancer is associated with a lower rate of disease recurrence after surgical resection. This result suggests that a sarcoid reaction in lung cancer may indicate anti-tumor activity such as tumor immunity¹. In our case, the sarcoidosis resolved through its natural course and did not deteriorate during the treatment of SCLC. It is important to note that the involvement of SCLC was confirmed in a stage of spontaneous remission of sarcoidosis in our case. This report may also suggest the possibility that the occurrence of a malignant tumor is partly a result of reduced sarcoid activity, reflecting a role of an immune mechanism such as tumor immunity in the natural remission process of sarcoidosis. It is interesting that ACE, besides serving as a marker for disease activity, may be involved in T lymphocyte regulation. Angiotensin II has been reported to be chemotactic for T lymphocytes²⁰, and regulatory T cells suppressing tumor

immunity are decreased in the serum and BALF of patients with sarcoidosis^{21,22}, while regulatory T cells are known to accumulate in the tumor to suppress tumor immunity²³. However, further studies of the natural history of sarcoidosis complicated with malignant tumors are required to elucidate the mechanism underlying the association between sarcoidosis and cancer.

It is also important to note that although amrubicin is not generally recommended for treatment of lung cancer with interstitial pneumonia, as it may exacerbate the pneumonia²⁴, its safety in cases of pulmonary sarcoidosis has not been evaluated yet. In our case, monthly amrubicin therapy lasting for more than 1 year did not affect serum fibrotic markers and pulmonary sarcoidosis, suggesting that amrubicin might be tolerable for fibrotic inflammation caused by sarcoidosis. It is interesting that both first-line and second-line chemotherapy showed remarkable effects against SCLC during the natural remission stage of sarcoidosis for over 18 months.

In conclusion, we described a case of SCLC complicated with sarcoidosis in a stage of spontaneous remission. It may be necessary to follow up patients with sar-

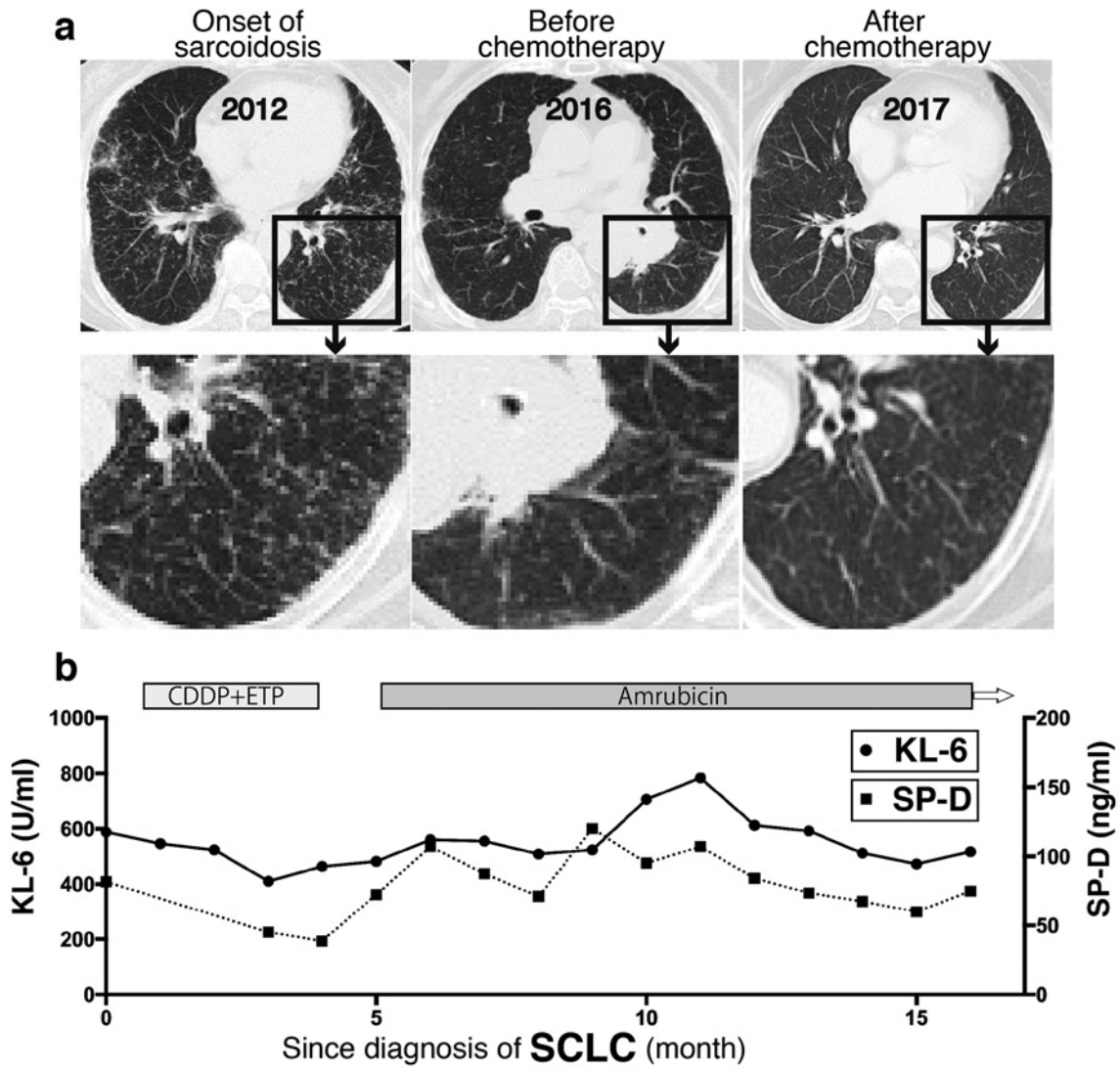


Fig. 4 Effect of chemotherapy on pulmonary sarcoidosis (a) and fibrotic markers (b).

a. Computed tomography (CT) scans at the initial visit, before and after chemotherapy. A chest CT showing bilateral hilar lymphadenopathy with widespread reticular shadows in both lung fields on initial admission to our hospital (left), which had been in remission before chemotherapy (middle), and did not deteriorate during chemotherapy (right).

b. No changes was noted in the levels of fibrotic markers, Krebs von den Lungen-6 (KL-6) and surfactant protein D (SP-D), during the chemotherapy.

Table 1

Author	ACE (IU/L) at sarcoidosis diagnosis	ACE (IU/L) at SCLC diagnosis	Sex	Age (years)	Pulmonary lesions of sarcoidosis	Since sarcoidosis to SCLC
Sinokawa et al.	N.D.	N.D.	F	62	BHL Lung	8 years
Kamei et al.	N.D.	14.6	M	61	BHL	10 years
Hatakeyama et al.	>40.0	20.8	M	62	BHL Lung	2 years
Ueno et al.	N.D.	24	M	59	BHL	9 years
Tokuyasu et al.	N.D.	27.4	M	69	BHL Lung	simultaneous
Ogata et al.	N.D.	9.2	M	56	BHL	simultaneous
Kurosaki et al.	N.D.	13.2	M	55	BHL Lung	12 years
This case	56.4	25.6	F	69	BHL Lung	4 years

coidosis over the course of spontaneous remission for the possibility of carcinogenesis, especially those with a history of smoking.

Conflict of Interest: No authors have any conflicts of interest to declare in association with this study.

References

- Steinfort DP, Tsui A, Grieve J, Hibbs ML, Anderson GP, Irving LB: Sarcoidal reactions in regional lymph nodes of patients with early stage non-small cell lung cancer predict improved disease-free survival: a pilot case-control study. *Human pathology* 2012; 43: 333-338.
- Abdel-Wahab N, Shah M, Suarez-Almazor ME: Adverse Events Associated with Immune Checkpoint Blockade in Patients with Cancer: A Systematic Review of Case Reports. *PloS one* 2016; 11: e0160221.
- Bertrand A, Kostine M, Barneze T, Truchetet ME, Schaefferbeke T: Immune related adverse events associated with anti-CTLA-4 antibodies: systematic review and meta-analysis. *BMC medicine* 2015; 13: 211.
- Cousin S, Toulmonde M, Kind M, Cazeau AL, Bechade D, Coindre JM, Italiano A: Pulmonary sarcoidosis induced by the anti-PD1 monoclonal antibody pembrolizumab. *Annals of oncology: official journal of the European Society for Medical Oncology* 2016; 27: 1178-1179.
- Danlos FX, Pages C, Baroudjian B, Vercellino L, Battistella M, Mimoun M, Jebali M, Bagot M, Tazi A, Lebbe C: Nivolumab-Induced Sarcoid-Like Granulomatous Reaction in a Patient With Advanced Melanoma. *Chest* 2016; 149: e133-e136.
- Firwana B, Ravilla R, Raval M, Hutchins L, Mahmoud F: Sarcoidosis-like syndrome and lymphadenopathy due to checkpoint inhibitors. *Journal of oncology pharmacy practice: official publication of the International Society of Oncology Pharmacy Practitioners* 2017; 23: 620-624.
- Montaudie H, Pradelli J, Passeron T, Lacour JP, Leroy S: Pulmonary sarcoid-like granulomatosis induced by nivolumab. *The British journal of dermatology* 2017; 176: 1060-1063.
- Reuss JE, Kunk PR, Stowman AM, Gru AA, Slingluff CL Jr, Gaughan EM: Sarcoidosis in the setting of combination ipilimumab and nivolumab immunotherapy: a case report & review of the literature. *Journal for immunotherapy of cancer* 2016; 4: 94.
- Suozzi KC, Stahl M, Ko CJ, Chiang A, Gettinger SN, Siegel MD, Bunick CG: Immune-related sarcoidosis observed in combination ipilimumab and nivolumab therapy. *JAAD case reports* 2016; 2: 264-268.
- Bonifazi M, Bravi F, Gasparini S, La Vecchia C, Gabrielli A, Wells AU, Renzoni EA: Sarcoidosis and cancer risk: systematic review and meta-analysis of observational studies. *Chest* 2015; 147: 778-791.
- Hatakeyama S, Tachibana A, Uchiyama H, Suzuki K, Nagayama M, Okano H, Oka T: [A case of small cell lung cancer occurring in a patient with pulmonary sarcoidosis]. *Nihon Kyobu Shikkan Gakkai zasshi* 1992; 30: 1963-1968.
- Kamei T, Ogushi F, Sone S, Ozaki T, Yasuoka S, Ogura T, Sano N: [A case of small cell lung cancer associated with pulmonary sarcoidosis]. *Nihon Kyobu Shikkan Gakkai zasshi* 1991; 29: 1305-1310.
- Kurosaki F, Bando M, Nakayama M: A patient with sarcoidosis who developed non-Hodgkin's lymphoma and small cell lung cancer. *Annals of the Japanese Respiratory Society* 2012; 1: 520-525.
- Ogata S, Maeyama T, Hamada N: Clinical features of six cases of primary lung cancer with sarcoidosis. *Annals of the Japanese Respiratory Society* 2012; 1: 95-101.
- Sasagawa M, Tawaraya K, Nagai A: A Case of Small Cell Lung Cancer Associated with Pulmonary Sarcoidosis. *Japanese Journal of Lung Cancer* 1987; 27: 301-306.
- Tokuyasu H, Izumi H, Mukai N, Takeda K, Sakaguchi Y, Isowa N, Shimizu E: Small cell lung cancer complicated by pulmonary sarcoidosis. *Internal medicine (Tokyo, Japan)* 2010; 49: 1997-2001.
- Ueno M, Motegi M, Hara K: A Case of Small Cell Lung Cancer Occuring in a Patient with Pulmonary Sarcoidosis. *The Japanese Journal of Thoracic Diseases* 2007; 66: 774-782.
- Katchar K, Soderstrom K, Wahlstrom J, Eklund A, Grunewald J: Characterisation of natural killer cells and CD56+ T-cells in sarcoidosis patients. *The European respiratory journal* 2005; 26: 77-85.
- Miyara M, Amoura Z, Parizot C, Badoual C, Dorgham K, Trad S, Kambouchner M, Valeyre D, Chapelon-Abrie C, Debre P, Piette JC, Gorochoff G: The immune paradox of sarcoidosis and regulatory T cells. *The Journal of experimental medicine* 2006; 203: 359-370.
- Weinstock JV, Blum AM, Kassab JT: Angiotensin II is chemotactic for a T-cell subset which can express migration inhibition factor activity in murine schistosomiasis mansoni. *Cellular immunology* 1987; 107: 180-187.
- Idali F, Wahlstrom J, Muller-Suur C, Eklund A, Grunewald J: Analysis of regulatory T cell associated forkhead box P3 expression in the lungs of patients with sarcoidosis. *Clinical and experimental immunology* 2008; 152: 127-137.
- Huang H, Lu Z, Jiang C, Liu J, Wang Y, Xu Z: Imbalance between Th17 and regulatory T-Cells in sarcoidosis. *International journal of molecular sciences* 2013; 14: 21463-21473.
- Nishikawa H, Sakaguchi S: Regulatory T cells in cancer immunotherapy. *Current opinion in immunology* 2014; 27: 1-7.
- Yoh K, Kenmotsu H, Yamaguchi Y, Kubota K, Ohmatsu H, Goto K, Niho S, Ohe Y, Saijo N, Nishiwaki Y: Severe interstitial lung disease associated with amrubicin treatment. *Journal of thoracic oncology : official publication of the International Association for the Study of Lung Cancer* 2010; 5: 1435-1438.

(Received, February 18, 2018)

(Accepted, May 27, 2018)