

## Diagnostic Value of Plain Radiography for Symptomatic Bone Metastasis at the First Visit

Yasuyuki Kitagawa, Takashi Yamaoka, Mari Yokouchi,  
Toshihiko Ito, Yoshihiro Mizuno, Yoshihiro Sudo,  
Yong Kim, Ryu Tsunoda and Shinro Takai

Department of Orthopaedic Surgery, Nippon Medical School, Tokyo, Japan

**Background:** To prevent and minimize skeletal-related diseases, early diagnosis of bone metastases is important. However, previous reports have shown that plain radiography has low sensitivity and fails to screen multiple asymptomatic lesions. Limited investigations have been reported on the value of plain radiography in the diagnosis of symptomatic bone metastases. Therefore, this study aimed to investigate the diagnostic utility of plain radiography for symptomatic bone metastasis.

**Methods:** Two experienced orthopedic surgeons retrospectively evaluated the plain radiographs of 39 patients with symptoms during their first visit between 2011 and 2014 for bone metastases. Another 2 experienced orthopedic surgeons then reviewed the data using 2 reference standards, the clinical results and the retrospectively evaluated results, in a blinded manner. The data were then reviewed by 2 certified orthopedic surgeons and 7 orthopedic surgeons in training with differing years of experience in a blinded manner.

**Results:** The overall sensitivity of diagnosis of symptomatic bone metastasis using plain radiography at the clinic first visit was 71.4%. Upon blinded evaluation, the accuracy, sensitivity, and specificity were 55.8%, 54.3%, and 68.8% and 77.6%, 73.0%, and 85.7% for clinical results and results from 2 experienced orthopedic surgeons as a reference standard, retrospectively. There was a strong and significant correlation between the accuracy and observers' years of experience in orthopedic surgery among the orthopedic surgeons in training ( $R=0.942$ ,  $p=0.0015$ ).

**Conclusions:** Plain radiography around the time of the first visit has a definitive role in the early diagnosis of symptomatic bone metastasis. (J Nippon Med Sch 2018; 85: 315–321)

**Key words:** bone metastasis, X-ray, plain radiography, diagnosis, first visit

### Introduction

In Japan, the number of elderly people aged 65 years or older continues to increase, and accordingly, the number of patients with cancer also continues to increase<sup>1</sup>. Among patients with either breast or prostate cancer, 70% develop bone metastases, and 25% of patients with breast cancer develop pathological fractures<sup>2</sup>. To prevent and minimize skeletal-related diseases, early diagnosis of bone metastases is important. However, in practice, it is difficult to diagnose bone metastases early on the basis of the clinical course and physical findings, probably because the age of onset and initial symptoms are fre-

quently similar to those in multiple common orthopedic diseases, such as degenerative spinal diseases.

In Japan, most patients with pain in the extremities or spinal column directly visit an orthopedic practitioner in an independent clinic or a hospital-based clinic. In such orthopedic clinics, plain radiography is usually performed at the first visit. In general, the sensitivity of diagnosis of bone metastasis using only plain radiography is very low, at around 30%, which is considered to be unsuitable for early diagnosis<sup>3</sup>. However, most previous reports on the diagnostic ability of an imaging study for bone metastasis are based upon screening of bone metas-

Correspondence to Yasuyuki Kitagawa, MD, Department of Orthopaedic Surgery, Nippon Medical School, 1-1-5 Sendagi, Bunkyo-ku, Tokyo 113-8603, Japan

E-mail: kitayasu@nms.ac.jp

Journal Website (<http://www2.nms.ac.jp/jnms/>)

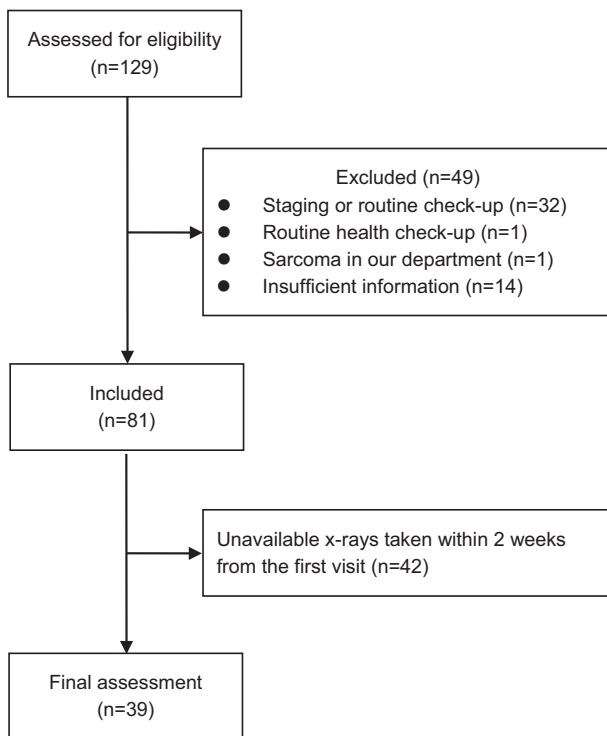


Fig. 1 Flowchart for enrolment.

tasis including multiple asymptomatic lesions, whereas limited investigations have focused on imaging diagnosis limited to only symptomatic bone metastases.

Symptomatic bone metastatic lesions are usually more advanced than lesions diagnosed by screening in most patients. Accordingly, they are presumed to be more easily diagnosed by plain radiography than asymptomatic bone metastases. The hypothesis of this research was that plain radiography can be useful for the diagnosis of symptomatic bone metastasis. To support this, we performed a retrospective, blinded evaluation of plain radiographs obtained during the first clinical visit.

### Materials and Methods

This retrospective study was approved by our institutional review board and was conducted in accordance with the Declaration of Helsinki. This study was conducted at the orthopedics department at a single university hospital. The plain radiography data for bone metastasis taken within 2 weeks of the first visit to any clinic were retrospectively evaluated by 2 experienced orthopedic surgeons for depiction of bone metastases. The data were then reviewed by another 2 experienced orthopedic surgeons in a blinded manner, followed by blinded review by 2 additional certified orthopedic surgeons and 7 orthopedic surgeons in training with differing years of orthopedic experience.

### Participants

The consecutive series of 129 patients were selected by retrospective review of our institutional database by searching records of all patients with bone metastasis (both in- and out-patients) who visited our department's clinic for symptoms related to first bone metastasis from January 2011 to December 2014. Of the 129 patients, 49 patients were excluded using the exclusion criteria described below. Of the remaining 81 patients, 42 patients were excluded, as the plain radiographs obtained within 2 weeks of their first visit to any clinic were not available. Finally, 39 patients were enrolled for this assessment (Fig. 1). Exclusion criteria included patients with bone metastasis diagnosed either by staging or a routine whole-body check-up after the diagnosis of a primary cancer without a prior visit to any clinic for bone metastasis, patients with bone metastasis diagnosed by a routine health check-up without a prior visit to any clinic for bone metastasis, patients with bone metastasis developed from sarcoma, who originally visited our department, and patients with insufficient clinical information for review. For this study, the first visit was defined as the first visit to any clinic with symptoms of bone metastasis.

The plain radiography data of the 39 patients, taken within 2 weeks of the first visit to any clinic were included. Of the 39 patients, 24 were men and 15 were women. The mean age was 70 years (range, 43–85 years). Demographic characteristics of patients are summarized in Table 1.

In case plain radiographs were taken at multiple time-points within 2 weeks from the first visit, those taken at or closest to the first visit were used. In general, 2 images of anterior-posterior and lateral views that contained the site of bone metastasis relating to the main symptoms were selected for evaluation. The plain radiographs did not contain the site of bone metastasis for 4 patients. These images were still included in the study, as selection of an appropriate imaging site is part of a clinician's ability. In addition, this data set was used as a negative control in blind tests. For these patients, radiographs obtained at sites closest to the site of bone metastasis were selected. The image data were in the JPEG format. The mean JPEG file pixel count was 2081.5 (range, 1,186–4,280) × 2382.1 (range, 1,440–4,280). The mean resolution and size of the monitors to display the data were 1,280 (range, 1,920 to 2,560) × 1,020 (range, 108 to 1,440) pixels and 22.3 inch (range, 13.3 to 28.5).

### Image Analysis

Part 1. In order to determine the diagnostic ability of

Table 1 Demographic and clinical characteristics of patients

Characteristics	Data
Mean age at first visit (range)	70.0 (43–85)
Sex	
Female	15 patients
Male	24 patients
Location	
Spine	21 lesions
Long bone	9 lesions
Pelvis	5 lesions
Without lesions	4 patients
Symptoms	
Pain	38 lesions
Pain and paralysis	1 lesion
Primary cancer (number of patients)	Lung (8), kidney (4), breast (4), stomach (4), prostate (3), others (16)

a) Plain radiography of 4 patients did not reveal any bone metastases (humeral, femoral, costal, and thoracic spinal lesions).

plain radiography around the time of the first visit, the images of 35 patients (excluding 4 patients with plain radiography that did not contain the site of bone metastasis) were classified as “bone metastasis or bone metastasis highly suspected,” or as others, after a retrospective evaluation by 2 experienced orthopedic surgeons who were aware of the metastasis lesion site. These 2 experienced orthopedic surgeons had 23.5 years and 22.5 years of experience as orthopedic surgeons. If the image was classified as “bone metastasis or bone metastasis highly suspected,” the type of bone metastasis (osteolytic type, osteoblastic type, or mixed type), the presence of a pathological fracture, and the presence of a pedicle sign in the case of the spine, were also assessed. These evaluations were performed independently, with consensus between the 2 surgeons after discussion.

Part 2. To determine the ability of clinicians to use plain radiography for diagnosis, the images of 39 patients were again classified into the same categories after a blind review by 2 experienced orthopedic surgeons who were only aware of the primary complaint. These 2 experienced orthopedic surgeons had 16.5 years and 8.5 years of experience as orthopedic surgeons. Upon evaluation as “bone metastasis or bone metastasis highly suspected,” the site of the lesion and the presence of a pedicle sign in the case of the spine were also evaluated. The evaluations were independently conducted in less than 3 minutes per patient. After 3 months, the images were blindly reviewed again by the same orthopedic surgeons to assess intra-observer reliability.

Part 3. To determine the relationships between the ability of clinicians to use plain radiography for diagnosis

and their clinical experience, the images were classified similarly as above by another 2 certified orthopedic surgeons and 7 orthopedic surgeons in training with differing clinical experience of orthopedic surgery. These 2 certified orthopedic surgeons had 12.5 and 16.5 years of experience, post-residency in orthopedic surgery. The 7 trainees included 2 medical doctors with 0.5 years, 1 medical doctor with 1.5 years, 2 medical doctors with 3.5 years, 1 medical doctor with 4.5 years, and 1 medical doctor with 6.5 years of experience post residency in orthopedic surgery. Statistical analysis was performed on data generated for 11 doctors (these 9 plus the 2 orthopedic surgeons identified in Part 2).

#### Statistical Analysis

Part 1. Diagnostic sensitivity of plain radiography around the first visit for symptomatic bone metastasis was calculated, and the results were used as a true reference standard for later blind evaluations, as described in Parts 2 and 3. Inter-observer agreement between the 2 experienced orthopedic surgeons was evaluated using Cohen’s kappa coefficient.

Part 2. Diagnostic accuracy, sensitivity, and specificity were calculated using 2 reference standards: 1) the actual clinical outcome on presence or absence of bone metastasis, and 2) the results obtained by the retrospective evaluations, as described in Part 1. In cases positive for bone metastasis, if the observer incorrectly identified the site of the lesion, it was regarded as an incorrect answer. Inter-observer and intra-observer agreements between the 2 experienced orthopedic surgeons were evaluated using Cohen’s kappa coefficient. A kappa value between 0.0–0.2 was graded as slight agreement, 0.21 to 0.4 as fair agree-

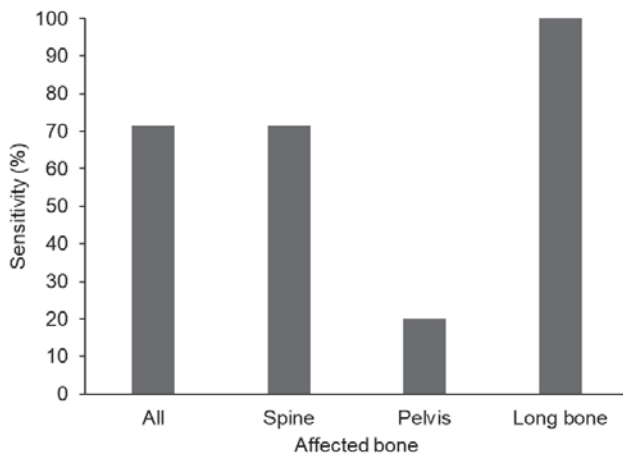


Fig. 2 Sensitivity of plain radiographs obtained around the time of the first visit for symptomatic bone metastasis obtained upon retrospective evaluation by surgeons who were aware of the patients' clinical information including the metastasis lesion site.

ment, 0.41 to 0.6 as moderate agreement, and 0.61 to 0.8 as substantial agreement, and 0.81 to 1.0 as almost perfect agreement<sup>45</sup>.

Part 3. Diagnostic accuracy was calculated using the results obtained by the retrospective evaluation in Part 1 as the reference standard. The relationship between diagnostic accuracy and observers' clinical experience in orthopedics was analyzed using Pearson's correlation coefficient.

A two-sided  $p$  value  $< 0.05$  was considered significant for Cohen's kappa coefficient and Pearson correlation coefficient. All statistical analyses were performed using Excel statistical software package: BellCurve for Excel, ver.2.15, 2017 (Social Survey Research Information Co., Ltd., Tokyo, Japan).

## Results

Part 1. The diagnostic sensitivity of plain radiography around the time of the first visit for symptomatic bone metastasis was obtained on the basis of a retrospective evaluation by 2 experienced orthopedic surgeons who were aware of the patients' clinical information including the metastasis lesion sites, as shown in **Figure 2**. The overall sensitivity was 71.4%, and the sensitivities for the long bone, spine, and pelvis were 100.0%, 71.4%, and 20.0%, respectively. The frequencies of characteristic plain radiography findings are shown in **Table 2**. The inter-observer agreement between the 2 experienced orthopedic surgeons described in Part 1 was moderate (kappa value, 0.44; 95% CI 0.14 to 0.75;  $p=0.0075$ ).

Part 2. Accuracy, sensitivity, and specificity of plain ra-

Table 2 Characteristic plain radiography findings upon retrospective evaluation

Findings	Frequency
Characteristics of diagnostic change (n=25)	
Osteolytic	84.0% (21/25)
Osteoblastic	8.0% (2/25)
Mixed	8.0% (2/25)
Spine (n=21)	
Pathological compression fracture	28.6% (6/21)
Pedicle sign	19.0% (4/21)
Long bone (n=9)	
Pathological fracture	77.8% (7/9)
Pelvis (n=5)	
Pathological fracture	20.0% (1/5)

diography for symptomatic bone metastasis around the first visit, upon blind review by another 2 experienced orthopedic surgeons who were only aware of the primary complaint are shown in **Table 3** and **Table 4**. The mean accuracy was 55.8%, sensitivity was 54.3% and specificity was 68.8%, compared to the actual presence or absence of bone metastasis as reference, and 77.6%, 73.0%, and 85.7%, respectively, compared to retrospective evaluation by 2 experienced orthopedic surgeons in Part 1 as reference. Inter-observer and intra-observer agreements between the 2 orthopedic surgeons are shown in **Table 5**. The inter-observer and intra-observer agreements were moderate to substantial. Diagnostic rates of bone metastasis for different locations are shown in **Table 6**. The clinicians' ability to diagnose using radiography was not high (mean accuracy: 69.1%) for spinal lesions, while it was very high (95.5%) for long bones. The sensitivity for detection of a pedicle sign was less than 50% (**Table 7**).

Part 3. There was a strong and significant correlation between diagnostic accuracy and the observers' years of experience in orthopedic surgery among trainees ( $R=0.942$ ,  $p=0.0015$ ). No correlation was found between accuracy and observers' years of experience among certified orthopedic surgeons ( $R=0.309$ ,  $p=0.691$ ) (**Fig. 3**).

## Discussion

The most important finding of this study was that the sensitivity of plain radiography around the time of the first visit for symptomatic bone metastasis was relatively high (71.4%) and the accuracy and sensitivity of blind evaluation of plain radiographs were over 50%. These findings were higher than the diagnostic results from screening of plain radiographs for bone metastasis that

Table 3 Diagnostic results of blind evaluation compared with actual results reporting the presence or absence of bone metastasis as a reference standard

	Accuracy	Sensitivity	Specificity
Observer 1 (1st time)	48.7%	51.4%	25.0%
Observer 1 (2nd time)	56.4%	51.4%	100.0%
Observer 2 (1st time)	64.1%	62.9%	75.0%
Observer 2 (2nd time)	53.8%	51.4%	75.0%
Mean	55.8%	54.3%	68.8%

Table 4 Diagnostic results of blind evaluation compared with results of retrospective evaluation (Part 1) as the reference

	Accuracy	Sensitivity	Specificity
Observer 1 (1st time)	74.4%	72.0%	78.6%
Observer 1 (2nd time)	76.9%	68.0%	92.9%
Observer 2 (1st time)	79.5%	80.0%	78.6%
Observer 2 (2nd time)	79.5%	72.0%	92.9%
Mean	77.6%	73.0%	85.7%

Table 5 Inter-observer and intra-observer agreements between 2 orthopedic surgeons

	$\kappa$ values	<i>p</i>	Grade
Intra-observer agreement			
Observer 1	0.49 (0.23–0.76)	0.0017	moderate
Observer 2	0.44 (0.17–0.71)	0.0046	moderate
Inter-observer agreement			
Observer 1 vs 2 (1st time)	0.63 (0.39–0.88)	<i>p</i> <0.001	substantial
Observer 1 vs 2 (2nd time)	0.54 (0.27–0.80)	<i>p</i> <0.001	moderate

a) Data given are kappa values with confidence intervals in brackets

Table 6 Diagnostic results of blind evaluation using results of retrospective evaluation (Part 1) as reference by location

	Accuracy	Sensitivity	Specificity
Spine (review: positive/all=15/21)	69.1%	60.0%	91.7%
Long bone (review: positive/all=9/9)	95.5%	97.2%	87.5%
Pelvis (review: positive/all=1/5)	85.0%	100.0%	93.8%

was not restricted to symptomatic bone metastasis, as reported previously.<sup>3</sup> This suggests that plain radiography has a definitive role in the diagnosis of symptomatic bone metastasis. To the best of our knowledge, there have been a few similar reports in the English language literature on plain radiography around the time of the first visit for first bone metastasis lesions with symptoms.

The low screening ability of plain radiography for bone metastasis is because of limited contrast in trabecular bone, overlap with bone, soft tissue and gas images,

and the difference of x-ray transparency between the chest and abdomen. Trabecular bone needs to be destroyed by more than half to detect any apparent lytic findings of bone metastasis on plain radiography<sup>6</sup>. Although the pedicle sign is radiographically regarded as an initial image of bone metastasis, the pedicle sign is a result of infiltration from the vertebral body and the posterior element and does not occur early in the course of metastasis<sup>7</sup>. Negative findings of a pedicle sign do not always mean no spinal metastasis is present. For plain ra-

Table 7 Diagnostic results of blind evaluation of a pedicle sign using results of retrospective evaluation (Part 1) as reference

	Accuracy	Sensitivity	Specificity
Observer 1 (1st time)	81.0%	50.0%	88.2%
Observer 1 (2nd time)	71.4%	50.0%	76.5%
Observer 2 (1st time)	80.0%	33.3%	88.2%
Observer 2 (2nd time)	66.7%	50.0%	70.6%
Mean	74.8%	45.8%	80.9%

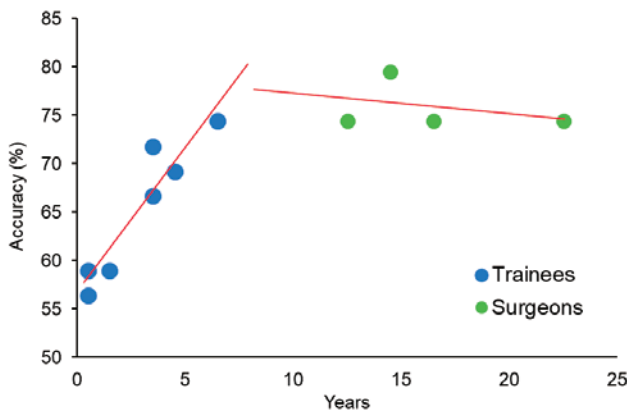


Fig. 3 Correlation between the diagnostic accuracy and observers' experience in orthopedics. In trainees, there was a strong and significant correlation ( $R=0.942$ ,  $p=0.0015$ ), while there was no correlation among certified orthopedic surgeons ( $R=0.309$ ,  $p=0.691$ ).

diography diagnosis of osteolytic bone metastasis, it is necessary to comprehensively check the contours of the spinous processes, the facet joints, the vertebral bodies, and the faint thinning of trabeculae, and not only the pedicle.

All patients examined in this study reported pain. Although the mechanism of pain development in bone metastasis is not sufficiently elucidated, complex interactions among cancer cells, bone cells, and peripheral nerve cells seem to be related to this mechanism<sup>8</sup>. It is presumed that nerve stretching that accompanies an increase in tumor size in the bone marrow and direct infiltration into the nerve are related to this mechanism, in addition to any microfracture due to bone loss<sup>9</sup>. It should be noted that bone loss and degree of pain are not always proportional in practice, and this is one of the limitations of plain radiography for the diagnosis of symptomatic bone metastasis.

The present study showed that the mean blind detection rate for orthopedic surgeons with plain radiography for lesions known to be positive was 73%. This is cer-

tainly lower than the detection rate of fractures in patients in an emergency room (94–99%)<sup>10</sup>, and the detection rate of any abnormality on chest, abdominal, and musculoskeletal plain radiography (80–83%)<sup>11</sup>, suggesting the associated difficulty in diagnosing bone metastasis using plain radiography. This study also showed that there was a strong and significant correlation between accuracy and observers' years of experience in orthopedic surgery among trainees, which suggests that there is a learning curve during the training period. On the other hand, data from the scatter chart (Fig. 3) suggests that the diagnostic ability may mature after becoming a certified orthopedic surgeon. As bone metastasis is less frequently encountered than common orthopedic diseases such as osteoarthritis in daily practice, orthopedic trainees need specialized plain radiography interpretation training for the diagnosis of bone metastasis and to become familiar with early interpretation. Moreover, it also suggests that it is important to create useful plain radiography interpretation learning material for bone metastasis.

The present study has some limitations. First, this study was a retrospective study, and secondly there exists a sampling bias as the number of patients with available plain radiography were only about half of all qualified patients. If nearly the same number of cases as those examined in this study were also added to this study, there is a possibility that the cumulative result may vary. Despite these limitations, there are notable strengths that deserve mention. To the best of our knowledge, this is the first study to investigate the diagnostic ability of plain radiography for symptomatic bone metastasis around the time of first visit. We believe that our results can contribute to improvement in the early diagnosis of bone metastasis.

In conclusion, plain radiography at the time of the first visit can have a definitive role in the early diagnosis of symptomatic bone metastasis. As plain radiography is frequently conducted at the time of the first visit in

medical practice in Japan, this study may be advantageous for early detection of bone metastasis. In order to make it even more useful, it is important to improve the ability of practitioners to interpret plain radiographs for the diagnosis of bone metastasis.

**Acknowledgements:** We are grateful to Mr. Larry Frumson for checking the English grammar of this manuscript and editing this manuscript.

**Conflict of Interest:** We declare no conflict of interest. No funding was received for this study.

### References

1. The editorial board of Cancer statistics in Japan: projection of cancer mortality and incidence in 2015. In *Cancer statistics in Japan 2015, 2016*; pp 14, Foundation for Promotion of Cancer Research (FPCR) c/o National Cancer Center, Tokyo.
2. Freeman AK, Sumathi VP, Jeys L: Metastatic tumors of bone. *Surgery (Oxford)* 2015; 33: 34–39.
3. Lange MB, Nielsen ML, Andersen JD, Lilholt HJ, Vyberg M, Petersen LJ: Diagnostic accuracy of imaging methods for the diagnosis of skeletal malignancies: a retrospective analysis against a pathology-proven reference. *Eur J Radiol* 2016; 85: 61–67.
4. Landis JR, Koch GG: The measurement of observer agreement for categorical data. *Biometrics* 1977; 33: 159–174.
5. Cohen J: A coefficient of agreement for nominal scales. *Educational and Psychological Measurement* 1960; 20: 37–46.
6. O’Sullivan GJ, Carty FL, Cronin CG: Imaging of bone metastasis: An update. *World J Radiol* 2015; 7: 202–211.
7. Asdourian PL, Weidenbaum M, DeWald RL, Hammerberg KW, Ramsey RG: The pattern of vertebral involvement in metastatic vertebral breast cancer. *Clin Orthop Relat Res* 1990; 250: 164–170.
8. Yoneda T, Hiasa M, Nagata Y, Okui T, White FA: Acidic microenvironment and bone pain in cancer-colonized bone. *Bonekey Rep* 2015; 4: 690. doi: 10.1038/bonekey.2015.58.
9. Mercadante S: Malignant bone pain: pathophysiology and treatment. *Pain* 1997; 69: 1–18.
10. Buskov L, Abild A, Christensen A, Holm O, Hansen C, Christensen H: Radiographers and trainee radiologists reporting accident radiographs: a comparative plain film-reading performance study. *Clin Radiol* 2013; 68: 55–58.
11. Tudor GR, Finlay D, Taub N: An assessment of inter-observer agreement and accuracy when reporting plain radiographs. *Clin Radiol* 1997; 52: 235–238.

(Received, January 16, 2018)

(Accepted, September 3, 2018)