

## Epidermoid Cyst Arising on the Body of the Tongue: Case Report and Literature Review

Takashi Ueno<sup>1</sup>, Ryoko Takayama<sup>2</sup>, Shin-Ichi Osada<sup>3</sup> and Hidehisa Saeki<sup>2</sup>

<sup>1</sup>Department of Dermatology, Nishi-Omiya Hospital, Saitama, Japan

<sup>2</sup>Department of Cutaneous and Mucosal Pathophysiology, Graduate School of Medicine, Nippon Medical School, Tokyo, Japan

<sup>3</sup>Department of Dermatology and Plastic Surgery, Akita University Graduate School of Medicine, Akita, Japan

**Background:** Epidermoid cysts of the body of the tongue are rare. Only 12 cases of such lesions have been reported in the English literature.

**Case:** A 14-year-old boy had a 7×5-mm-sized cystic lesion with a yellowish-white surface on the ventral aspect of his tongue. The cystic wall was composed of squamous epithelium containing keratinous material. No skin appendages were attached to the wall. These findings were consistent with a diagnosis of an epidermoid cyst.

**Literature Review:** For the thirteen cases, including ours, the average age was 18.0 years. The highest incidence was found in the first decade of life. Eight of the patients were male and five were female. The size varied from several millimeters to several centimeters. There may be a left side predilection of the occurrence. There is no evidence for malignant transformation of epidermoid cysts of the tongue, though two cases were reported as carcinoma arising from an epidermoid or dermoid cyst of another oral area.

**Discussion:** Epidermoid cysts of the body of the tongue are congenital or acquired. The congenital type can arise due to a failure of surface ectoderm separation or invagination of the surface ectoderm along the embryologic fusion sites. The acquired type is caused by trauma, with implanting of an epithelial element into the deeper tissue. In the present case, it was difficult to determine whether the pathogenesis was congenital or acquired because there are no clinical or histopathological differences between the two types. (J Nippon Med Sch 2018; 85: 343–346)

**Key words:** epidermoid cyst, dermoid cyst, tongue, the body of the tongue

### Introduction

The spectrum of oral dermoid cysts consists of epidermoid cysts, “true” dermoid cysts, and teratoid cysts<sup>1,2</sup>. They represent cystic lesions filled with sebum-like materials and have some overlapping features such as a well-circumscribed nodular appearance, a lack of tenderness, and a cyst wall consisting of stratified squamous epithelium<sup>1</sup>. Epidermoid and dermoid cysts are inclusion cysts derived from the ectoderm. The epidermoid cyst is lined by squamous epithelium, whereas the dermoid cyst is lined by squamous epithelium with skin appendages<sup>2</sup>. The teratoid cyst is composed of tissues derived from at least one of the embryonic germ layers<sup>2</sup>.

Epidermoid cysts of the body of the tongue are rare. To the best of our knowledge, only twelve cases of such lesions have been reported in the English literature<sup>3–13</sup>. Herein, we report a case of an epidermoid cyst of the body of the tongue. Because the previous reports were from dentistry institutes, and departments of otolaryngology or pediatric surgery, the lesion is not widely recognized by dermatologists. This is the first case report on an epidermoid cyst of the body of the tongue from a dermatology department.

---

Correspondence to Takashi Ueno, MD, PhD, Department of Dermatology, Nishi-Omiya Hospital, 1–1173 Mihashi, Omiya-ku, Saitama 330–0856, Japan

E-mail: takashi-ueno@nms.ac.jp

Journal Website (<http://www2.nms.ac.jp/jnms/>)

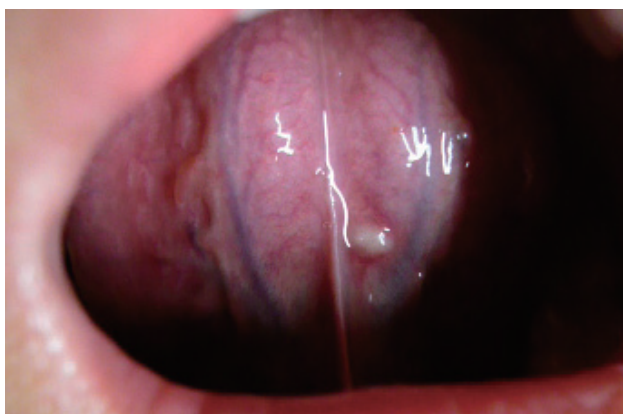

Fig. 1 Clinical appearance. A 7×5-mm-sized nodular lesion with a yellowish-white surface was located to the left of the lingual frenulum on the ventral aspect of the tongue.

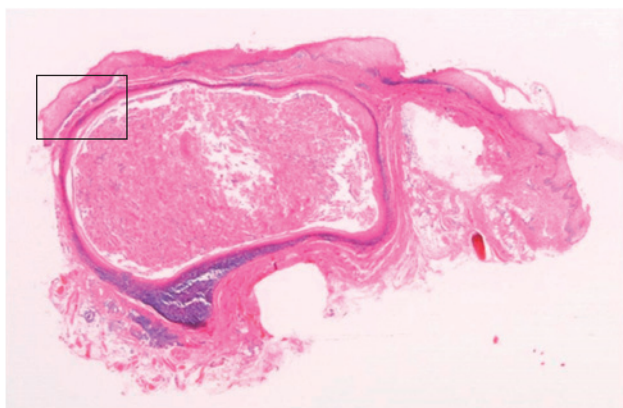


Fig. 2 Histopathological view. The cyst is just below the overlying mucosa. (H & E stain, ×10)

### Case

A 14-year-old boy presented with a slow-growing asymptomatic nodule on his tongue. The patient noticed it eight months before the first visit and had no history of injury to the oral cavity. On clinical examination, a 7×5 mm, well-demarcated, elastic hard nodule with a yellowish-white surface was located to the left of the lingual frenulum on the ventral aspect of the tongue (Fig. 1). The nodule was resected under local anesthesia. Histopathological study revealed that a cyst with keratinous material existed below the overlying mucosa (Fig. 2) and that the cyst wall was composed of a non-keratinized squamous epithelium resembling the oral lining mucosa (Fig. 3). No skin appendages were attached to the cystic wall. These clinicopathological findings were consistent with a diagnosis of an epidermoid cyst.

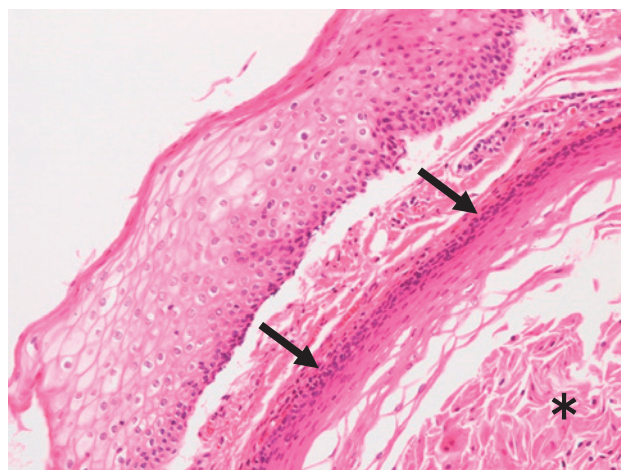


Fig. 3 Higher magnification of the boxed portion in Fig. 2. The cyst is lined with non-keratinized squamous epithelium (arrows) and contains keratinous material (\*) with retained nuclei. (H & E stain, ×100)

### Literature Review

Of the thirteen patients with epidermoid cysts of the body of the tongue, including our case (Table 1), eight were male and five were female. Their average age was 18.0 years. The highest incidence was in the first decade of life, followed by the second. In seven cases, the cyst manifested at birth or when the patient was under 2 years old. The size varied from millimeters to centimeters with an intralingual epidermoid cyst measuring a maximum size of 6.4 cm<sup>3</sup>. There may be a left side predilection of the occurrence; seven were on the left side, one on the midline, and the laterality was not described for the others. Although epidermoid cysts of the body of the tongue are generally asymptomatic and slow-growing, the larger cysts caused difficulties in eating, swallowing, speaking, and even breathing.

In most instances, the cysts were totally resected, except for one treated by marsupialization<sup>4</sup>. Akerson et al.<sup>5</sup> described a case in which asymptomatic swelling of the tongue suddenly increased with subsequent dysphagia and dysphonia within 24 hours. Thus, the lesion is recommended to be treated as soon as possible to avoid a sudden increase in size<sup>5,6</sup>.

There is no evidence for malignant transformation of epidermoid cysts of the tongue, although two cases that occurred in other oral areas developed squamous cell carcinoma, a dermoid cyst in the sublingual area<sup>14</sup>, and an epidermoid cyst within the sublingual gland<sup>15</sup>.

Table 1 Cases of epidermoid cysts of the body of the tongue

	Authors	Age (y.o.)	Sex	First noticed	Size #	Site (of the tongue)	Symptoms	Treatment
1	Quinn (1960)	9	M	at birth	N/D	anterior aspect	drainage through an orifice on the dorsum	excision
2	Goldberg (1965)	22	M	N/D	0.4	left, ventral aspect	N/D	excision
3	Akerson et al. (1974)	10	F	N/D	3.5	midline, dorsal	rapid dysphagia and dysphonia	excision
4	Valtonen et al. (1986)	0.4	F	N/D	1.5	left	N/D	marsupialization
5	Reddy et al. (1991)	0.2	F	at birth	5	ventral	difficulty in breast and bottle feeding	excision
6	Corrêa et al. (2003)	1.2	M	at birth	0.8	left, ventral part	friction against the alveolus	excision
7	Wada et al. (2010)	71	M	70 or 71 y.o.	1.4	left	swelling and continuous pain	excision
8	Akinbami et al. (2011)	32	M	at birth	6.4	intralingual	difficulty in swallowing, speech, and mastication	excision
9	Lakshmi et al. (2011)	5	F	at birth	3	left, anterior	affecting speech articulation	excision
10	Pereira et al. (2011)	12	M	11 or 12 y.o.	6	anterior, ventral	discomfort and affecting normal function	excision
11	Saxena et al. (2015)	12	M	1.5 y.o.	5	ventral aspect	difficulty in breathing, eating, and swallowing	excision
12	Churasia et al. (2015)	45	F	43 y.o.	3	left, dorsal	difficulty in eating, and chewing	excision
13	Present case	14	M	13 y.o.	0.7	left, ventral aspect		excision

M: male #: maximum diameter (cm)

F: female N/D: not described

### Discussion

Epidermoid cysts that develop in the oral cavity are rare and have a predilection for the floor of the mouth<sup>7</sup>. Cases like ours, in which the epidermoid cyst was located in the tongue proper without extending to the floor of mouth, are extremely rare<sup>8,9</sup>.

The tongue consists of two parts with different origins, the body with an oral origin and the root with a pharyngeal origin<sup>16</sup>. The body of the tongue is derived from the first three pharyngeal arches: the lateral processes and the tuberculum impar. In the embryonic period, the swellings fuse to form the body of the tongue<sup>16</sup>. The root of the tongue arises from the second, third, and fourth pharyngeal arches<sup>16</sup>. Moreover, the oral mucosa is classified into three types: specialized mucosa, lining mucosa, and masticatory mucosa. The dorsal and ventral surfaces of the tongue are covered by specialized mucosa and lining mucosa with a non-keratinized epithelium, respectively<sup>17</sup>.

An oral epidermoid cyst can be congenital or acquired<sup>2,9,18</sup>. The congenital type can arise due to the failure of the surface ectoderm to separate from the underlying neural tube, or from invagination of the surface ectoderm along the embryologic fusion sites during the embryonic

stage<sup>2</sup>. In contrast, the acquired type is caused by trauma, resulting in implantation of the surface epithelial element into the deeper tissue<sup>2</sup>.

It was difficult to determine whether the present case was a congenital cyst or an acquired one. The lack of a history of injury suggests the former<sup>19</sup>. However, the latter may not be connected in the patient's mind with any specific injury<sup>20</sup>. Furthermore, there are no clinical or histopathological differences between the congenital and acquired types<sup>6,18</sup>.

**Conflict of Interest:** None declared.

### References

1. King RC, Smith BR, Burk JL: Dermoid cyst in the floor of the mouth. Review of the literature and case reports. *Oral Surg Oral Med Oral Pathol* 1994; 78: 567-576.
2. Smirniotopoulos JG, Chiechi MV: Teratomas, dermoids, and epidermoids of the head and neck. *Radiographics* 1995; 15: 1437-1455.
3. Akinbami BO, Omitola OG, Obiechina AE: Epidermoid Cyst of the Tongue Causing Airway Obstruction. *J Maxillofac Oral Surg* 2011; 10: 349-353.
4. Valtonen H, Nuutinen J, Kärjä J, Collan Y: Congenital dermoid cysts of the tongue. *J Laryngol Otol* 1986; 100: 965-969.

5. Akerson H, Milford ML: Epidermoid cyst of the tongue. Report of case *J Oral Surg* 1974; 32: 117-120.
6. Churasia A, Goel D: Epidermal inclusion cyst of tongue. *J Ora Surg Oral Med Oral Pathol Oral Radiol* 2015; 1: 171-175.
7. Corrêa MS, Fonoff Rde N, Ruschel HC, Parizotto SP, Corrêa FN: Lingual epidermoid cyst: case report in an infant. *Pediatr Dent* 2003; 25: 591-593.
8. Reddy VS, Radhakrishna K, Rao PL: Lingual dermoid. *J Pediatr Surg* 1991; 26: 1389-1390.
9. Lakshmi S, Somashekara KG, Priya NS: Epidermoid cyst of tongue. *Otorhinolaryngol Clin* 2011; 3: 122-124.
10. Goldberg AF: Dermoid Cyst of the Tongue: Report of a Case. *J Oral Surg* 1965; 23: 649.
11. Wada T, Negoro K, Hiraishi Y, Iwagami Y, Fujita S: Epithelial inclusion cyst of the tongue clinically mimicking tongue cancer. *Int J Oral Med Sci* 2010; 8: 167-170.
12. Saxena V, Majithia IP: A rare case of epidermoid cyst of tongue. *Med J Armed Forces India* 2015; 71 (Suppl 2): s564-s567.
13. Pereira CM, Gasparetto PF, Botelho TL: Atypical appearance of epidermoid cyst in tongue's ventral surface. *Revista Sul-Brasileira de Odontologia* 2011; 8: 240-242.
14. Devine JC, Jones DC: Carcinomatous transformation of a sublingual dermoid cyst. A case report. *Int J Oral Maxillofac Surg* 2000; 29: 126-127.
15. Bhatt V, Evans M, Malins TJ: Squamous cell carcinoma arising in the lining of an epidermoid cyst within the sublingual gland - a case report. *Br J Oral Maxillofac Surg* 2008; 46: 683-685.
16. Rise EN: Dermoid cyst of the tongue and floor of the mouth. *Arch Otolaryngol* 1964; 80: 12-15.
17. Nanci A: Oral Mucosa. In *Ten Cate's Oral Histology* (Nanci A, ed), 8th ed. 2012; pp 278-310, Elsevier, St Louis, Missouri.
18. Longo F, Maremonti P, Mangone GM, De Maria G, Califano L: Midline (dermoid) cysts of the floor of the mouth: report of 16 cases and review of surgical techniques. *Plast Reconstr Surg* 2003; 112: 1560-1565.
19. Puranik SR, Puranik RS, Prakash S, Bimba M: Epidermoid cyst: Report of two cases. *J Oral Maxillofac Pathol* 2016; 20: 546.
20. Ettinger RL, Manderson RD: Implantation keratinizing epidermoid cysts. *Oral Surg Oral Med Oral Pathol* 1973; 36: 225-230.

(Received, January 31, 2018)

(Accepted, August 9, 2018)