

## Serum Interleukin-18 Provides a Clue to the Diagnosis of Adult-Onset Still's Disease: Findings from 6 Japanese Patients with Adult-Onset Still's Disease

Azusa Ogita<sup>1</sup>, Shin-ichi Ansai<sup>1</sup> and Hidehisa Saeki<sup>2</sup>

<sup>1</sup>Division of Dermatology, Nippon Medical School Musashi Kosugi Hospital, Kanagawa, Japan

<sup>2</sup>Department of Dermatology, Nippon Medical School Hospital, Tokyo, Japan

**Background:** Adult-onset Still's disease (AOSD) is a systemic autoinflammatory disorder accompanied by skin eruption. However, typical skin eruptions, such as evanescent, salmon-pink erythema, are not specific to AOSD and dermatologists often face difficulty in diagnosing AOSD. In this study, we examined serum IL-18 levels as well as IL-6, ferritin and C-reactive protein in 6 Japanese patients with AOSD.

**Methods:** Serum levels of IL-6 and IL-18 were evaluated in the acute phase and at the time of remission. Serum levels of IL-6 were analyzed using a commercial chemiluminescent enzyme immunoassay (CLEIA; SRL, Tokyo, Japan). Serum IL-18 levels were measured using a commercial ELISA kit (Medical & Biological Laboratories Co., LTD. Nagoya, Japan).

**Result:** In active AOSD, serum ferritin levels and CRP levels were above normal range in 6 patients. In remission, serum ferritin levels of 3 patients were slightly above the normal range, while CRP serum levels of 6 patients were all normalized. Serum IL-18 levels were markedly elevated in 5 cases during the acute phase. In remission, serum IL-18 levels remained at higher values than the normal range in 5 cases. Serum IL-6 levels were also highly elevated in 5 patients in active AOSD and became normalized in remission except in case 2.

**Conclusion:** High levels of serum IL-18 will be a clue to the diagnosis of AOSD. CRP is also useful biomarker for monitoring disease activity compared with IL-6 and IL-18.

(J Nippon Med Sch 2022; 89: 114–118)

**Key words:** steroid resistant, Interleukin-18, Interleukin-6, Adult-onset Still's disease

### Introduction

Adult-onset Still's disease (AOSD) is one of the polygenic autoinflammatory diseases (AIDs) that exhibits no unique symptoms; thus, dermatologists often face difficulty in diagnosing AOSD. Although the pathogenesis of AOSD is not clearly understood, polygenic AIDs such as AOSD, systemic juvenile idiopathic arthritis, Kawasaki disease, and Behçet's disease seem to share the same pathogenesis of hyperactivation of inflammasome and the overproduction of interleukin-1 cytokine family<sup>1</sup>. In AOSD patients with a genetic background, trigger factors such as infections and chemical factors are transmitted to macrophages via Toll-like receptors, which leads to exces-

sive activation of the NACHT, LRR and PYD domains-containing protein3 (NLRP3) inflammasome. This activation of NLRP3 enhances caspase-1 to cleave inactive pro-interleukin-1 $\beta$  (IL-1 $\beta$ ) and pro-interleukin-18 (IL18) into mature IL-1 $\beta$  and IL-18. These cytokines are released from macrophage and stimulate innate immune cells such as monocytes, macrophage and dendritic cells as well as adaptive immune cells by activating Nuclear factor kappa B (NF $\kappa$ B), a transcription factor for pro-inflammatory cytokine genes, to increase the production of pro-inflammatory cytokines, including IL-1 $\beta$ , IL-6, IL-18, tumor necrosis factor (TNF- $\alpha$ ), interferon- $\gamma$  (IFN- $\gamma$ ), etc. This cycle contributes to the overproduction of pro-

Correspondence to Azusa Ogita, MD, Division of Dermatology, Nippon Medical School Musashi Kosugi Hospital, 1-396 Kosugi-cho, Nakahara-ku, Kawasaki, Kanagawa 211-8533, Japan

E-mail: azu@nms.ac.jp

[https://doi.org/10.1272/jnms.JNMS.2022\\_89-114](https://doi.org/10.1272/jnms.JNMS.2022_89-114)

Journal Website (<https://www.nms.ac.jp/sh/jnms/>)

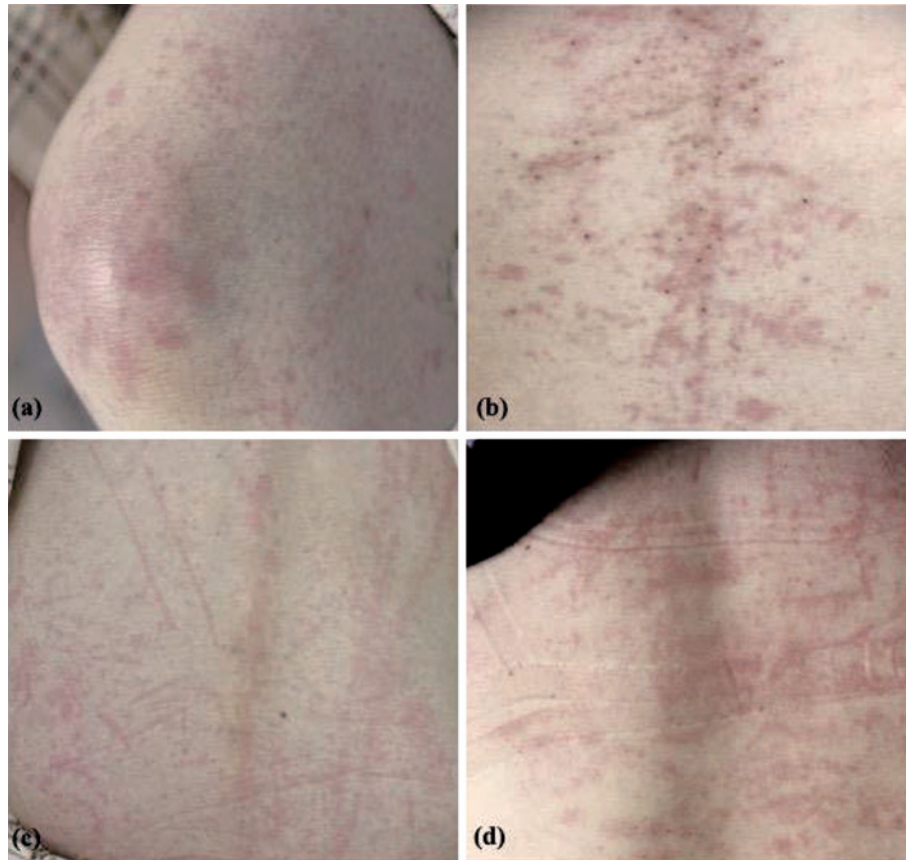


Fig. 1 Skin rashes in cases 2 and 6.

- a. Case 2. Typical rash seen in AOSD. An evanescent, salmon-pink, erythema on the knee.
- b. Case 6. Persistent pruritic, violet to brownish, papules and plaques on the abdomen.
- c. Case 2. Scratch dermatitis-like lesion on the back.
- d. Case 6. Scratch dermatitis-like lesion on the back.

inflammatory cytokines and causes the acute phase reaction<sup>2,3</sup>. Since the involvement of NLRP3 and the overproduction of downstream cytokines such as IL-18 has been suggested to play a pivotal role in AOSD, we suspected that detection of overproduced IL-18 and IL-6 will help diagnosing as AOSD. In this study, we investigated 6 Japanese cases of AOSD that were diagnosed over the past 10 years in our dermatology clinic and measured concentrations of serum IL-18 and IL-6, together with ferritin and C-reactive protein (CRP), to examine their potential as biomarkers for AOSD.

## Materials and Methods

### Patients

To evaluate the serum levels of IL-6, IL-18 and laboratory data, 6 Japanese patients with AOSD who visited our dermatology clinic of Nippon Medical School Hospital over the last 10 years were enrolled. The patients that had no signs or infection, malignancy or rheumatic disease were carefully diagnosed based on the Yamaguchi

criteria for AOSD<sup>4</sup>. Ultimately, six patients with AOSD (1 man and 5 women) were enrolled. Their mean age at the time of diagnosis was 39 years (range: 22 to 53 years). All six patients had skin rashes at the time of visiting our clinic. One patient (case 2) presented with the typical evanescent, salmon-pink erythema with fever (**Fig. 1a**). The other five patients had persistent pruritic erythema. Of them, one patient (case 6) presented with persistent pruritic papules and plaques (**Fig. 1b**). Scratch dermatitis-like lesions were observed in 2 patients (case 2 & 6) (**Fig. 1c, d**). Skin biopsies were performed on 4 patients with persistent, pruritic eruption (case1, 4, 5, 6). Histopathologically, all four cases exhibited perivascular and/or interstitial infiltrate of lymphocytes, neutrophils and eosinophils in the dermis. Interface change was observed in 2 cases (case 4 and 6) and the other 2 cases (case 1, 5) showed no epidermal changes. The histopathological findings of persistent pruritic papules and plaques in case 6 consisted of mounded parakeratosis, dyskeratotic cells in the epidermis and interface change

Table 1 Skin eruptions and changes in serum IL-18, IL-6, Ferritin and CRP levels

Case	Age	Sex	Skin eruptions	IL-18 (126.0±44.5 pg/mL)		IL-6 (≤4.0 pg/mL)		Ferritin (10-60 ng/mL)		CRP (≤0.3 mg/dL)		Remarks
				Onset	Remission	Onset	Remission	Onset	Remission	Onset	Remission	
Case1	48	F	Persistent pruritic erythema	184,497	24,144	184.65	1.64	307.6	66.5	5.33	0	In case 5, when AOSD recurred, IL-18 and IL-6 levels rose faster than ferritin (within normal range), 4,530 pg/mL and 8.6 pg/mL, respectively.
Case2	53	F	Evanescence, salmon-pink, erythema; scratch dermatitis-like lesion	≥5,000	≥5,000	130	11.4	4,439	167	29.24	≤0.1	
Case3	45	F	Persistent pruritic erythema	≥5,000	ND	381	ND	4,692	ND	23.48	ND	
Case4	27	M	Persistent pruritic erythema	ND	169	ND	0.6	441	246	15.46	≤0.1	
Case5	22	F	Persistent pruritic erythema	≥5,000	1,390	35.7	2.3	1,106	20	7.35	≤0.1	
Case6	39	F	Persistent pruritic papules and plaques; scratch dermatitis-like lesion	≥5,000	4,940	10.5	2.2	1,361	18	9.66	≤0.1	

IL-18. interleukin-18; CRP. C-reactive protein; ND. not done

Remission. no fever, no rash, no arthralgia, no lymph node swelling and normalized CRP.

IL-18 values in case 2, 3, 5 and 6 are greater than 5,000 pg/mL (≥5,000 pg/mL). Final values of IL-18 were not obtained because they were tested at other laboratory company.

at the basal layer, as well as superficial perivascular and interstitial infiltration of lymphocytes, neutrophils and numerous eosinophils in the dermis, supporting the distinct and specific findings of persistent pruritic papules and plaques<sup>5</sup>.

#### Measurement of serum IL-6, IL-18

Serum levels of IL-6 (normal range: ≤ 4.0 pg/mL) and IL-18 (normal range: 126 pg/mL±44.5 pg/mL) were evaluated in the acute phase before treatments and at the time of remission (no fever, no rash, no arthralgia, no lymph node swelling and normalized CRP) in 5 patients. Serum levels of IL-6 were analyzed using a commercial chemiluminescent enzyme immunoassay (CLEIA; SRL, Tokyo, Japan). Serum IL-18 levels were measured using a commercial ELISA kit (Medical & Biological Laboratories Co., LTD. Nagoya, Japan) by way of BML, INC. (Case 1) and SRL, INC. (Case 2, 3, 5, 6). Serum CRP (normal range: 0-0.3 mg/dL) and ferritin (normal range: 10-60 pg/mL) levels were also evaluated before and after treatment in 6 patients.

## Results

### Laboratory findings (CRP and ferritin) and changes in serum of IL-6 and IL-18 levels before and after treatment (Table 1)

In active AOSD, serum ferritin levels and CRP levels were above normal range, from 307.6 to 4,692 ng/mL and from 5.33 to 29.24 mg/dL, respectively; in 6 patients. In remission, serum ferritin levels of 3 patients were slightly above the normal range, while CRP serum levels of 6 patients were all normalized.

Serum IL-18 levels were markedly elevated in 5 cases during the acute phase. In case 1, while serum the serum IL-18 level was highly elevated (184,497 pg/mL) at onset, in remission it remained at a high level (24,144 pg/mL). Serum IL-18 levels in 4 cases (case 2, 3, 5, 6) were above the upper-limit of detection of the ELISA kit (≥5,000 pg/mL) and final serum IL-18 levels in 4 cases were not obtained. The reasons are as follows. First, the tests were conducted by other laboratory company in which serum samples were not diluted to get the final serum IL-18 levels. Second, the samples were tested one or two months after a blood test depending on the number of samples collected, causing a delay in the IL-18 results. In remission, serum IL-18 levels remained at higher values

than the normal range in 5 cases. In cases 1 and 2, the serum IL-18 levels remained remarkably high ( $\geq 5,000$  pg/mL) after remission.

Serum IL-6 levels were also highly elevated in 5 patients in active AOSD and became normalized in remission after treatment except in case 2. Interestingly, in case 5, when the AOSD recurred, serum cytokine levels, such as IL-18 and IL-6, rose faster than ferritin and serum IL-18 elevated sharply (4,530 pg/mL) compared with IL-6 level (8.6 pg/mL).

### Discussion

IL-18, a proinflammatory cytokine of IL-1 superfamily, plays a significant role in stimulating innate immune cell activation as well as adaptive immune cells, causing overproduction of several inflammatory cytokines in AOSD. In this study, serum IL-18 levels in 5 patients were elevated significantly higher than normal values and remained higher, even after treatment. A previous report supports our data that IL-18 levels in AOSD were much higher (mean $\pm$ SD 99,000 $\pm$ 99,800 pg/mL) than those in patients with rheumatoid arthritis (RA), systemic lupus erythematosus (SLE), systemic sclerosis, polymyositis/dermatomyositis, and Sjögren's syndrome (SS), and in healthy controls<sup>6</sup>. Colafrancesco *et al.*<sup>7</sup> also concluded that AOSD patients could be discriminated from RA, SLE, and SS patients and from healthy subjects by the serum level of IL-18 determined by ELISA. Furthermore, Kim *et al.*<sup>8</sup> described that with a cutoff value of 366.1 pg/mL, the sensitivity and specificity of IL-18 was highest for the diagnosis of AOSD (91.7% and 99.1%, respectively). Therefore, detection of the overproduction of IL-18 will be clue to the diagnosis of AOSD. Interestingly, some previous studies showed that IL-18 levels were gradually reduced in patients with AOSD after symptoms disappeared by treatment and remained detectable beyond the values in healthy controls, even a few weeks after normalization of the inflammatory reaction<sup>6,9</sup> consistent with our observations of serum IL-18 levels after treatment. In particular, in cases 1 and 2, the serum IL-18 levels remained high ( $\geq 5,000$  pg/mL) even after remission. In these cases, the AOSD was refractory to high dose of systemic corticosteroids and the patients were treated twice with intravenous pulse glucocorticoids therapy together with an immunosuppressant. Furthermore, in case 2, the patient was treated with Tocilizumab, a monoclonal antibody against IL-6 receptor. Our result indicates that high levels of serum IL-18 correlate with disease severity and refractory cases and the role of IL-18 as a marker of disease ac-

tivity in AOSD is questionable. Although the cause of high serum IL-18 levels in remission remains unclear, we suspect that it may be caused by the overproduction of IL-18 levels in organs or tissues, such as lymph node and liver in AOSD<sup>10,11</sup>, resulting in the delay of normalization of serum IL-18 levels.

IL-6 is a pro-inflammatory cytokine secreted by macrophages, activated T cells, B cells and some other cells, which attributes to the production of acute-phase protein and to the activation of B cells for producing antibodies. In our studies, we found out that serum IL-6 levels were elevated at the onset; however, it does not appear to be a reliable diagnostic marker. Kawashima *et al.*<sup>6</sup> demonstrated that increased serum IL-6 was generally detected at higher levels in AOSD patients compared with RA patients; although the difference between the two groups was not statistically significant. Furthermore, Rau *et al.*<sup>12</sup> proved that IL-6 cannot differentiate AOSD patients from patients with sepsis. Therefore, serum IL-6 level is not a specific marker for the diagnosis of AOSD. While IL-6 levels have been considered to correlate with disease activity<sup>9,13</sup>, in case 2, IL-6 remained elevated even after remission. Based upon our findings, CRP levels appear to be more useful in observing disease activity in AOSD.

Hyperferritinemia in AOSD is mainly attributable to increased ferritin released from the liver and spleen<sup>6,14</sup>. IL-18 stimulates innate immune cells such as Kupffer cells in liver and splenic macrophages for erythrophagocytosis to release the iron in the form of ferritin. IL-18 contributes to hyperferritinemia and high level of serum ferritin has been said to be a diagnostic marker of AOSD and correlate with its disease activity<sup>2,3,15,16</sup>. However, serum ferritin levels in our cases increased and decreased gradually in the active and inactive state, compared with IL-6, IL-18, and CRP.

The clinical features of skin eruption in AOSD vary and they are categorized into 2 distinct cutaneous eruptions, one is the typical evanescent, salmon-pink rash, and the other is an atypical persistent, pruritic or non-pruritic rash. The most representative lesion among the atypical skin rashes is persistent pruritic papules and/or plaques, as seen in case 6. The scratch dermatitis-like lesions observed in 2 cases may be among the characteristic eruptions observed in AOSD, presenting as excoriation marks or as a reflection of Koebner's phenomenon<sup>5</sup>. In our cases, there were no correlations between the types of skin eruptions and serum IL-18 and IL-6 levels.

In summary, high levels of serum IL-18 will be a clue to the diagnosis of AOSD. Commercial-based IL-18

ELISA kits in Japan are not actually convenient because the test is not covered by medical insurance, and serum samples are pooled and tested all together a few weeks after a blood test, causing a delay in the IL-18 results. We suggest that IL-18 ELISA kits need to be more practical for use in daily practice. CRP is also useful biomarker for monitoring disease activity compared with IL-6 and IL-18.

**Conflict of Interest:** None declared.

### References

1. Malcova H, Milota T, Strizova Z, et al. Interleukin-1 blockade in polygenic autoinflammatory disorders: where are we now? *Front Pharmacol.* 2021;11:619273.
2. Mitrovic S, Fautrel B. New markers for adult-onset Still's disease. *Joint Bone Spine.* 2018;85:285–93.
3. Feist E, Mitrovic S, Fautrel B. Mechanisms, biomarkers and targets for adult-onset Still's disease. *Nat Rev Rheumatol.* 2018;14:603–18.
4. Yamaguchi M, Ohta A, Tsunematsu T, et al. Preliminary criteria for classification of adult Still's disease. *J Rheumatol.* 1992;19:424–30.
5. Lee JY, Yang CC, Hsu MM. Histopathology of persistent papules and plaques in adult-onset Still's disease. *J Am Acad Dermatol.* 2005;52:1003–8.
6. Kawashima M, Yamamura M, Taniai M, et al. Levels of interleukin-18 and its binding inhibitors in the blood circulation of patients with adult-onset Still's disease. *Arthritis Rheum.* 2001;44:550–60.
7. Colafrancesco S, Priori R, Alessandri C, et al. IL-18 serum level in adult onset Still's disease: a marker of disease activity. *Int J Inflamm.* 2012;156890.
8. Kim HA, An JM, Nam JY, et al. Serum S100A8/A9, but not follistatin-like protein 1 and interleukin 18, may be a useful biomarker of disease activity in adult-onset Still's disease. *J Rheumatol.* 2012;39:1399–406.
9. Choi JH, Suh CH, Lee YM, et al. Serum cytokine profiles in patients with adult onset Still's disease. *J Rheumatol.* 2003;30:2422–7.
10. Conigliaro P, Priori R, Bombardieri M, et al. Lymph node IL-18 expression in adult-onset Still's disease. *Ann Rheum Dis.* 2009;68:442–3.
11. Priori R, Barone F, Alessandri C, et al. Markedly increased IL-18 liver expression in adult-onset Still's disease-related hepatitis. *Rheumatology.* 2011;50:776–80.
12. Rau M, Schiller M, Krienke S, et al. Clinical manifestations but not cytokine profiles differentiate adult-onset Still's disease and sepsis. *J Rheumatol.* 2010;37:2369–76.
13. Chen DY, Lan JL, Lin FJ, et al. Proinflammatory cytokine profiles in sera and pathological tissues of patients with active untreated adult onset Still's disease. *J Rheumatol.* 2004;31:2189–98.
14. Van Reeth C, le Moel G, Lasne Y, et al. Serum ferritin and iso-ferritins are tools for diagnosis of active adult Still's disease. *J Rheumatol.* 1994;21:890–5.
15. Ota T, Higashi S, Suzuki H, et al. Increased serum ferritin levels in adult Still's disease. *Lancet.* 1987;1:562–3.
16. Fautrel B, Le Moël G, Saint-Marcoux B, et al. Diagnostic value of ferritin and glycosylated ferritin in adult-onset Still's disease. *J Rheumatol.* 2001;28:322–9.

(Received, February 8, 2021)

(Accepted, April 30, 2021)

(J-STAGE Advance Publication, September 14, 2021)

Journal of Nippon Medical School has adopted the Creative Commons Attribution-NonCommercial-NoDerivatives 4.0 International License (<https://creativecommons.org/licenses/by-nc-nd/4.0/>) for this article. The Medical Association of Nippon Medical School remains the copyright holder of all articles. Anyone may download, reuse, copy, reprint, or distribute articles for non-profit purposes under this license, on condition that the authors of the articles are properly credited.