

Pectoralis Major Myocutaneous Flap Revisited as a Workhorse for Reconstruction for Defects in the Upper Arm: A Case Report

Taro Mikami^{1,2}, Yuki Homma², Yoshihiko Tamanoi²,
Yuichiro Yabuki², Yusuke Kawabata³, Ikuma Kato⁴,
Toshinori Iwai⁵, Kazuhiro Shimada⁶ and Jiro Maegawa²

¹Department of Plastic and Reconstructive Surgery, Chigasaki Municipal Hospital, Kanagawa, Japan

²Department of Plastic and Reconstructive Surgery, Yokohama City University School of Medicine, Kanagawa, Japan

³Department of Orthopedic Surgery, Yokohama City University School of Medicine, Kanagawa, Japan

⁴Department of Molecular Pathology, Yokohama City University Graduate School of Medicine, Kanagawa, Japan

⁵Department of Oral and Maxillofacial Surgery, Yokohama City University Graduate School of Medicine, Kanagawa, Japan

⁶Department of Breast Surgery, Chigasaki Municipal Hospital, Kanagawa, Japan

Many previous reviews of the literature have described the grafts and techniques for management of defects in the upper arm. However, the alternatives are limited in cases where some conventional flaps are not available and the nearby donor vessels have been previously sacrificed for free flaps. A 77-year-old man presented with a tumor in the right upper arm just above the axilla. The patient had already undergone surgeries for three recurrences of low-grade myxofibrosarcoma, the primary site of which was around the right scapula. The pectoralis major musculocutaneous flap was used for the defect caused by tumor resection, since there was no other available option. An acceptable result was obtained without any major complications. Thus, the pectoralis major myocutaneous flap may be a candidate for reconstruction of defects in the proximal part of the upper arm. (*J Nippon Med Sch* 2023; 90: 288–293)

Key words: pectoralis major myocutaneous flap, upper-arm reconstruction, myxofibrosarcoma

Introduction

Skin flaps or myocutaneous flaps, such as the lateral upper-arm flap and medial upper-arm flap, can be used for reconstruction in cases involving upper-arm defects for which skin grafting is not indicated. Some distant flaps, such as the lateral thoracic flap and latissimus dorsi myocutaneous flap, can also be considered as options in such cases. On the other hand, the solutions are limited when nearby tissues are not available because of complicated trauma or recurrence of malignancies. In such cases, vascularized tissue transfer can be attempted by utilizing intact vessels near the affected site as recipient vessels.

The pectoralis major muscle is a fan-shaped, relatively large muscle that consists of three parts: the clavicular portion, the origin of which is the medial part of the cla-

vicula, the parasternal portion arising from the sternum and upper six costal cartilages, and the abdominal portion from the anterior rectus abdominis sheath¹. The blood supply to the muscle has been considered to be of type V according to the Mathes and Nahai classification, and is provided by the thoracoacromial artery, the lateral thoracic artery, the internal thoracic artery, and the intercostal artery². The lateral and medial pectoral nerves supply branches to the muscle, enabling the upper arm to adduct, extend, and inwardly rotate the shoulder joint³.

The pectoralis major myocutaneous flap (PMMCF) was first described in 1968⁴. This flap has often been used in head and neck reconstructive surgery. In the era of free tissue transfer, this technique is regarded as the a second-line approach in these reconstructive procedures^{5–12}. This tissue has recently come to be recognized as a workhorse

Correspondence to Taro Mikami, Department of Plastic and Reconstructive Surgery, Chigasaki Municipal Hospital, 5-15-1 Honson, Chigasaki, Kanagawa 253-0042, Japan

E-mail: zeong3@mac.com

https://doi.org/10.1272/jnms.JNMS.2023_90-401

Journal Website (<https://www.nms.ac.jp/sh/jnms/>)

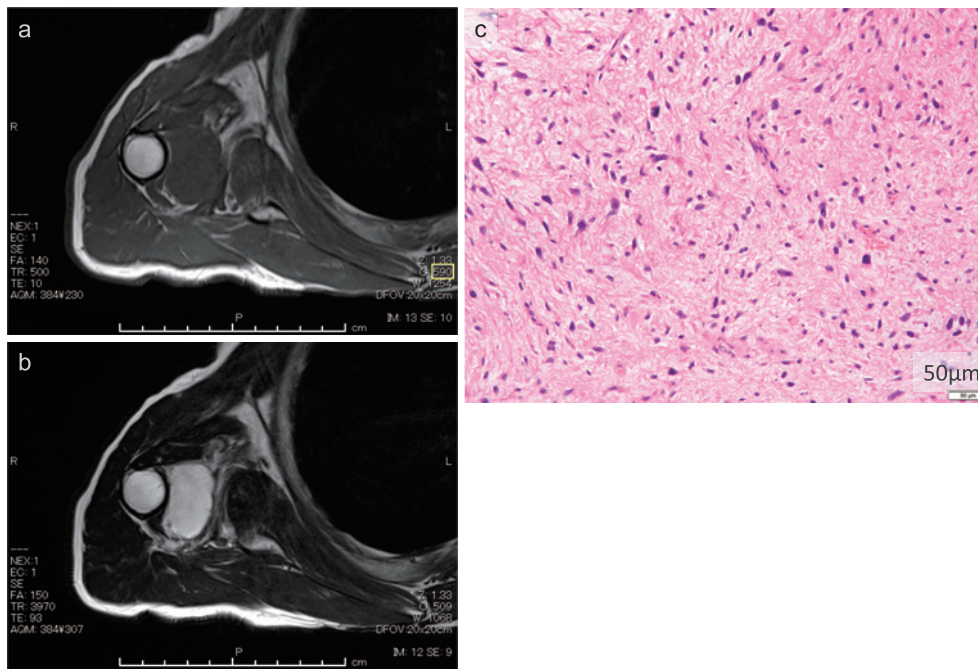


Fig. 1 Preoperative findings

- T1-weighted magnetic resonance imaging scan obtained before surgery.
- T2-weighted magnetic resonance imaging scan obtained before surgery. The lesion was observed near the humerus.
- Histological findings of incisional biopsy. The tumor cells were scattered in a myxofibrous background. Nuclear pleomorphism and atypia were observed. Thin-walled blood vessels were observed sparsely.

of free vascularized tissue transfer since the thoracoacromial artery, one of the main feeding arteries, is sufficiently present along its length for its use as a free flap, although the free vascularized flap style of PMMCF for reconstruction of limbs was first described in 1976¹³⁻¹⁷. On the other hand, few previous studies have described the use of this flap as a pedicled flap for reconstruction of upper-arm defects^{18,19}.

We encountered a case of recurrent myxofibrosarcoma on the proximal side of the right upper arm, the primary site of which was present in the upper back of the ipsilateral side. The PMMCF on the ipsilateral side was applied to the defect.

Case Report

The patient was a 77-year-old man who noticed a subdermal tumor on the right upper back when he was 69 years of age. He had a history of lung and laryngeal cancers, hypertension, rheumatoid arthritis, and diabetes mellitus. He had been prescribed medication for all of these conditions except the cancers. The patient was 164 cm tall, weighed 56 kg, and his fingers were affected by rheumatoid arthritis.

He underwent a primary surgery at the same age in at

another hospital, and a relatively small lesion was removed during the procedure. However, the first recurrence appeared one year later, and histopathological examination revealed that the resected lesion was malignant. Approximately three years later, when the patient was 72 years old, he was admitted to the Department of Orthopedic Surgery of our institute because of a second recurrence. Pathological evaluation of the incisional biopsy specimen confirmed low-grade myxofibrosarcoma (Fig. 1). Subsequently, tumor excision with wide margins was performed, followed by reconstruction using split-thickness skin grafting (Supplementary Fig. 1; https://doi.org/10.1272/jnms.JNMS.2023_90-401). However, the patient showed sarcoma cells on the edge of the deep layer in histopathological assessments. Two months later, radiation therapy with a total dose of 60 Gy was initiated to the primary site (Supplementary Fig. 1).

Approximately 18 months after the first surgery at our institute, a tumor that had grown up to a certain size was noticed in the right upper arm near the axilla. Since local recurrence was suspected, the tumor was excised with a wide margin, which was followed by local skin flap and split-thickness skin grafting (Supplementary Fig. 2; https://doi.org/10.1272/jnms.JNMS.2023_90-401).

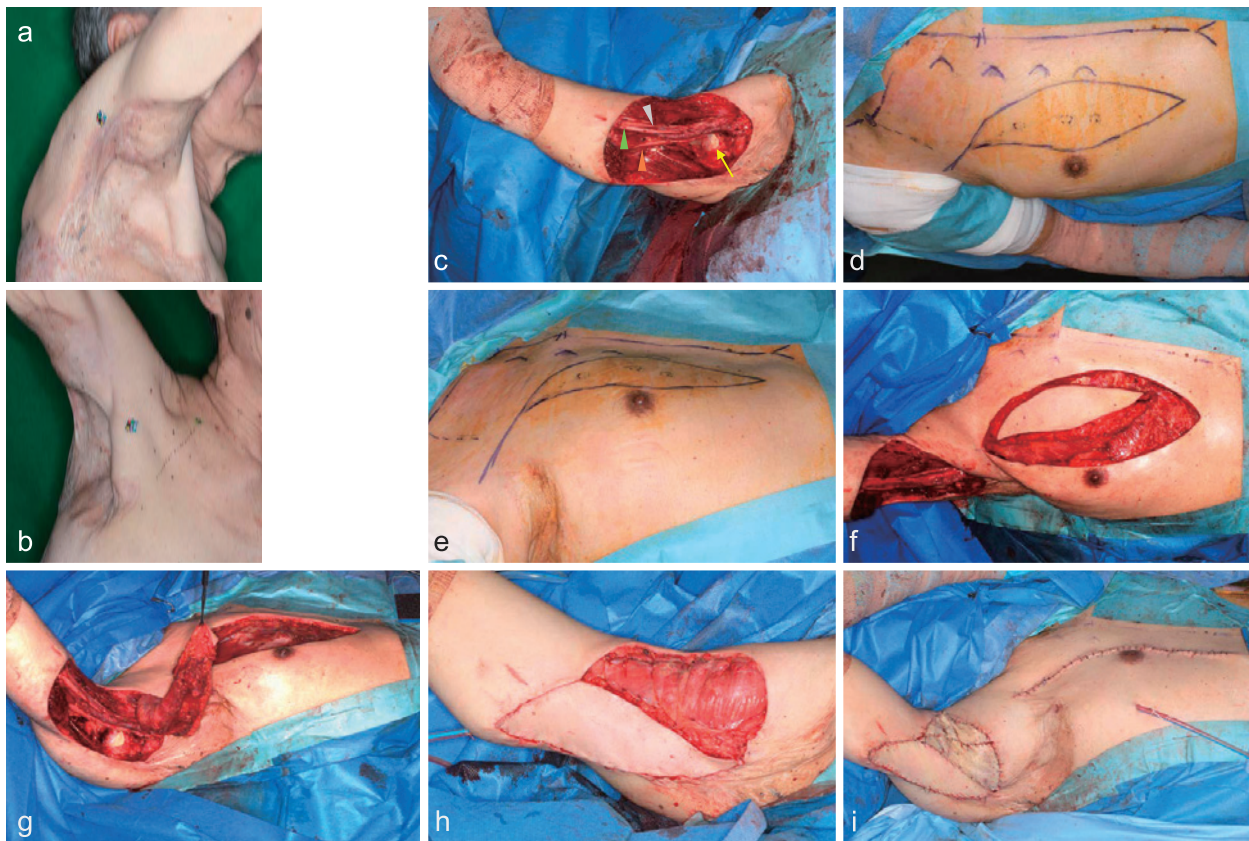


Fig. 2 Local findings obtained before and during the third surgery

- Lateral view of the axilla before surgery. A slightly distended area is marked by a black dotted line. This area was compatible with a recurrent lesion.
- Anterior view of the right axilla and proximal upper arm. The black dotted line in the upper chest indicates the pectoral branch of the thoracoacromial artery identified with an ultrasonic Doppler blood flow meter.
- The medial view of the right upper arm after removal of the lesion. The brachial artery and comittant veins, as well as the median, ulnar, and radial nerves were exposed. A part of the humerus is shown in this picture. Orange arrowhead: ulnar nerve. Light green arrowhead: median nerve. Gray arrowhead: radial nerve. Yellow arrow: a part of the humerus.
- The design of the pectoralis major myocutaneous flap (PMMCF). The three dotted circles indicate the skin perforators of the pectoral branch of the thoracoacromial artery.
- Lateral view of the design of the PMMCF.
- The flap before the transfer.
- The flap during the transfer. The flap passed through the subcutaneous tunnel in front of the right axilla.
- The flap after mounting to the defect. Dermal sutures between the skin paddle of the flap and the defect margins were completed, while the pectoralis major muscle flap was sutured to the lateral border of the serratus anterior muscle. Note that the exposed nerves and vessels were completely covered.
- Final status of the surgical site.

However, one year after the last surgery, another tumor was observed on the proximal side of the right upper arm, near the axilla. The lesion had also obviously increased in size in four months, and magnetic resonance imaging (MRI) indicated it was a local recurrence (Fig. 1).

The tumor was 3 cm in diameter and located in the right upper arm near the right axilla. The tumor was movable in the subcutaneous layer, with partial skin adhesion.

After resection of the lesion, the triceps brachii muscle

was partially resected, while the biceps brachii muscle was intact. The brachial artery and veins, median nerve, radial nerve, and ulnar nerve were exposed for about 10 cm in length. In addition, a part of the humerus was also exposed to some area of the defect of the periosteum (Fig. 2). The defect was circular with a diameter of approximately 10 cm. The most distal point was 7 cm from the right cubital fossa. Since the primary lesion was located in the upper back, neither the latissimus dorsi muscle flap nor the parascapular flap was available. In addition, the thoracodorsal artery and veins had already been

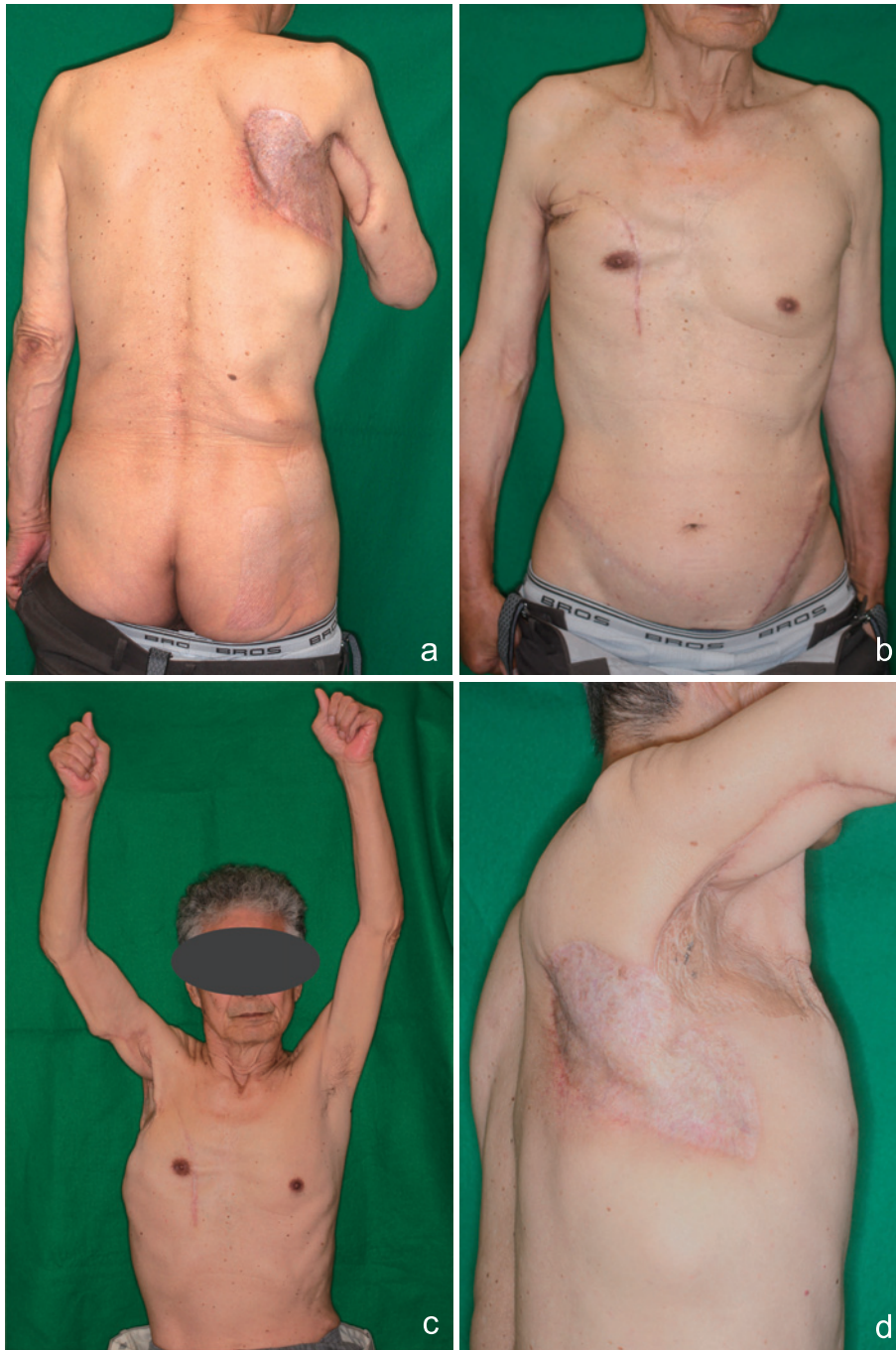


Fig. 3 Findings obtained at 18 months after the surgery

- a. Posterior view. The skin graft in the right upper back revealed no signs of recurrence, and no hypertrophic scar was present in at the donor site on the right buttock.
- b. Anterior view. An operative scar was noted on the right chest. The right nipple and areola complex were slightly higher than those on the left. Two linear scars resulting from skin grafting were observed present in the lower abdomen on both sides.
- c. Anterior view of the upper chest and the arms. The patient could raise his right and left arms. There was no sign of scar contracture in the right anterior chest or signs of disturbed range of movement of the shoulder joint.
- d. The lateral view of the right axilla and the upper chest.

sacrificed. Therefore, we planned to use the PMMCF to reconstruct the defect. The skin paddle was designed in the parasternal portion, including the perforators from

the thoracoacromial artery in the 4th and 5th intercostal spaces. The size of the skin paddle was 20 cm × 7 cm (Fig. 2). After skin incision, subfascial dissection was per-

formed with electrocautery to find the medial and lateral borders of the pectoralis major muscle. The muscle was cut off with a LigaSure™ Small Jaw (Covidien Japan, Minato-ku, Tokyo, Japan) at the medial and lateral borders (Fig. 2). In this procedure, the vascular pedicle was identified using an ultrasonic Doppler bloodflow meter. The clavicular part of the muscle was incised with LigaSure™ to elongate the arc of rotation of the flap. The elevated flap was passed through the subcutaneous tunnel, just below the clavicle.

Since the distal part of the flap was confirmed to reach the most distal point of the defect in the upper arm, the exposed nerves, vessels, and bare bone were covered by the muscle flap. The remnant portion of the right triceps brachii and lateral border of the muscle flap were sutured using with 4-0 Vicryl™. A full-thickness skin graft from the left lower abdomen was divided into two pieces and applied to the muscles with a modified Alabama method dressing.

The postoperative clinical course was uneventful. The skin graft was fully taken with no necrosis in the skin paddle of the flap. Eighteen months after surgery, no local recurrence was observed and the patient showed a full range of movement in the right shoulder (Fig. 3).

The patient provided written informed consent for the use of clinical data, including photos.

Discussion

This case highlights two major findings. First, PMMCF can serve as a workhorse for reconstruction of skin and soft tissue defects in the proximal side of the upper arm. The second finding was that the PMMCF showed lower morbidity in reconstruction of the upper arm.

In some previous studies, PMMCF was reported to be an option for reconstruction of the trunk or extremities as a vascularized free flap^{16,20,21}. However, few reports have described the use of this flap as a pedicled flap to cover defects in the upper arm; one of the reasons is that other flaps are technically simpler. However, the latissimus dorsi myocutaneous flap muscle flap as well as free vascularized flaps were not available in the present case. On the other hand, the perforator flaps from the distal part of the upper arm were too small to cover the exposed nerves and vessels. Since the pectoral branches of the thoracoacromial vessels were thought to be less affected by radiation, while the PMMCF was large and long enough to cover the defect, the PMMCF was applied. Our surgical procedure involved two important steps: one was the design of the skin paddle to ensure the

length of the flap, and the other was the incision of the clavicular part of the muscle to gain the length of the pedicle of the flap²¹.

Some studies have reported that PMMCF or muscle flaps induced shoulder arthropathy or worsened DASH scores, while other reports advocated fewer donor-site morbidities in procedures performed with these flaps^{22,23}. The DASH scoring system was not applied in the present case because the fingers of the patient had been affected by rheumatoid arthritis. However, the patient did not experience any disturbances in activities of daily living after the final surgery. A rare case report suggested that this flap may cause pneumothorax⁹. These findings may be the reasons for the relatively few indications for applying PMMCF for reconstruction in of the upper arm.

This flap can be used to cover defects on the more distal side of the upper arm by designing the skin paddle on the deep fascia of the rectus abdominis muscle, as reported previously^{18,21,24}. In addition, the size of the skin paddle is limited when the donor site is planned to be closed directly. In such cases, the skin graft to the donor site or on the muscle of the flap should be prepared in proportion to the size of the defect.

Conclusion

PMMCF can serve as a workhorse to reconstruct skin and soft tissue defects in the proximal side of the upper arm. However, the design of the skin paddle and the arc of rotation should be examined well before surgery, and the possibility of some adverse effects, such as limitations of the range of movement in the shoulder joint, should be kept in mind.

Conflict of Interest: The authors declare no financial and or other competing interests.

References

1. Strauch B, Yu HL. Atlas of microvascular surgery: anatomy and operative techniques. New York: Thieme; 2006. p. 453–70.
2. Mathes SJ, Nahai F. Classification of the vascular anatomy of muscles: experimental and clinical correlation. *Plast Reconstr Surg*. 1981 Feb;67(2):177–87.
3. Wei FC, Mardini S. Flaps and reconstructive surgery. 2nd ed. [VitalSource eBook]. Elsevier; 2016. p. 22502–3172.
4. Hueston JT, McConchie IH. A compound pectoral flap. *Aust N Z J Surg*. 1971 Aug;38(1):61–3.
5. Kruse AL, Luebbbers HT, Obwegeser JA, Bredell M, Gratz KW. Evaluation of the pectoralis major flap for reconstructive head and neck surgery. *Head Neck Oncol*. 2011 Feb 27;3:12.
6. Baek SM, Lawson W, Biller HF. An analysis of 133 pectoralis major myocutaneous flaps. *Plast Reconstr Surg*. 1982

- Mar;69(3):460-9.
7. Miller LE, Stubbs VC, Silberthau KB, et al. Pectoralis major muscle flap use in a modern head and neck free flap practice. *Am J Otolaryngol.* 2020 Jul - Aug;41(4):1024-75.
 8. Opoku-Agyeman J, Matera D, Simone J. Surgical configurations of the pectoralis major flap for reconstruction of sternoclavicular defects: a systematic review and new classification of described techniques. *BMC Surg.* 2019 Sep 13;19(1):136.
 9. Kim B, Kaleem A, Zaid W. Case reports of two unusual donor site complications of the pectoralis major myocutaneous flap and literature review. *J Oral Maxillofac Surg.* 2016 Jul;74(7):1504.e1-e12.
 10. Gadre KS, Gadre P, Sane VD, Halli R, Doshi P, Modi S. Pectoralis major myocutaneous flap--still a workhorse for maxillofacial reconstruction in developing countries. *J Oral Maxillofac Surg.* 2013 Nov;71(11):2005.e1-e10.
 11. Vartanian JG, Carvalho AL, Carvalho SM, Mizobe L, Margrin J, Kowalski LP. Pectoralis major and other myofascial/myocutaneous flaps in head and neck cancer reconstruction: experience with 437 cases at a single institution. *Head Neck.* 2004 Dec;26(12):1018-23.
 12. Kekatpure VD, Trivedi NP, Manjula BV, Mathan Mohan A, Shetkar G, Kuriakose MA. Pectoralis major flap for head and neck reconstruction in era of free flaps. *Int J Oral Maxillofac Surg.* 2012 Apr;41(4):453-7.
 13. Trainotti S, Hoffmann TK, Rotter N, et al. Pectoralis major muscle free flap: anatomical studies on pedicle length and vessel diameter. *Ear Nose Throat J.* 2019 Aug;98(7):431-4.
 14. Corten EM, Schellekens PP, Bleys RL, Hage JJ, Kon M. The segmental pectoralis major free flap: anatomical features of its vascular pedicle. *Ann Plast Surg.* 2006 Jan;56(1):82-6.
 15. Corten EML, Hage JJ, Schellekens PPA, Kreulen M, Kon M. Clinical application and outcome of the segmental pectoralis major free flap in five head and neck patients. *Plast Reconstr Surg.* 2009 May;123(5):1462-7.
 16. Ikuta Y, Kubo T, Tsuge K. Free muscle transplantation by microsurgical technique to treat severe Volkmann's contracture. *Plast Reconstr Surg.* 1976 Oct;58(4):407-11.
 17. Reid CD, Taylor GI, Waterhouse N. The clavicular head of pectoralis major musculocutaneous free flap. *Br J Plast Surg.* 1986 Jan;39(1):57-65.
 18. Russell RC, Feller AM, Elliott LF, Kucan JO, Zook EG. The extended pectoralis major myocutaneous flap: uses and indications. *Plast Reconstr Surg.* 1991 Nov;88(5):814-23.
 19. Lin H, Hou C, Xu Z. Transfer of the superior portion of the pectoralis major flap for restoration of shoulder abduction. *J Reconstr Microsurg.* 2009 May;25(4):255-60.
 20. Hallock GG. The total pectoralis major muscle myocutaneous free flap. *J Reconstr Microsurg.* 2013 Sep;29(7):461-4.
 21. Iblher N, Penna V, Momeni A, Padron NT, Stark GB. The extended pectoralis major flap for reconstruction of the upper posterior chest wall and axilla. *J Thorac Cardiovasc Surg.* 2008 Sep;136(3):790-1,791.e1-e13.
 22. Teo KG, Rozen WM, Acosta R. The pectoralis major myocutaneous flap. *J Reconstr Microsurg.* 2013 Sep;29(7):449-56.
 23. Sun Q, Guo S, Wang D, Xu N, Jin SF, Wang CC. Does pectoralis major flap harvesting induce upper extremity dysfunction? *J Int Med Res.* 2015 Aug;43(4):555-9.
 24. Wei WI, Lam KH, Wong J. The true pectoralis major myocutaneous island flap: an anatomical study. *Br J Plast Surg.* 1984 Oct;37(4):568-73.

(Received, October 9, 2021)

(Accepted, December 15, 2021)

(J-STAGE Advance Publication, January 25, 2022)

Journal of Nippon Medical School has adopted the Creative Commons Attribution-NonCommercial-NoDerivatives 4.0 International License (<https://creativecommons.org/licenses/by-nc-nd/4.0/>) for this article. The Medical Association of Nippon Medical School remains the copyright holder of all articles. Anyone may download, reuse, copy, reprint, or distribute articles for non-profit purposes under this license, on condition that the authors of the articles are properly credited.