

## Photodynamic Identification of Human Parathyroid Glands with 5-aminolevulinic Acid

Haruki Akasu<sup>1,2</sup>, Takehito Igarashi<sup>1,2</sup>, Kumi Tanaka<sup>1,2</sup> and Kazuo Shimizu<sup>1,2</sup>

<sup>1</sup>Department of Biological Regulation and Regenerative Surgery, Nippon Medical School Graduate School of Medicine

<sup>2</sup>Department of Surgery, Division of Endocrine Surgery, Nippon Medical School

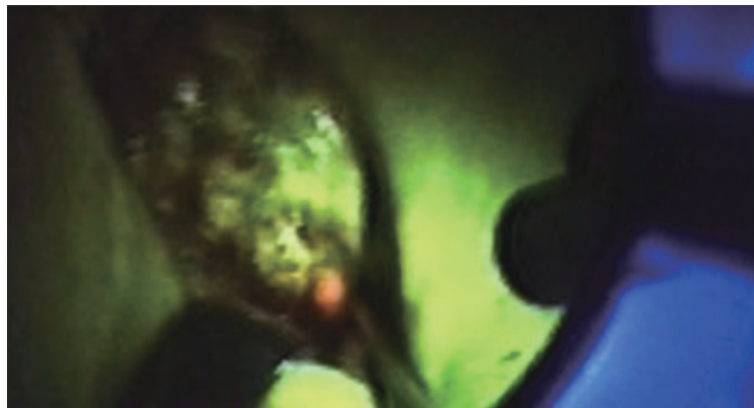

Fig. 1

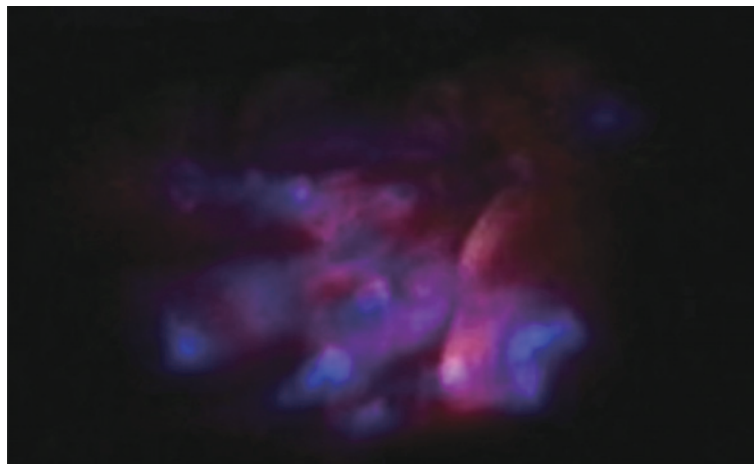


Fig. 2

### Abstract

Tumors synthesize fluorescent and photosensitizing endogenous protoporphyrin after administration of 5-aminolevulinic acid (5-ALA). Localization of tumors and tumor-like lesions in various organs that are labeled with fluorescing porphyrins has thus developed into a diagnostic method. Intraoperative photodynamic detection of malignant gliomas is the most common application, and has been widely performed since 1998<sup>1</sup>.

Although several methods to identify parathyroid glands have been employed, photodynamic methods have not yet been used for this application. In 2004, Shimizu et al. showed that human parathyroid glands could be identified photodynamically with 5-ALA<sup>2</sup>. We have performed photodynamic identification of human parathyroid

---

Correspondence to Haruki Akasu, Department of Surgery, Nippon Medical School, 1-1-5 Sendagi, Bunkyo-ku, Tokyo 113-8603, Japan




Fig. 3

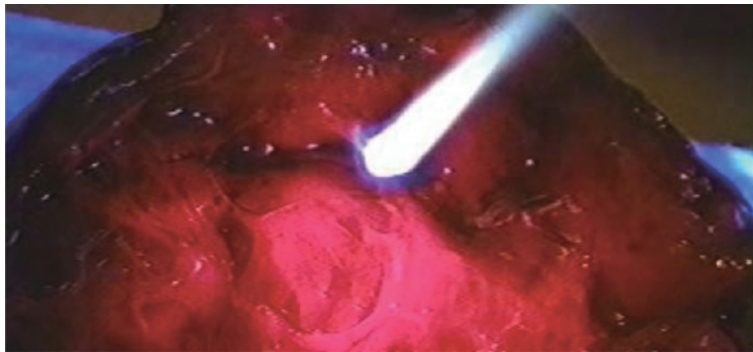


Fig. 4

glands in an additional 19 cases.

In hyperparathyroidism, detection of morbid parathyroid glands is extremely important. On the other hand, the identification and preservation of normal parathyroid glands is important for preventing hypoparathyroidism after thyroid surgery. Our method allows the visualization of both morbid and normal parathyroid glands.

We believe that intraoperative photodynamic identification of human parathyroid glands is feasible and practical, allowing less-invasive, more-precise neck surgery.

**Fig. 1** Intraoperative fluorescence of normal parathyroid gland. Parathyroid gland is visualized as a red spot and can be distinguished from nearby tissues.

**Fig. 2** Intraoperative fluorescence of hyperplastic parathyroid gland (25 mm in diameter). Hyperplastic parathyroid gland is visualized as uneven red fluorescence.

**Fig. 3, 4** Cut surface of parathyroid adenoma (48 mm in diameter) (**Fig. 3**) showed marked fluorescence (**Fig. 4**).

### References

1. Stummer W, Stocker S, Wagner S, et al: Intraoperative detection of malignant gliomas by 5-aminolevulinic acid-induced porphyrin fluorescence. *Neurosurgery* 1998; 42: 518–526.
2. Shimizu Kazuo, Shimizu Kazuhide, Kitagawa W, et al: Clinical application of 5-aminolevulinic acid: A useful and feasible new method for intraoperative identification of pathological and normal parathyroid during endocrine neck surgery. *Endocrine Surgery* 2004; 21: 199–202.