

## Visualizing Complex Cardiac Arrhythmias

Yasushi Miyauchi, Yu-ki Iwasaki, Reiko Okazaki,  
Hiroshige Murata, Teppei Yamamoto, Ayano Matsumoto,  
Yoshinori Kobayashi, Takao Katoh and Kyoichi Mizuno

Division of Cardiology, Hepatology, Geriatrics, and Integrated Medicine, Department of Internal Medicine,  
Graduate School of Medicine, Nippon Medical School

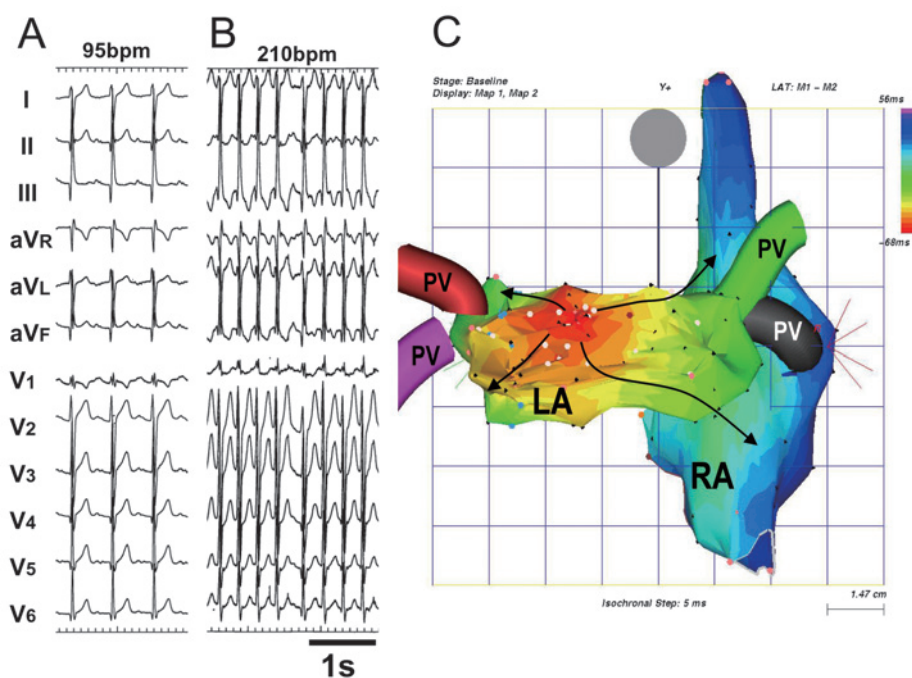


Fig. 1

A nonfluoroscopic, catheter-based, three-dimensional electroanatomical mapping system (CARTO system, Biosense-Webster, Diamond Bar, CA, USA) has been developed that may aid in ablating complex cardiac tachyarrhythmias. The system uses magnetic technology to accurately determine the three-dimensional location of the mapping and ablation catheter. Recorded data of the catheter location and an intracardiac electrogram (ECG) at that location are used to reconstruct a real-time representation of the three-dimensional geometry of the chamber, color-coded with relevant electrophysiological information. The sequence of activation is visualized on the reconstructed geometry of the cardiac chambers by the colors of the spectrum (red, orange, yellow, green, light blue, dark blue, and purple). With this system, the activation pattern and the target site for ablating complex tachyarrhythmia can be visually demonstrated.

Since the deployment of this system, we have cured a total of 168 cases of various complex tachyarrhythmias. Two representative cases are shown in the figures. In a 17-year-old teenaged boy with exercise-induced atrial tachycardia (**Fig. 1**), the activation map exhibited a radially spreading pattern from a focus in the posterior wall of the left atrium. The radiofrequency ablation at the earliest activation site

Correspondence to Yasushi Miyauchi, MD, Division of Cardiology, Hepatology, Geriatrics, and Integrated Medicine, Department of Internal Medicine, Nippon Medical School, 1-1-5 Sendagi, Bunkyo-ku, Tokyo 113-8603, Japan

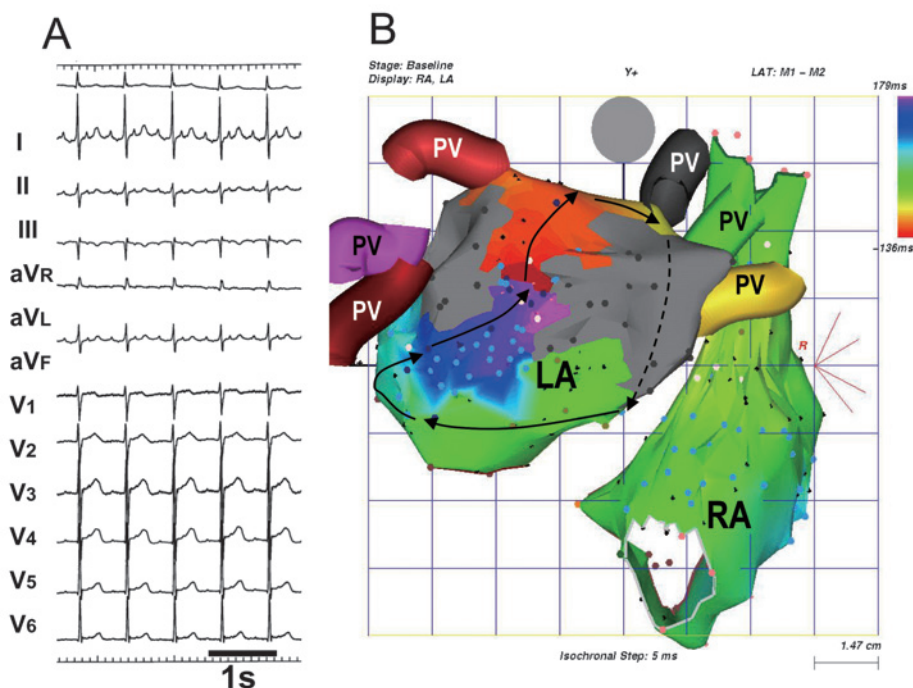


Fig. 2

successfully eliminated the tachycardia. In another case of atrial tachycardia after surgery for aortic valve and atrial fibrillation (**Fig. 2**), the activation map (**Fig. 2B**) showed a reentrant pattern around the surgical lesions. This atrial tachycardia was eliminated by the radiofrequency ablation between the scars around the left and right pulmonary veins.

**Fig. 1** Twelve-lead ECG (A and B) and activation map (C) of focal atrial tachycardia in a 17-year-old teenaged boy. The baseline ECG (A) exhibited ectopic atrial rhythm with the positive P waves in inferior limb and all precordial leads. After administration of isoproterenol (B), the rate of atrial rhythm increased to 210 beats per minute with P waves of the same morphology. An electroanatomical activation map (C) of the left atrium (LA) and right atrium (RA) exhibited a radially spreading pattern (**arrows**) from a focus that is shown in red. PV=pulmonary vein.

**Fig. 2** Twelve-lead ECG (A) and the activation map (B) of macroreentrant atrial tachycardia after surgery for atrial fibrillation in a 67-year-old man. The ECG exhibits atrial tachycardia at a cycle length of 310 milliseconds with 2:1 atrioventricular conduction. The activation map exhibits a macroreentrant pattern where the earliest activation site (red) meets the latest activation site (purple) and the whole activation time (time to the earliest to latest activation) fulfils the entire cycle length of the tachycardia. Sites with double potentials that are tagged with light blue dots represent surgical incisions. Gray dots and area are scars created by cryoablation during surgery. Abbreviations are the same as in Figure 1.